Ser Yogin Rayal 1817

2309

THE

ANATOMIST'S

VADE-MECUM.

CONTAINING THE

Anatomy, Physiology, Morbid Appearances, &c.

OF THE

Human Body;

THE

Art of making Anatomical Preparations, &c.

To which are added,

ANATOMICAL, PHYSIOLOGICAL, MEDICAL,

AND

SURGICAL EXAMINATIONS

FOR STUDENTS.

A NEW EDITION,

VERY MATERIALLY IMPROVED.

By ROBERT HOOPER, M. D.

...tiate in Physic of the University of Oxford, and the Royal College ... Physicians in London; Fellow of the Linnæan Society, &c.; Physi-...an to the St. Mary le-bone Infirmary; and Lecturer on Medicine in ...ondon.

LONDON:

...NTED FOR JOHN MURRAY, 32, FLEET-STREET.

1811.

L:2
A11

HARDING and WRIGHT, Printers, St. John's Square, London.

TO

THOMAS WHEELER, ESQ.

FELLOW OF THE LINNEAN SOCIETY;

PROFESSOR OF BOTANY TO THE WORSHIPFUL COMPANY

OF APOTHECARIES IN LONDON;

APOTHECARY TO ST. BARTHOLOMEW'S HOSPITAL, &c.

THIS EDITION

IS GRATEFULLY AND RESPECTFULLY INSCRIBED,

AS A TESTIMONY OF ESTEEM FOR HIS UNIFORM FRIENDSHIP, HIS VIRTUES, AND PROFESSIONAL ABILITIES

BY

HIS SINCERE AND AFFECTIONATE FRIEND,

THE AUTHOR.

LIST

OF

Dr. HOOPER'S PUBLICATIONS.

1. The ANATOMIST'S VADE-MECUM, &c. foolscap 8vo. New Edition, 9s.

2. The PHYSICIAN'S VADE-MECUM, foolscap 8vo. 6s.

3. The SURGEON'S VADE-MECUM, &c. foolscap 8vo. 6s.

4. A Compendious MEDICAL DICTIONARY; containing an Explanation of the Terms in Anatomy and Surgery, Practice of Physic, &c. A new Edition, 12mo. 9s.

5. QUINCY'S LEXICON MEDICUM. A new Edition, with very important Additions and other Improvements, 8vo. 18s.

6. The STRUCTURE and ECONOMY of PLANTS; to which is added, the Analogy between the Animal and Vegetable Kingdom. 8vo. 3s. 6d.

7. OBSERVATIONS on the INTESTINAL WORMS of the Human Body. 8vo.

8. OBSERVATIONS on the INFLUENZA, 8vo. 1s. 6d.

9. ALBINUS'S TABLES of the BONES DIMINISHED, with Explanations, &c. 7s.

10. ——— PLATES of the MUSCLES, foolscap 8vo. 5s.

11. WALTER'S PLATES of the NERVES, reduced from the Originals. 4to. 18s.

12. A DIAGRAM of the EYE, on a large folio sheet, coloured, 2s. 6d.

INTRODUCTION.

IT is the intention of the Writer, in the following Compendium, to present to the student a useful anatomical conspectus, or pocket manual of anatomy and physiology: in which he will find,

1. A short but accurate description of the different parts of the human body, and their functions.

2. An enumeration of the diseases to which those parts are subject, and the various operations of surgery that are performed on the human body.

3. The method of preparing the various parts of the body, to exhibit their structure, in a natural and diseased state, as far as our present knowledge will enable us.

4. A glossary, or explanation of the principal terms used in that science.

5. Such questions as he probably will be required to answer at the College of Surgeons, the Medical Board, the Board of Sick and Hurt, &c. in order to obtain his diploma, or pass as surgeon, or surgeon's mate, for the army or navy, or the service of the East-India Company.

The utility of such a performance, interspersed with a number of practical remarks, it is presumed, will be generally acknowledged, especially when it is considered that there is no such work written upon a similar plan.

The principal motive that induced the Author to form and collect together, into one small pocket-volume, this elementary production, was his having himself experienced the want of such an assistant when applying to that branch of philosophy. He therefore solicits permission to recommend it to students, not as a work wherein any thing new is to be met with, but merely as their occasional companion in the prosecution of their studies.

21, *Savile Row,*
1810.

THE PLAN OF

Dr. HOOPER's and Dr. AGER's LECTURES,

ON THE

THEORY AND PRACTICE OF PHYSIC, MATERIA MEDICA, AND CHEMISTRY.

THE LECTURES on the THEORY and PRACTICE of PHYSIC are wholly delivered by Dr. HOOPER. They comprehend a full account of the principles of the science and of all the diseases incident to men, women, children, and infants, excepting such as belong to Surgery and Midwifery. The diseases are delivered in nosological order; the symptoms, predisposing, exciting, and proximate causes, are explained and followed by the most approved modes of treatment and diet. The whole illustrated by drawings taken from diseases during life, and also by an extensive collection of morbid parts, to explain the seat and causes of diseases and the structure of diseased viscera.

The Lectures on CHEMISTRY and the MATERIA MEDICA are delivered principally by Dr. AGER. In these Lectures the theoretical principles of the science of Chemistry are illustrated by numerous experiments, and the occasional introduction of those parts of Natural Philosophy which are more immediately connected with it. Its application to the Arts is very fully explained, and particularly to Medicine, by exhibiting the method of preparing all the chemical articles directed by the Royal Colleges to be kept in the

shops. In the Lectures on the Materia Medica, every article of approved efficacy, but especially those admitted into the Pharmacopœias of the Royal Colleges, are exhibited, and their natural history, sensible and chemical properties, and medical virtues, described.

Terms of Attendance.

	First course.	Second.	Third.	Perpet.
Practice of Physic	4 Guineas	3	2	8
Chemistry and Materia Medica	4 ——	3	2	8

Perpetual to all the Lectures, 10 Guineas.

Three courses are delivered in the year: one commencing the first Monday in October; the second on the first Monday in February, and the third on the first Monday in June.

*** The Lectures on the Theory and Practice of Physic are delivered every morning (Sundays excepted) at eight o'clock; and those on Chemistry and Materia Medica at nine, at Dr. HOOPER's Museum, Cork-Street, Burlington Gardens.

Perpetual Pupils are entitled to private examinations.

A

COMPENDIOUS

HISTORY OF ANATOMY.

FROM the works of HIPPOCRATES, THE FATHER OF MEDICINE, who flourished about *four hundred years before the birth of Christ*, is to be collected all the information of antiquity on the subject of Anatomy. This great physician, whose principal attention was directed to the symptoms and cure of diseases, was, nevertheless, well aware of the importance of anatomical knowledge to perfection in the healing art: hence we find, that his works abound with anatomical facts and observations, interspersed with the prevailing doctrines of the day. When it is considered, how many obstacles were thrown in the way of this science, from climate, prejudice, and superstition, the perseverance and acquirements of this great man, the ornament of the medical profession, cannot be sufficiently admired. He describes some parts peculiar to the

human body, which could only be ascertained by actual dissection. The body he made to consist of solids, fluids, and spirits; of containing and contained parts. The elementary humours he divided into four kinds: blood, phlegm, choler or bile, and melancholy or occult bile. This was agreeable to the philosophy of the age in which he lived; as likewise the notions of all bodies being composed of earth, air, fire, and water. He never distinguished between nerves, arteries, veins, or tendons; but calls the heart and its pericardium a powerful muscle; he knew the aorta, vena cava, pulmonary arteries and veins, and entertained obscure notions of the uses of the valves; but considered the auricles as a fan. He mentions the distributions of the arteries and veins by trunks and ramifications from the heart; and asserts, that all the arteries originate from the heart. The liver was thought to be the root of the veins, the fountain of the blood; and he supposed it to separate bile. He thought the arteries carried the spirits; but was entirely ignorant of the circulation of the blood, and of the use of the diaphragm; and his seating the soul in the left ventricle of the heart, is a memorable example of human vanity, and of that inherent inclination in man, boldly to account for what is inexplicable. The heart and lungs, he imagined, received part of our

drink. Of the organ of hearing, it is concluded, he knew little, for he only mentions the tympanum. As to the brain, which he thought a gland, (an idea which has since been erroneously supposed to belong to Malpighi,) the nerves and their uses, vision and the senses, he was totally ignorant as to the causes; yet he makes the brain the seat of wisdom. The glands he imperfectly understood. The Pythagorean doctrines of conception, generation, and pregnancy, are, in general, absurd and superstitious; as likewise his notions of the Pythagorean numbers, which seem to have been the prevailing philosophical follies of the day. On moles, false conceptions, and the nourishment of the fœtus, a rational judgment is formed; he comprehended the communication from the mother to the fœtus by means of the umbilical cord; though, in another place, he supposes that it absorbs nutriment by the mouth, and from the surrounding fluid in the ovum.

After Hippocrates, anatomy continued to be improved; but, as opportunities were extremely limited, from the prejudices of mankind, its progress was but slow, and chiefly confined to the two schools of *Athens* and *Alexandria*. In the former, the name of Socrates, Plato, Xenophon, Aristotle, and Theophrastus, are still preserved along with many of their works; and, although we

observe that their general attention was directed to philosophy, yet natural history and anatomy were far from being overlooked: their opportunities, however, of examining bodies, were confined; and, after their time, the study of natural knowledge at Athens sunk for ever. But while it decayed in Greece and Asia, it rose with increased energy, under the protection of the Ptolemies, at Alexandria. In this school, which was so long pre-eminent, Erisistratus and Herophilus were highly distinguished for anatomical knowledge. By the liberal patronage of the Ptolemies, they enjoyed ample opportunities of dissecting human bodies; and the consequent improvements which anatomy received were very great. They not only corrected many former errors, but wrote with great judgment upon neurology. They observed a variety of structure in nerves supplying different parts, and hence distinguished them into those which were necessary to sense, and those which were subservient to motion.

Between the times of Herophilus and Erisistratus to Galen, a period of five hundred years, Asclepiades, Rufus Ephesius, and the sensible and elegant writer Celsus, flourished. The two latter have given the appellations and situations of all the parts of the human body, *in compendio*, in which many discoveries appear to have been made from

the time of Hippocrates. Neither one nor the other dwelt much on the uses of the parts. Rufus writes Greek in the concise Attic style, and Celsus is the most classical writer that ever appeared in the art of medicine.

Claudius Galenus, or Galen, was physician to four emperors, and was, without exception, the most distinguished practitioner of the age in which he lived. He has arranged all the prior anatomical science that Herophilus and Erisistratus had obtained from the actual dissection of human subjects, and incorporated it into his voluminous treatises on all the branches of medicine. The medical principles of this great man, formed on the Peripatetic philosophy of Aristotle, are not to the present purpose; except that they reigned triumphantly in the schools and universities, disdaining and crushing all innovators, or improvers, for a period of nearly fifteen hundred years. The celebrated Galen, however, was a man of uncommon erudition; and he brought into one point of view, with much labour, learning, and industry, all the medical and philosophical science of his predecessors. The anatomical part was indubitably extracted from the great Herophilus and Erisistratus, and, consequently, in general contains what those *first dissectors* of human bodies, had observed or written. In the works of this eminent

physician, anatomy appears very conspicuous and methodical. He gives the situation and uses of all the parts of the human body, whether animal, vital, or natural. What discoveries he made, cannot be ascertained; but Galen was the first author who seems to have digested, in regular order, the human functions, the brain and its membranes, the senses, the contents of the thorax and abdomen, osteology, a complete myology, and neurology, in which are the origin and insertion of the muscles, their action, &c.; and the distribution of the whole nervous system. The lacteal vessels, likewise, were well known; though the extent of their effects, their passing through the thoracic duct and subclavian vein, to the blood, were not comprehended. The exhalant arteries and inhalants were mentioned, both by Hippocrates and Galen; but the principles of action were unknown. The circulation of the blood, the real uses of the liver, glands, heart, diaphragm, pancreas, kidney, ureters, bladder, universal cellular structure, the power of the nervous system over the arteries and veins, the lymphatic absorbent system, were to him unknown.

From the time of Galen to the *fifteenth century*, anatomy was rather on the decline, anatomists being considered learned or ignorant in proportion to their knowledge of his works. The destruction of

Alexandria introduced learning among the *Arabians;* but they made little progress in the knowledge of the human body. ABDOLLALIPH, however, towards the close of the twelfth century, exposed many of Galen's errors in osteology, by frequenting burial-grounds.

Among the early cultivators of the science of anatomy in the *fifteenth century*, the GREAT VESALIUS flourished, who may with propriety be styled the RESTORER OF ANATOMY; being the first who dared expose the errors of Galen, in medicine and anatomy, by referring to the human body. This wonderful man, whose perseverance and genius cannot be sufficiently admired, was born at Brussels, in 1514. After having gone through the usual studies of the age, he went to Montpellier, to study medicine. The principal professors in the university of Paris requested him to come there, where he attended their lectures. Vesalius's zeal for medicine, particularly anatomy, induced him to brave every danger to which he was exposed, by clandestinely procuring bodies for dissection. He did not, however, confine his attention to the human subject only, but opened a great number of animals. In the pursuit of his favourite science, his veneration for Galen diminished in proportion as he detected his inaccuracies; till at length he threw off

all control of this great standard of ancient medicine and anatomy, and became the advocate for actual dissection of the human body, to which he constantly referred in all his disputations.

The war which commenced at that time in France, obliging Vesalius to leave Paris, he returned to his own country, Louvain. The knowledge he had acquired in anatomy induced him to profess it publicly in that city; but, in order to extend his anatomical researches, in 1535, he followed the army of the Emperor Charles the Fifth, against France. His reputation increased. He was chosen professor of anatomy in the university of Padua, by the republic of Venice, and there gave lectures on medicine, particularly anatomy, for seven years.

In 1539, Vesalius published his anatomical plates, which attracted the admiration of the learned. In this, and in his other works, all the errors of Galen are exposed. A multitude of enemies sprung up against this bold innovator of old established authority. All Europe resounded with invectives against him: Eustachius at Rome, Driander at Marpurg, and Sylvius at Paris, became his public enemies, particularly the latter, who employed every species of calumny to lessen him in the esteem of his patrons: instead of Vesalius, he called him *Vesanus*, or a madman; and accused him of ignorance, arogance,

and impiety. Fallopius was the only one among his opponents who preserved any moderation. Having been a pupil of Vesalius, he never forgot how much he was indebted to his preceptor; and, although he was far more able than Sylvius to criticise, from having powerful objections to bring forward against the work, he proceeded in the most delicate and respectful manner, influenced by the greatest esteem and gratitude for the assistance he had received from his venerable master. Vesalius, on the other hand, acted towards his pupil in the most gentle and honourable manner. As soon as the remarks of Fallopius on his work had reached Spain, Vesalius prepared to answer them, and replied to him as a father would to his son. Fallopius, who has rendered his name dear to posterity by his extensive knowledge in anatomy, possessed sentiments very different from Sylvius; he was not ashamed of acknowledging his obligations to Vesalius, for the greater part of his information on anatomy: he admits that Vesalius has not shewn sufficient respect to Galen, but confesses that his objections are generally correct. Notwithstanding all opposition, the reputation of Vesalius daily increased, and he established anatomy on solid and permanent principles, when the Emperor Charles the Fifth, by whom he had been already honoured, nominated him

his first physician, and kept him constantly at court. He now gained the confidence of the nobility, and frequently gave unequivocal marks of his profound knowledge in the practice of physic. But an unexpected event soon reduced this great man to distress. Upon the death of a Spanish gentleman, whom he had attended during life, Vesalius requested permission of the relatives of the deceased to open the body, he being very desirous of investigating the obscure cause of his death; which request was granted. Some of the spectators, who probably were not Vesalius's friends, declared they saw the heart palpitate upon his opening the thorax: their declaration soon reached the ears of the nobleman's relations, and raised a suspicion that the body was opened alive; in consequence of which, Vesalius was prosecuted for homicide and impiety, and brought before the Inquisition; which severe tribunal was about to punish him for the crime, when Philip the Second, of Spain, suggested the means of removing him from the decision of his judges, and caused him to make a pilgrimage to the Holy Land; in consequence of which, Vesalius resolved to make the tour of Palestine. He passed over to Cyprus with James Malateste, a Venetian general, and thence to Jerusalem. Soon after the death of the celebrated Fallopius, which happened in the year 1564, the senate

of Venice recalled Vesalius to fill the chair; but on his voyage to Padua, he was shipwrecked on the island of Zante, where this great man, reduced to the utmost extremity, perished with hunger, on the 15th of October 1564, at the age of fifty years. It is said, that a goldsmith, who landed on that part of the island soon after the accident, caused him to be interred, and an epitaph to be engraven on his tomb in the church of the Virgin Mary in that island.

The beginning of the *seventeenth century* is remarkable for the discovery of the most important function of animated bodies, by our countryman HARVEY. This great physician was born of a respectable family at Folkstone, in Kent, on the 2d of April, 1578. At ten years of age he was sent to a grammar-school at Canterbury, and at fourteen removed to Caius college, Cambridge. At nineteen he travelled through France and Germany to Padua, in Italy, where, having studied physic under Eustachius Radius, John Minadous, and Fabricius ab Aquapendente, by whom he was taught anatomy, he was created doctor of physic and surgery in that university in 1602. Returning soon after to England, he was incorporated M. D. at Cambridge, went to London to practise, and married. In 1604, he was admitted candidate of the College of Physi-

cians in London, and three years afterwards fellow. In 1615, he was appointed lecturer of anatomy and surgery in that college.

In the year 1632, he was made physician to Charles the First, as he had been before to King James; and adhering to the royal cause, upon the breaking out of the civil wars, attended his Majesty at the battle of Edgehill, and then at Oxford, where, in 1642, he was incorporated M. D. In 1645, the King got him elected warden of Merton college in that university, but upon the surrendering of Oxford the year after to the Parliament, he left that office and retired to London. In the year 1651, he published his work on the generation of animals; a book replete with interesting observations, and which would have been more so but for some misfortunes, by which his papers perished during the time of the civil wars. On Michaelmas-day 1654, he was chosen President of the College of Physicians in his absence, and coming there the day after, acknowledged his great obligations to the electors for advancing him to such honour and dignity, as if he had been chosen to be "Medicorum omnium apud Anglos princeps:" but his age and weakness were so great, that he could not discharge the duty incumbent upon that great and distinguished office; he therefore requested them to elect Dr. Prujean, who

had deserved so well of the College. As Dr. Harvey had no children, he made the College his heirs, and settled his paternal estate upon them in the July following. He had three years before built them a combination-room, a library, and a museum, and in 1656 he brought the deeds of his estate, and presented them to the College. He was then present at the first festival instituted by himself to be continued annually, together with a commemoration speech in Latin, to be spoken on the eighteenth of October, in honour of the benefactors to the College; having appointed a handsome stipend to the orator, and also to the keeper of the library and museum, which are still called by his name. He died June 3, 1657, and was carried to be buried at Hemstead, in Hertfordshire, where a monument is erected to his memory.

In the year 1616, Dr. Harvey read a course of lectures, in which he first opened his discovery relating to the circulation of the blood, which some judicious anatomists had before only suspected to exist in a vague and confused manner, and which others had only known to take place in some particular part. From this period Harvey demonstrated and taught in his public lectures, and by simple and clear experiments proved to the most incredulous minds, that the blood not only traversed the struc-

ture of the lungs, but that it circulated in every part of the body, by means of an admirable arrangement on which depends the life of man. He fully evinced the alternate contraction and dilatation of the heart; the passage of the blood from the two venæ cavæ into the right auricle, from thence into the right ventricle, and through the lungs; its reception into the left auricle from the pulmonary veins, its expulsion thence into the left ventricle, from which it was propelled through all the arteries of the body, and returned by the veins. So clearly were the phenomena of the whole circulation understood, and so admirably explained, by Dr. Harvey, that notwithstanding he wrote near two hundred years ago, this function has never since been laid down with more truth, simplicity, and elegance.

Soon after the discovery of the circulation of the blood, Aselius, an Italian, discovered the lacteals, which Pecquet, in 1651, traced to the thoracic duct, and thence to the left subclavian vein. In 1653, Rudbeck and Barthoin discovered the lymphatics: it does not appear that there was any communication between them; both, therefore, are entitled to equal praise. The latter has, however, additional credit from his having entertained very accurate ideas of the physiology of the lymphatic system, which was afterwards more fully explained by Glisson.

The two last centuries have nearly perfected our knowledge of the human body. Every nation in Europe has produced anatomists of the greatest reputation. The names of ALBINUS, COOPER, DIEMERBROCK, HIGHMORE, CHESELDEN, LEWENHOECK, MALPIGHI, MAYOW, RUYSCH, WILLIS, and WINSLOW, form but a small number of those who have enlightened the science of anatomy in the *seventeenth century*. In the *eighteenth*, the following are particularly distinguished: HALLER, MORGAGNI, ZYNN, WALTER, SCARPA, SOEMMERING, the MONROS, the HUNTERS, and CRUICKSHANK.

Fortunately for mankind, Anatomy is now become an indispensable branch of medical science; and throughout Europe we have every where distinguished teachers, who are daily adding to the stock of useful information.

ANATOMY.

Anatomy is a science that explains the structure and use of every part of the human body, both solids and fluids.

The examination of brute animals, fishes, reptiles, polypi, &c. to illustrate more clearly, or to demonstrate by analogy, the structure and functions of man, is called *Zootomy*, or *Comparative Anatomy*.

PRINCIPLES OF THE HUMAN BODY.

The human body consists of solids and fluids. The solids are divided into *hard* and *soft*: the former comprehending bones and cartilages; the latter, muscles, nerves, the viscera, and all the soft parts of the body.

SOLIDS OF THE HUMAN BODY.

Analysis of the solid parts demonstrates their constituent principles to be *earthy particles*, connected together by an *intermediate gluten*.

When these principles are joined one to another in a regular series, they form a *simple* or *elementary fibre*.

If a number of fibres be joined together by their breadth, they constitute a *lamina*, or *layer*.

The union of many of these *laminæ*, without any order, forms *cellular structure*, more commonly termed *cellular membrane*.

A *membrane* is nothing more than a compact or condensed cellular structure.

Thick, strong, and elastic membranes are termed *ligaments*.

When cellular structure is distended with a coagulated elastic jelly, it forms a *cartilage.*

Phosphate of lime deposited in cellular structure, constitutes either *bony fibres,* or *laminæ,* which form *bone.*

A nerve is a soft bundle of fibres, of a pulpy substance, *sui generis,* called *nervous,* and cellular structure.

The *brain* is composed of this nervous substance.

Muscles consist of fibres formed of a peculiar substance, nerves and vessels. *Tendons* are the beginnings or ends of muscles, of a silver glistening colour.

Blood-vessels and *absorbents* are hollow canals, formed of membranes, nervous and muscular fibres, and cellular structure.

Glands are composed simply of vessels, nerves, and cellular structure; or a peculiar substance.

A *viscus,* is a term given to any part which performs a determinate office, as the lungs, the liver, intestines, the skin, glands, &c. &c. The *viscera* are composed of vessels, nerves, and cellular texture.

FLUIDS OF THE HUMAN BODY.

These consist of the chyle, blood, and various humours separated from the blood. See *Hygrology.*

The science of Anatomy comprehends, and is divided into,

Osteology,	or doctrine of the	Bones.
Syndesmology,	or doctrine of the	Ligaments.
Myology,	or doctrine of the	Muscles.
Bursalogy,	or doctrine of the	Bursæ Mucosæ.
Angiology,	or doctrine of the	Vessels.
Neurology,	or doctrine of the	Nerves.
Adenology,	or doctrine of the	Glands.
Splanchnology,	or doctrine of the	Viscera.
Hygrology,	or doctrine of the	Fluids.

OSTEOLOGY;

OR,

DOCTRINE OF THE BONES.

BONES are hard, compact, inflexible, and insensible substances, composed of earth and gluten, which support and form the stature of the body, defend its viscera, and give adhesion to its muscles.

In order to demonstrate the earth and gluten of bones, it is only necessary to calcine them, and expose a dried bone to the action of dilute acids. The earth which remains after calcination, is *phosphate* and a little *carbonate of lime.* The gluten into which the bone is converted by macerating in dilute acids, is *gelatin.*

The SUBSTANCE of bones is of three kinds:—*compact*, as in the bodies of the long bones; *spongy*, as in the extremities of the long bones; and *reticular*, called also the *cancelli* of bones, as in the cavities of bones which have marrow.

Take a thigh-bone, macerate it well, make a perpendicular section, and you will observe the three substances of bones very beautifully marked: the *compact* is seen forming its external part and body, the *spongy* at the extremities, and the *reticulated* in its cavity.

The compact substance is formed of many laminæ, or plates, composing a firm hard substance. These laminæ are easily distinguishable in bones that have been partly exposed to calcination, or boiled for any length of time in a strong alkaline ley, or steeped in muriatic acid and water. In man, and in other living animals, these laminæ mostly separate on exposure to air; and hence the laminated portions are called *exfoliations* in surgery.

The fibres of the spongy and reticulated substances are extremely varied in their direction; and some variety occurs in this respect in the compact substance: thus, in flat bones, as those of the head, they are disposed in the form of rays, and are seen converging from the circumference to the centre; in the cylindrical bones they seem to be placed in parallel directions.

To exhibit the above circumstances, and demonstrate the direction of the bony fibres, select—

1st, The parietal bones of a fœtus; macerate the soft parts away, and preserve the bones in spirits. Thus they will exhibit, very beautifully, the radiated direction of the fibres.

2d, A portion of the adult femur from the body of the bone; macerate it, after depriving it of its soft parts, in diluted muriatic acid, and then separate with forceps the laminæ: this will exhibit the laminæ of bones.

3d, The os femoris of a fœtus, slink calf, or a pig; macerate it, and keep it in spirit, or dry it and put it into spirit of turpentine, to shew the parallel direction of the bony fibres.

Colour. This differs according to the proportions of earth or blood entering their composition: hence, in the adult they are whitest, and reddest in the child, more earth existing in the former, and more blood in the latter.

Composition. Besides phosphate and carbonate of lime, and gluten, which form the principal part of bone, it is supplied with blood-vessels, absorbents, and nerves.

Figure. Various, yet they are mostly divided, from their shape, into broad and flat, long and round, and cylindrical bones. Long and irregular-shaped bones are divided into a body and extremities; and flat bones into body and margins.

Names. Bones are variously named; some from their situation, as the frontal, parietal, occipital, nasal, malar, &c.; others from their figure, as the ethmoid bone, clavicle, os cuboides, naviculare, tibia, &c.; and some from their use, as the sphænoid bone, the maxillary bone, the femur, &c. The *processes* and *cavities* of bones are named after their figure, as the acetabulum of the os innominatum, the odontoid process of the second cervical vertebra, the coracoid process of the scapula, &c.; or from their use, as the trochanters of the thigh-bone; or from their situation, as the nasal, palatine, orbitar processes.

If a process be large, and of a spherical shape, it is termed sometimes the *caput*, or head; if the head is flattened, it takes the name of a condyle. Other processes are termed mastoid, or mammillary, from their resemblance to a nipple; styloid and coracoid, from their similitude to a stiletto, or the beak of a crow; some spinous, which appear like thorns; others derive their names from their direction, as the longitudinal, perpendicular, horizontal, oblique, transverse processes.

There is a kind of eminence peculiar to bones, called an *epiphysis*, which should be distinguished from an *apophysis*. The latter is nothing more than a process; but an epiphysis is a part of a bone, connected to that bone by an intervening cartilage; thus the condyles of the thigh-bone of a child are epiphyses, and are separable from the femur. Epiphyses at length become apophyses in the adult.

> Macerate the flesh from the femur of a child two years old, and suspend it in spirits, to shew the epiphyses at the superior and inferior extremity. Pigs' bones are also well calculated to shew the epiphyses.

Use. Bones support and give stature to the body, defend its viscera, and give adhesion to its muscles.

1. Besides giving support and stature, they at the same time form levers, by which we are enabled to move the whole or parts of the body in obedience to our will, to resist certain powers, and perform the various and multiplied operations of the arts.

2. In regard of the defence which they afford to parts; we observe the brain surrounded by a strong case of bone, and the spinal marrow wonderfully guarded by vertebræ, which at the same time allow of motion: in the chest, the heart and lungs are secure from pressure and common accidents; and the most important parts of the organs of generation are defended by strong bones.

3. The eminences of bones enlarge their substance, multiply the different points of adhesion for muscles, and augment their moving power, by removing their attachment from the centre of motion.

4. Lastly, by the many moveable joints which bones form we are allowed the vast extent of power we enjoy; and fractures, which without them would continually be happening, are prevented: joints also permit of the great extension which bones experience during *their growth*.

When the bones are deprived of their soft parts, and hung together in their natural situation by means of wire, the whole is termed an *artificial skeleton:* but when they are kept together by means of their ligaments, it is called a *natural skeleton.*

A Table of the Bones.

			No.
Bones of the Head.	The bones of the *cranium* or *skull*	Os frontis	1
		Ossa parietalia	2
		Os occipitis	1
		Ossa temporalia	2
		Os ethmoides	1
		— sphænoides	1
	The bones of the *face*	Ossa maxillaria superiora	2
		——jugalia	2
		——nasalia	2
		——lachrymalia	2
		——palatina	2
		——spongiosa inferiora	2
		Os vomer	1
		— maxillare inferior	1
	Dentes, or *teeth*	Incisores	8
		Cuspidati	4
		Bicuspides	8
		Molares	8
		Sapientiæ	4
	Bone of the *tongue*, or	Os hyoides	1
	Bones of the internal *ear*, situated within the temporal bone	Mallei	2
		Inci	2
		Ossa orbicularia	2
		Stapides	2

				No.
Bones of the Trunk.	The *spine*	Vertebræ . . .	Cervical —	7
			Dorsal —	12
			Lumbar —	5
		Sacrum — —	—	1
		Os coccygis — —	—	1
	The *thorax*	Sternum	— —	1
		Costæ — —	—	24
	The *pelvi*	Ossa innominata	— —	2
Bones of the Upper Extremities.	The *shoulder* — —		Claviculæ —	2
			Scapulæ —	2
	The *arm* — —		Ossa humeri —	2
	The *fore-arm* — —		Ulnæ —	2
			Radii —	2
	The *hand*	*Carpus*, or *wrist*	Ossa navicularia	2
			—— lunaria —	2
			—— cuneiformia	2
			—— orbicularia	2
			—— trapezia	2
			—— trapezoides	2
			—— magna —	2
			—— unciformia	2
		Metacarpus	— —	10
		Phalanges	— —	28
Bones of the Lower Extremities.	The *thigh* — —		Ossa femoris	2
	The *leg* — —		Patellæ —	2
			Tibiæ —	2
			Fibulæ —	2
	The *foot*	*Tarsus* — —	Ossa calcis —	2
			—— astragali	2
			—— cuboides	2
			—— navicularia	2
			—— cuneiformia	6
		Metatarsus —	— —	10
		Phalanges —	— —	28
Sesamoid bones of the thumb and great toe, occasionally found — — —				8
			Total	248

The skeleton is divided into head, trunk, and extremities.

Of the Head.

There is great variety in the shape of the heads of individuals. The head of females is more delicate; the insertions of the various muscles of the face are not so strongly marked. The crania of different nations also vary; in the generality of Europeans the shape is oblong; in the Turk and Algerine it is round; and in the Chinese and Tartar it is broad. The cranium of the African is flattened on the forehead, and the teeth and chin are extended forward. The shape of the head of the Asiatic and American negro, also varies considerably from the European.

Some anatomists have attributed this variety in the crania of different nations to the management of the children when very young; supposing the head of the Turk to be rounded by an early use of the turban, while that of an Englishman is flattened by the chin-stay. Others are of opinion that the difference in the shape is not occasioned by any such accidental means, but by natural causes, with which we are as yet unacquainted.

The head is divided into the cranium, or skull, and face.

ADULT CRANIUM.

The shape of the adult cranium is in general spherical, but there is great variety in skulls. The superior part is arched; in some this arch is greater than in others: anteriorly it is more or less flattened, posteriorly more or less rounded, but always considerably more convex than on the anterior part: at the sides the cranium is flattened. There are a great number of processes and depressions on the under surface, so as to render it very irregular in its appearance.

The adult cranium is COMPOSED of eight bones—viz. one *os frontis*, which forms the forehead; two *ossa parietalia*, situated

at the upper part and sides of the head; two *ossa temporum*, placed below the parietal bones; one *occipital*, forming the back part of the head; one *sphænoidal*, placed in the middle of the basis of the cranium; and one *ethmoid bone*, situated behind the root of the nose.

Upon viewing the superior part of a skull externally, several *zigzag lines* are observable, called SUTURES:—that which extends from one temple across over the head to the other temple, is termed the *coronal suture*; it unites the frontal bone to the two parietal:—that which proceeds from behind one ear upwards, across to the other, is the *occipital*, or *lambdoidal suture*; it unites the occipital bone to the two parietal:—and the suture which extends upon the crown of the head, from the lambdoidal to the coronal, uniting the two parietal bones, is called the *sagittal*. These are sometimes termed the *true sutures*, to distinguish them from two *spurious* or *squamous*, which are found on each side of the cranium, extending from the temple backwards, in the form of an arch, and uniting part of the temporal bone to the parietal. Besides these two sutures, two other portions are to be noticed; the one belonging to the lambdoidal, the other to the squamous suture, being, in fact, continuations of them: the one is called *additamentum suturæ squamosæ*, the other *additamentum suturæ lambdoidali*. There are, sometimes, one or more triangular-shaped bones observed in the course of some of the sutures; these are called *ossicula triquetra, triangularia*, or *Wormiana*.

The chief use which arises from this partition of the cranium into so many pieces, seems to be to facilitate the ossification after birth, and to serve, in some measure, to prevent the spreading of fractures from one bone to another.

The formation of the sutures appears to be the effect of the particular manner in which the bones of the cra-

nium ossify. They are all more strongly marked on the external surface of the cranium. Towards old age bony matter is often deposited between the bones, so as to cause the sutures to disappear; and sometimes, though seldom, at a very early period. The author has in his collection the cranium of an African negro, who died before the age of twenty-eight, in which there is no vestige of the true sutures; and instances are related of the sagittal and coronal sutures being entirely obliterated in children of only eight years of age.

Besides these sutures, there are several *prominences* upon the upper part of the cranium; two in the frontal bone, one immediately over each eye, between it and the suture; one in the middle of each parietal bone; and one in the middle of the occipital: these point out the *centre of ossification* of those bones.

Upon the internal surface of the upper part of the cranium there are a number of *grooves*, in an arborescent form; these are made by the spinous artery of the dura mater. The sutures are here seen in the form of a line, not dove-tailed, and the whole surface appears more polished than the external.

The bones forming the upper part of the skull, or, as it is sometimes called, the *calvaria*, are composed of an *external* and an *internal table*, which are of a compact structure, and of a spongy intervening substance, called the *meditullium*, or *diploë*.

The internal surface of the basis of the cranium, is divided naturally into eight considerable *depressions*, adapted to the lobes of the brain and cerebellum. The two *anterior* are immediately over the orbits, and are separated from each other by an obvious eminence, above the root of the nose, called *crista galli*. Immediately before this eminence is a small hole called the *foramen cæcum*; and on each side of it are a number of perforations, which transmit the olfactory nerves into the nose; they are called the *foramina cribrosa*. Passing back-

wards, there are two round holes near each other, one going to the bottom of each orbit; these are for the passage of the optic nerves, and are called *foramina optica:* beyond these holes there is a small cavity, which will admit the end of one's little finger, surrounded by four processes, two of which are *anterior*, and two *posterior;* these are termed *clinoid processes*, and the cavity in their middle, which contains the pituitary gland, the *sella turcica*. Under each anterior clinoid process is a considerable fissure, the *foramen lacerum orbitale superius*, which communicates with the orbit, and transmits the third, fourth, the first branch of the fifth, and the sixth pair of nerves, and the ophthalmic artery. Beyond this fissure, proceeding backwards, there is a round and then an oval hole; the first is the *foramen rotundum*, through which the second branch of the fifth pair of nerves passes; the other, the *foramen ovale*, is for the passage of the third branch of the fifth pair of nerves. Contiguous to the foramen ovale is a small hole, the *foramen spinosum*, through which the spinous artery of the dura mater enters. Between the foramen ovale, and the posterior clinoid process, on each side of the sella turcica, there is a considerable ragged aperture, the *carotid canal*, which is partly filled up with cartilage in the fresh subject, and is for the entrance of the carotid artery, and the exit of the great intercostal nerve. A projecting portion of bone next presents itself, called the *petrous portion* of the tempora bone; it has upon its posterior surface an oval opening, the *meatus auditorius internus*, through which the nerve for the organ of hearing, and the facial nerve, proceed. Immediately below this is an irregular oval opening, formed by the junction of the occipital with the temporal bone; this is the *foramen lacerum in basi cranii:* through the anterior part of this opening passes the eighth pair of nerves, and the posterior

part transmits the blood from the lateral sinus of the dura mater, whose course is marked by a *deep groove* leading to the foramen lacerum, into the jugular vein. The portion of bone which proceeds backwards from the posterior clinoid processes, between the petrous portions of the temporal bone, is the *cuneiform*, or *basilary process* of the occipital bone; it is somewhat *hollowed* for the reception of the medulla oblongata, which lies upon it. At the bottom of this process of bone is a considerable opening, called the *foramen magnum occipitale;* it transmits the spinal marrow, the vertebral arteries, and the accessory nerves of Willis; and a process of the second vertebra of the neck lies in its anterior part. Between this opening, and the foramen lacerum in basi cranii, is the *foramen condyloideum anterius*, which gives passage to the ninth, or lingual pair of nerves. Beyond the great occipital foramen is a *crucial eminence*, to which processes of the dura mater are attached; the horizontal eminence separates the two *superior occipital cavities* from the two *inferior*.

The skull is divided into *calvaria* and *basis*. The calvaria comprehends all that portion situated *anteriorly*, about an inch above the nose, and half an inch above the orbits; laterally above the semicircular ridge of the parietal bones; and posteriorly about an inch above the occipital tubercle. The calvaria is the part which is sawed off, to examine the brain after death. The operation of *trepanning* may be performed on any part of the calvaria, avoiding, if possible, that part which lies over the sinuses of the dura mater.

The calvaria is sometimes very thick. It is not clear whether this be the effect of disease or not. It is, however, very probable, that in some instances it is the consequence of rheumatic inflammation.

The *diastasis*, or separation, and often the absorption, of the bones of the calvaria, are frequently the consequences of an accumulation of water within the skull.

FŒTAL CRANIUM.

The bones of the skull of a fœtus at birth, are far more numerous than those of an adult; for many of the processes of the latter are epiphyses in the former; thus the occipital bone consists of four portions; the sphænoidal of three, &c. There are no sutures in the cranium of the fœtus. The parietal bones, and the frontal bones, do not coalesce until the third year, so that before that period there is an obvious interstice, commonly called *mould*, and scientifically the *fontanel*, or *fons pulsatilis*. There is also a lesser space, occasionally, between the occipital and parietal bones, termed the *posterior fontanel*. These spaces between the bones are filled up by the dura mater, and the external integuments, so that, during birth, the size of the head may be lessened; for at that time the bones of the head, upon the superior part, are not only pressed nearer to each other, but they frequently lap one over another, to diminish the size during the passage of the head through the pelvis.

In the bones of the fœtal cranium, the fibres are seen diverging from a central point of ossification towards the circumference, and each bone appears to be composed of a single lamina; so that ossification is going on from a considerable number of points at the same time, and the bones consequently approach each other in the same proportion. After birth, the bones acquire greater thickness, and are soon observed to be composed of two laminæ of fibres, each of which laminæ are connected by the spongy part, called the diploë. These laminæ soon become the two tables of the cranium, and as the bones join each other, their edges become mutually indented, so as to form the different sutures.

OS FRONTIS.

Os Frontale.

The frontal bone is situated in the anterior part of the skull, forming the forehead and upper part of the orbits; it is of a semicircular shape, and when detached from the other bones of the cranium, has some resemblance to a cockle-shell. Externally, where it forms the forehead, it is very smooth and convex; but below, where it assists in forming the orbit, it affords several processes and cavities. The inner and concave surface of this bone is turned towards the brain, and in the centre of its inferior part is the ethmoid bone, which is placed at the top of the cavity of the nostrils. It sometimes consists of two portions, in consequence of the sagittal suture being continued down through its middle to the nose. This is more frequent in females than males.

Processes. Two *frontal eminences*, which mark the centres of ossification;—two *frontal tuberosities*, which are situated over the frontal sinuses;—two *superciliary ridges*, or *arches*, which give origin to the frontal muscles, and whose extremities are called the *angular* or *orbitar processes;* behind each external angular process, the surface of the bone is considerably depressed, for the situation of a part of the temporal muscle; this is called the *temporal fossa;*—an *external frontal spine;* called also the nasal process, upon which the ossa nasi rest; an *internal frontal spine*, to which the dura mater adheres;—and two *orbitar plates*, which separate the orbits from the cavity of the cranium.

Cavities. The *cerebral cavity*, which contains the anterior portions of the hemispheres of the brain;—a large *notch* between the orbitar plates for the situation of the cribriform plate of the ethmoid bone;—two *frontal*, or *pituitary sinuses*

within the bone, above the root of the nose; they are always separated by a thin bony partition, and open by two small holes into the nostrils, of which they form a part:—two *orbitar cavities*, in which are two depressions for the situation of the lachrymal gland;—a *notch* in each superciliary ridge for the trochlea of the superior oblique muscle;—a *superciliary foramen*, through which passes a small artery from within the cranium, together with a branch of the fifth pair of nerves, to be distributed to the muscles and integuments of the forehead; often a notch only is seen, and sometimes there are two foramina on one side, and one on the other;—the *anterior orbitar foramen*, which affords a passage to a branch of the ophthalmic artery, and a small twig of the fifth pair of nerves into the nose; this foramen is sometimes formed by the junction of the ethmoid bone with the frontal;—the *posterior orbitar foramen*, which is smaller than the former, and deeper in the orbit;—a *depression*, behind the middle of the superciliary ridge, for the situation of the lachrymal gland;—the *foramen cæcum*, situated below the beginning of the internal frontal spine;—slight *furrows* and *ridges* on the orbitar processes, occasioned by the convolutions of the brain.

CONNEXION. The frontal bone is connected with the two parietal, by means of the coronal suture; with the two ossa nasi, the two superior maxillary bones, and the two lachrymal bones, by means of what is called the *transverse suture;* with the sphænoid bone by means of harmony, called *harmonia sphænoidalis;* with the ethmoid bone by *harmonia ethmoidalis;* and with the os jugale by means of suture.

The USE of the frontal bone is to constitute the forehead pituitary sinuses, part of the orbit, and to contain and defend the anterior lobes of the brain.

The frontal bone at birth consists always of two portions. The superciliary arches, and orbitar plates, are distinctly formed, and sometimes the frontal sinuses.

When performing the operation of trepanning, the situation of the frontal sinuses, and the longitudinal sinus of the dura mater, should be remembered, and cautiously avoided.

Substances have been forced immediately over the internal angle of the orbit, some way into the skull, and never produced any symptom common to injuries of the brain. When removed, it has been ascertained that these substances were in the *frontal sinus.*

OSSA PARIETALIA.

Ossa bregmatis. Ossa syncipitis. Ossa verticalia. Ossa verticis.

The parietal bones are situated one on each side of the superior part of the cranium, and are considerably convex and somewhat quadrangular. Each bone is distinguished into an *external* and *an internal surface*, and four *angles*, viz. the *frontal*, *sphænoidal*, called also, the *spinous process*; the *occipital*, and *mastoid.*

EMINENCES and CAVITIES. A *semicircular* ridge, from which the temporal muscle originates;—a number of *furrows* marked by the fibres of the temporal muscle; and the *foramen parietale*, which is near the sagittal suture, and transmits an artery and a vein of the dura mater; in some skulls it is wanting, sometimes there are two on one side and none on the other. Upon its internal surface are the *grooves of the spinous artery*; and when the two bones are united, there is a deep *cavity* extending along the sagittal suture, for the longitudinal sinus of the dura mater.

Each parietal bone is CONNECTED with its fellow, by means of the sagittal suture; with the frontal bone by the coronal suture; with the occipital by the lambdoidal suture; and with the temporal by the squamous suture.

The USE of these bones is, to form the superior part of the cranium.

The parietal bone, at birth, consists of one portion, and partakes of the shape of the adult bone. It shews, very beautifully, the radiated bony fibres, and the centre of ossification.

The situation of the parietal foramen should not be forgotten; for when the artery which passes through it is divided, it sometimes bleeds very profusely, and being embedded, and somewhat retracted in the foramen, cannot be secured by a ligature. Instances, it is said, have occurred, where blood has collected from this cause between the dura mater and cranium.

A considerable fossa is sometimes found in the internal surface of these bones, near the longitudinal sinus; it is in consequence of the pressure of a protruding portion of the sinus, or of the external Pacchionian glands, by which absorption of the bone takes place.

The connexion of the parietal bones with the frontal, is well worthy of attention. In the middle of the coronal suture, where the os frontis, from its size and flatness, is the most in danger of being injured, it rests upon the arch formed by the parietal bones; whereas at the sides the parietal bones rest upon the os frontis, because the same arch is there in the greatest danger from pressure.

OS OCCIPITIS.

Os basilare. Os memoriæ. Os nervosum.

The occipital bone is situated in the posterior part of the head, and is somewhat of a quadrate oblong shape. The external surface of the occipital bone is convex, and very irregular, serving for the attachment of several muscles; the inferior portion of the bone is stretched forwards like a wedge, and at the base of this projecting portion are two condyles,

which serve for the articulation of the head with the first vertebra of the neck.

Processes. *Upon the external surface.* The *occipital tubercle*, in the middle of the bone to which the ligamentum nuchæ adheres; a *transverse spine*, proceeding from each side of the tubercle, to which the trapezius and complexus muscles are attached;—a *lesser transverse spine*, below the former, for the insertion of the recti muscles;—a *prominent ridge*, running downwards from the occipital tubercle, and forming, with the above-mentioned ridges, a *crucial spine*;—the *cuneiform*, or *basilary process*, situated before the great foramen upon which the basilary artery, and the medulla oblongata, lie;—two *condyloid processes*, or *condyles*, which are united to the first vertebra of the neck;—small *elevations*, about the foramen magnum, for the insertion of ligaments, by which the head is attached to the vertebræ of the neck: there is also a roughness round the roots of the condyles, for the attachment of their capsular ligaments.——*Upon the internal surface.* An *internal crucial spine*: the superior branch gives adhesion to the longitudinal sinus of the dura mater, the two lateral to the lateral sinuses, and the inferior to the septum cerebelli.

Cavities. The *foramen magnum occipitale*, through which the spinal marrow proceeds into the spine, and the vertebral arteries and accessory spinal nerves into the cranium;—two *anterior condyloid foramina*, for the passage of the lingual pair of nerves;—two *posterior condyloid foramina* (which are sometimes wanting), for the passage of the occipital vein into the lateral sinus;—two *notches*, which, with two corresponding notches of the temporal bones, form the *foramina lacera in basi cranii*, for the passage of the blood from the lateral sinuses into the jugular vein, and the exit of the par vagum;—a considerable *groove*, leading to the above notches, in

which the lateral sinuses are situated. The internal surface has also four considerable *depressions*, formed by the *crucial spine;* the two superior contain the posterior lobes of the brain, and the two inferior, the two lobes of the cerebellum.

Man being designed for an erect posture, the foramen magnum occipitale is placed nearly in the middle of the basis of the human cranium, at almost an equal distance from the posterior part of the occiput, and the anterior part of the lower jaw; whereas in quadrupeds it is nearer the back part of the occiput.

CONNEXION. The occipital bone is connected by the cuneiform process to the sphænoid bone, in the adult by synostosis; hence Professor Sœmmering describes them as one bone, *os occipito-sphænoidale;* but in youth by synchondrosis; with the two parietal, and two temporal bones by the lambdoidal suture; with the first vertebræ of the neck by ginglymus, and with the second by syndesmosis.

The USE of the occipital bone is to constitute the posterior and inferior part of the cranium; to contain the posterior lobes of the brain, the cerebellum, and medulla oblongata, and to serve for the articulation of the head with the spine.

If we except the petrous portion of the temporal bone, the occipital will be found much stronger than any other bone of the head. The reason of this, perhaps, is, that it has to defend the cerebellum, the least injury of which proves fatal; and perhaps, also, because the occipital bone is more liable to fracture, and less defended than the other bones; for when we fall forward, the hands naturally protect us; and if on one side, the shoulders greatly defend the head; but when a person falls backwards, the hind part of the head comes with considerable force against the earth.

The occipital bone, at birth, is formed of four portions, joined together by cartilages:—one large portion, which forms the hinder part of the head; no trace of

tubercle nor crucial spine is seen:—the cuneiform process;—and two portions between these, forming the sides of the foramen magnum, and the attachment with the atlas.

OS SPHÆNOIDEUM.

Os sphænoidale. Os multiforme. Os cuneiforme. Os pterygoideum. Os alæforme. Os vespertiliforme. Os polymorphon. Os vespiforme.

The sphænoidal bone is situated in the middle of the basis of the cranium, extending underneath, from one temple across to the other. Its figure is very irregular; and is compared by some to a bat with its wings extended.

PROCESSES. Two *alæ majores*, whose anterior part forms a portion of the orbit; the inner surface has lying upon it a portion of the middle lobe of the brain, and the whole external surface is covered by the temporal muscle.—*Upon the external surface.* Two *spinous processes*, which are two narrow points, projecting one behind each foramen spinosum. The *sphænoidal spine*, or *azygous process*, upon which the basis of the vomer lies;—two *pterygoid processes*, each of which is distinguished into a root, and two extended plates, or wings; one external, which gives origin, on its external surface, to the pterygoideus externus muscle, and on its internal surface, to the pterygoideus internus muscle; and the other internal;—two *hamular*, or *hook-like processes*, one on the end of the internal wing of each pterygoid process, over which the tendon of the circumflexus or tensor palati muscle turns.—*Upon the internal surface.* Two *alæ minores*, which form the upper part of the superior orbital fissures;—four *clinoid processes*, two *anterior* and two *posterior*;—the *processus olivaris* lying between, and a little behind the anterior clinoid processes.

Cavities. The *sphænoidal pituitary sinus,* which is in the middle of the bone, has a communication with the nostrils, and is divided by an intermediate septum ;—two *pterygoid depressions,* one between each greater and lesser wing, for the reception of a part of the palate-bone ;—two *foramina,* each leading to a canal, called the *pterygoid,* or *Viduan canal,* in the root of the pterygoid process, through which the recurrent or Viduan branch of the fifth pair of nerves passes into the cranium.—*Internally.* The *sella turcica,* or *ephippium,* which is surrounded by the four clinoid processes, and contains the pituitary gland ;—two *foramina optica,* one before each anterior clinoid process, which transmit the optic nerves ;—two *grooves,* one on each side of the sella turcica, between the anterior and posterior clinoid processes, formed by the pulsation of the carotid arteries ;—two *foramina lacera orbitalia superiora,* between each greater and lesser wing, through which the third, fourth, first branch of the fifth, and the sixth pair of nerves, and the ophthalmic artery, pass out of the cranium ;—two *foramina rotunda,* for the passage of the second branch of the fifth pair of nerves ;—two *foramina ovalia,* for the third branch of the fifth pair ;—two *foramina spinosa,* through which the spinous artery of the dura mater enters the cranium.

Connexion. The sphænoid bone is connected with all the bones of the cranium ; with the frontal, the ethmoid, the two parietal, and the two temporal by harmony, and with the occipital by synostosis : it is also united to the two cheek-bones, the two superior maxillary bones, and the two palate-bones by harmony, and to the vomer by gomphosis.

Use. The use of this bone is to form the basis of the cranium, to concur in forming the orbits, the pituitary sinuses of the nose, the temples, and to contain the middle lobes of the brain.

The sphænoid bone, at birth, consists of five portions, joined together by strong cartilages; one in the middle surrounding the pituitary gland, the two *alæ majores*, and the two pterygoid processes. There is no sphænoidal sinus formed. The clinoid processes and *alæ minores* are cartilaginous.

OSSA TEMPORALIA.

Ossa temporum.

The temporal bones are of an irregular figure, and are situated at the sides and inferior part of the cranium, containing within them the organ of hearing. Each bone is divided into a *squamous portion*, which is flat, and forms the squamous suture, and a part of the side of the cranium; and a *petrous portion*, sometimes termed the *os petrosum*, which is very irregular, and is situated in the basis of the skull; it is a hard, craggy protuberance, nearly of a triangular shape, and surrounds the organ of hearing; and below this petrous portion is a concave angular projecting portion, which forms a part of the lambdoidal suture.

Processes. The *zygomatic process*, which, with a process of the os jugale, forms the *zygoma*, yoke, or arch of the temples, underneath which the temporal muscle moves, and from whose lower edge several muscles of the face arise, particularly the masseter and zygomatic. The *mastoid*, or *mammary process*, which projects from under the ear, and has inserted into its anterior part, the sterno-cleido-mastoideus muscle; and into its posterior part the complexus, the obliquus, and trachelo-mastoideus. The *styloid process*, which is long and pointed, and gives origin to a ligament of the os hyoides, also to the stylo-hyoideus, stylo-pharyngeus, and stylo-glossus muscles. The *vaginal process*, which surrounds the root of the styloid. The *auditory process*, or outer bony circle of the

auditory passage, to which the membrana tympani, and cartilage of the ear are fixed. The *pars petrosa* on its internal part, with a ridge on its surface, for the attachment of the tentorium.

CAVITIES. The *meatus auditorius externus*, which leads to the cavity of the organ of hearing;—the *meatus auditorius internus*, which begins on the internal and posterior surface of the petrous portion, and transmits the seventh pair of nerves; it has immediately within it, the internal opening of the aqueduct of Fallopius, and other foramina at its bottom, for the branches of the portio mollis;—the *aqueductus cochleæ*, and *aqueductus vestibuli*, situated behind the meatus;—the *foramen innominatum* seen on the anterior surface of the pars petrosa leading backwards to transmit the Vidian nerve;—the *glenoid cavity*, between the zygomatic auditory, and vaginal processes, which serves for the articulation of the lower jaw, and is separated in the middle by the glenoid fissure, into which the ligament that secures the articulation of the lower jaw with this bone is fixed;—a considerable *groove* behind the mastoid process, from which the digastric muscle arises; the *foramen mastoideum*, situated at the back of the process, not always to be found, but when present, it either transmits a vein to the lateral sinus, or an artery to the dura mater;—the *foramen stylomastoideum*, so called, from its situation between the styloid and mastoid processes; it is also called the aqueduct of Fallopius, and transmits the facial nerve;—the *fossa jugulis*, a thimble-like cavity, situated below, and on the fore part of the foramen stylomastoideum, the beginning of the internal jugular vein occupies this cavity;—the *canalis caroticus*, which begins before and a little above the jugal fossa; it first runs upwards, and then forwards, forming a kind of elbow, and terminates at the end of the petrous portion.

Through this serpentine canal the internal carotid arteries proceed to the brain, and two filaments of the intercostal nerve pass out to form the great intercostal nerve;—the *Eustachian tube,* which runs outwards and backwards in an horizontal direction, until it terminates in the cavity of the ear, called the tympanum;—the *hiatus Fallopii,* a small foramen, situated within the skull, about the middle of the anterior surface of the petrous portion; it receives a twig of the portio dura;—a *furrow,* in which a part of the lateral sinus is received.

Connexion. Each temporal bone is united to the parietal by the squamous suture; with the occipital by the lambdoidal suture; with the sphænoid and jugal bones by harmony, and with the lower jaw by arthrodia.

Substance. The squamous portion consists of two tables and a diploë; the mammary process, of cells which communicate with the cavity of the organ of hearing; and the petrous portion is very hard and compact.

Use. To contain the middle lobes of the brain, and the organ of hearing; and to concur in forming the temples and the basis of the cranium.

The temporal bone, at birth, consists of three portions: the squamous, the petrous, and a *ring-like bone,* which surrounds the opening of the tympanum. The last bone is seen completely ossified at the fourth month after impregnation: it is not a ring, though termed *annulus osseus,* for its ends do not meet. After birth, this portion is gradually elongated to form the meatus auditorius externus. It is within the petrous portion that the organ of hearing is situated, which is perfectly formed at birth. See *Cavity of Hearing.*

An operation is sometimes performed on the mastoid process of this bone, to remedy deafness: it consists in removing a portion of the bone by an instrument of the trephine kind, and forming a communication of the

external air through the mastoid cells with the cavity of the tympanum. A much more simple, and perhaps more certain, operation for this purpose, is perforating the *membrana tympani.*

OS ETHMOIDEUM.

Os ethmoidale. Os cribriforme. Os cribrosum.

The ethmoid bone is a four-side bone, situated in the anterior part of the basis of the skull, behind the root of the nose, and between the orbits.

PROCESSES. A *cerebral*, or *cribriform plate*, which lies horizontally above the root of the nose, within the cavity of the cranium : it is every where perforated by a number of small foramina, through which the olfactory nerves pass into the cavity of the nostrils. The *crista galli*, a process somewhat like a cock's comb, which proceeds upwards from the middle of the cribriform plate, and has attached to it the falciform process of the dura mater. Two *orbitar plates*, called also *ossa plana*, and *plana papyracea*, which are very smooth externally, and form the inner side of the orbits. The *septum ethmoidale, nasal plate, azygous process*, or *perpendicular lamina*, a considerable process, descending directly under the crista galli, into the cavity of the nose, and forming with the vomer the septum narium. Two *cavernous substances*, which are curled like a piece of parchment, one on each side of the septum, called improperly the superior turbinated or spongy bones, and *conchæ superiores.*

CAVITIES. A number of *cribriform foraminula*, situated on each side of the crista galli. Two *foramina orbitalia nasi*, one situated in the line of union between the frontal bone and orbitar plate of the ethmoid, for the passage of the nasal branch of the orbital nerve. A number of *cells*, which

compose the internal part of the bone, and form the pituitary sinuses of the ethmoid bone.

CONNEXION. The ethmoid bone is united to the os frontis, the two nasal bones, the two superior maxillary, the two palatine, the sphænoid bone, and the vomer, by harmony.

USE. To form an extensive surface for the organ of smell, and to constitute part of the nose, orbits, and cranium.

The ethmoid bone, at birth, is mostly cartilaginous ; part of the septum ethmoidale, however, consists of bony matter, and the superior turbinated bones are occasionally found ossified.

Of the Face.

The bones of the face are fourteen in number, and consist of those of the upper and under jaw. The upper jaw is formed of thirteen bones, viz. two superior maxillary, two nasal, two palatine, two jugal, or malar, two inferior spongy, two lachrymal, and the vomer, which are united to the cranium, and with one another by harmony. The under-jaw consists of one bone.

There is an obvious *line*, beginning at the external angle of the orbit, where the frontal bone is united to the cheek-bone, which leads to the inferior opening in the orbit, proceeds upwards to the nose, whose root it crosses, and then traverses the other orbit to the external angle : this is called the *transverse suture*. The other harmonies of the face are named after the bones which they unite, as the *zygomatic*, *nasal*, *palatine harmonies*, &c.

OSSA MAXILLARIA SUPERIORA.

The superior maxillary bones are two hollow bones, situated in the anterior and middle part of the face, and assist in

forming the nose, orbit, and palate; so that their shape is very irregular.

PROCESSES. The nasal process, which forms the side of the nose. The *orbitar process*, or *plate*, which forms part of the orbit. The *malar process*, by which it is united to the cheek-bone. The *alveolar process*, in which the teeth are situated. The *palate process*, which forms the palate. A *spine*, formed by the union of each palate portion, upon which the vomer rests:—a *ridge* on the internal part, on which the os spongiosum inferius rests:—the *orbital margin*:—the *tuberosity* at the back part of the bone.

CAVITIES. The *antrum maxillare*, called also *antrum Highmori*, and *sinus maxillaris pituitarius*, in the body of the bone, between the orbital and palate processes; it has an opening into the nostrils. The *infra-orbital canal*, which opens under the margin of the orbit, and transmits the infra-orbital nerve. The *lachrymal depression*, situated in the superior and internal part of the nasal process, for the situation of the lachrymal sac; it leads to the *canalis nasalis*, or *ductus ad nasum*, which conveys the tears into the nostrils. The *posterior palatine foramen*, near the last tooth on the inside, for the passage of the alveolar nerve. A *notch* on the anterior part of the palatine process, which, with the corresponding notch of the other superior maxillary bone, forms the *foramen palatinum anticum*, or *foramen incisivum*, which transmits the anterior palatine nerve and artery.

CONNEXION. Each superior maxillary bone is connected with its fellow, with the os frontis, one os nasi, one lachrymal bone, the ethmoid, sphænoid, one os jugale, one palatine bone, and one inferior spongy bone, by harmony; and with the vomer and teeth by gomphosis.

USE. The use of these bones is to form part of the face,

palate, nose, nostrils, and orbits, and to afford a convenient situation for the organ of mastication.

The superior maxillary bone, at birth, consists of one portion; so that every process and cavity can be seen, but not so perfect as in the adult. The alveoli are fewer in number.

When an abscess forms in the antrum of Highmore, it is necessary to perform an operation, to give an exit to the pus. This consists in perforating the parietes of the cavity, and surgeons mostly employ a species of trocar for this purpose. If the first dens molaris under the affected antrum be in its socket, it is to be drawn, and the trocar thrust through the alveolus into the antrum.

OSSA MALARUM.

Ossa jugalia. Ossa zygomatica.

The cheek-bones are situated at the sides of the face, and are nearly of a quadrangular shape.

PROCESSES. The *upper orbitary process*, which forms part of the orbit and the sharp edge of the temple. The *inferior orbitary process*, opposite to the former, and constituting in part the bottom of the orbit and the edge of the cheek. The *internal orbitary process*, which also forms a part of the orbit. The *maxillary process*, by which it is joined to the superior maxillary bone. The *zygomatic process*, which is joined to the temporal bone, to form the zygoma.

CONNEXION. The os jugale is united to the frontal, superior maxillary, sphænoid, and temporal bone, by suture.

USE. To assist in forming the face and orbits.

Every part of the jugal bone is formed at birth, but the shape is rather more triangular.

OSSA NASI.

Ossa nasalia.

The bones of the nose are of an oblong and quadrangular shape, are formed of a very compact substance, and are placed close to each other in the superior and middle part of the nose, in such a way as to form a strong arch, called the bridge of the nose.

In each bone may be noticed an *external* and an *internal surface*, and four margins. There is always a small foramen in each bone, for the passage of blood-vessels and nerves.

USE. To form the bridge and external part of the nose.

CONNEXION. Each bone is connected with its fellow, and the superior maxillary bone, by harmony, and with the frontal and ethmoid by the transverse suture.

The *ossa nasi* are perfectly formed at birth.

OSSA LACHRYMALIA.

Ossa unguis.

The lachrymal are two flat quadrangular bones, resembling somewhat the nail of the finger, situated one in each orbit at the internal angle, and separating the orbit from the nostrils. The surface towards the eye is concave, and has a *fossa*, or groove, in which the lachrymal sac is situated. The internal surface is convex, and covers some of the ethmoid cells, and part of the nostril.

CONNEXION. Each bone is connected with the frontal, ethmoid, superior maxillary, and inferior spongy bone, by harmony.

The USE of these bones is to assist in covering the labyrinth of the nose, in forming the orbit, and to afford a situation to the lachrymal sac.

They are completely formed at birth.

These bones are subject to caries from *fistula lachrymalis.*

The lachrymal bone is perforated obliquely downwards in the operation for fistula lachrymalis, in order that the tears may be conveyed into the nostrils.

OSSA SPONGIOSA INFERIORA.

Ossa turbinata inferiora. Conchæ inferiores.

The inferior spongy bones are situated in the side and lower part of the nostrils, and are of a spiral and convoluted figure. They are concave towards the antrum of Highmore, and convex towards the septum nasi.

USE. To augment the surface of the organ of smelling.

CONNEXION. Each bone is united with the superior maxillary, the palate, lachrymal, and ethmoid bone, by harmony.

The inferior spongy bones are subject to caries, and total destruction, from the venereal disease, and nasal polypi

OSSA PALATINA.

Ossa palati.

The palatine bones are extremely irregular in their shape and are situated in the posterior part of the nose, from which they ascend laterally to the orbits. This irregularity of their figure, and their situation being so varied, gives rise to their division into palatine, pterygoid, nasal, and orbital portions.

PROCESSES. The *palatal plate*, which forms the posterior part of the roof of the mouth. The *spinous process*, at the inner edge of the palate-plate, joining the under-edge of the vomer. The *pterygoid process*, which is situated behind the last grinder. The *nasal process*, which arises perpendicularl

from the palate, and covers a part of the antrum of Highmore. The *orbitary process*, which is situated in the orbit.

Cavities. The *palatine cells*, which communicate with, and form part of the sphænoid cells.

Use. To form the posterior part of the palate, and part of the nose and orbit.

Connexion. Each bone is united to its fellow, the superior maxillary bone, the sphænoid, ethmoid, inferior spongy bone, and vomer, by harmony.

The *ossa palatina* are very perfectly formed at birth, but cannot, without great difficulty, be separated from the surrounding membranes.

VOMER.

The vomer is a bone situated perpendicularly between the roof of the mouth and the septum ethmoidale, in the cavity of the nostrils, which it divides into two parts. It bears some resemblance to the ploughshare used in former times.

Use. To sustain and divide the cavity of the nostrils.

Connexion. Superiorly it is united with the sphænoid bone by gomphosis, and with the ethmoid by harmony; inferiorly with the superior maxillary and palatine bones by harmony; anteriorly it is united to the cartilaginous septum of the nose.

The vomer, at birth, consists of two distinct *lamellæ*, with an intervening cartilage.

It is not unfrequently destroyed by venereal caries.

OS MAXILLARE INFERIUS.

Mandibula.

The lower jaw is shaped somewhat like a horse-shoe, and occupies the inferior and anterior part of the face.

Processes. Two *condyloid*, or *articulatory processes*, which are received into the articulatory cavities of the temporal bones. Two *coronoid processes*, which are sharp-pointed, and give adhesion to the temporal muscles. The *alveolar process*, in which the teeth are fixed. The *symphysis* of the jaw, in the middle of the chin. A *ridge* on the fore-part of the chin, for the attachment of muscles. *Small eminences* behind the symphyses for the attachment of the frænum linguæ, and muscles of the throat. The *inferior margin*, whose ends form the angles of the jaw.

Cavities. A *semilúnar notch*, between each coronoid and condyloid process. *Grooves* made by the masseter muscle. The *alveoli*, or cavities in which the teeth are fixed. Two *posterior maxillary formina*, one above each angle, on the inner surface of the jaw, which transmit the lower maxillary nerve and artery into a *canal* in the middle of the bone, called *canalis mentalis*, which conducts the same artery and nerve to the *anterior maxillary foramina*, upon the external surface of the bone, one on each side of the chin, from whence the artery and nerve again emerge upon the chin.

Use. To retain the roots of the teeth in the alveolar margin; to constitute the inferior segment of the cavity of the mouth, and to afford a point of adhesion to the muscles of the face, neck, larynx, and tongue.

Connexion. The lower jaw is united to the temporal bones by ginglymus, with the teeth by gomphosis, and with the os hyoides and other parts by syssarcosis.

Joint. The *ginglymus joint* of this bone, with the os temporis, is formed by the large articular cavity of the latter receiving the condyloid process of the lower jaw. In this joint there is a moveable *interarticular cartilage*, which is very closely connected to the condyloid process and the articular

cavity, by ligaments arising from their edges, and the whole is surrounded by a capsular ligament, fixed to the temporal bone and the neck of the condyle. By the peculiar formation of this joint, the lower jaw has many motions; thus, when the condyles slide forwards, the lower jaw passes horizontally forwards, as in the action of biting; or the condyles only may be brought forwards, while the rest of the jaw passes backwards, as is the case when the mouth is open. The condyles may also slide alternately backwards and forwards, and *vice versâ*, so that while one condyle advances, the other moves backwards, turning the body of the jaw from side to side, as in grinding the teeth. The principal use of the interarticular cartilages, seems to be that of securing the articulation, by adapting themselves to the different inequalities in these several motions of the jaws, and to prevent any injuries from friction.

The lower jaw, at birth, consists of two pieces, which meet at the symphysis.

Besides the usual diseases of bones, the author has seen one case of necrosis of this bone, in which the whole of the lower jaw came away at four different times; and another, where one half came away at one time. The former was under a long-continued salivation; the latter from an abscess destroying the nutritious artery. Their loss was supplied by a very firm body of bone.

Of the Cavities formed by the Bones of the Face and Cranium.

The cavities which are formed by the junction of the bones of the face and cranium are, the orbits, nostrils, mouth, in which are the teeth, the fauces, in the anterior part of which is the os hyoides, and the cavity of hearing, situated in the temporal bone.

ORBITS.

The orbits are two conoidal cavities, situated under the forehead, and on each side of the root of the nose. The angles of the orbits are called *canthi*.

CAVITIES. A *depression* for the lachrymal gland ;—a *notch* of the orbital trochlea ;—a *depression* for the lachrymal sac ;—the *canalis nasalis*, or *ductus ad nasum*, for the passage of the tears ;—a *superior* and *inferior*, or *sphæno-maxillary orbital fissure* ;—the *superciliary foramen* ;—the *infra-orbital canal* ;—the *foramen nasale*, and the *optic foramen.*

Seven bones enter into the *formation* of each of these cavities, viz. the frontal, maxillary, jugal, lachrymal, ethmoid, palatine, and sphænoid.

USE. The use of the orbits is to contain and defend the organ of sight and its adjacent parts.

CAVITY OF THE NOSTRILS.

The nostrils are two pyramidal cavities, situated under the anterior part of the cranium, in the middle of the face, and covered anteriorly by the nose.

PROMINENCES. The *septum narium* ;—the *cavernous substance* of the ethmoid bone, improperly called the superior spongy bones ;—and the *inferior spongy bones.*

CAVITIES. Three pair of *pituitary sinuses*, namely, the frontal, sphænoid, and maxillary ;—the *caverns* of the ethmoid labyrinth ;—the *anterior foramina* of the nostrils ;—the *ductus nasalis* ;—the *sphæno-palatine foramina* ;—and the *anterior palatine foramina.*

The nostrils are composed of fourteen bones, viz. the frontal, two maxillary, two nasal, two lachrymal, two inferior spongy, the sphænoid, vomer, ethmoid, and two palatine bones.

USE. The use of these cavities is to form a situation for the organ of smelling, and the pituitary membrane of the nostrils, and to serve also for speech and respiration.

CAVITY OF THE MOUTH.

The cavity of the mouth is situated between the upper and under jaw, and is covered laterally and anteriorly in the fresh subject by the cheeks and lips; posteriorly it is continued into the fauces. The two superior maxillary bones, and the palatine portions of the palate bones, form the superior part of the mouth, and anteriorly it is closed by the teeth.

TEETH.

The teeth are hard bones, partly covered with a peculiar substance, called *enamel*, and fixed one after another in the upper and under jaw, in such a manner, that in the adult there are sixteen belonging to each.

Every tooth is divided into a *crown*, which is covered by the enamel; a *neck*, or that part embraced by the gum; and a *root*, also called the fang, which is hidden within the socket. There is a *foramen* at the fang of each tooth, leading into a cavity for the entrance of the vessels and nerves to the pulps.

There are four kinds of teeth: *incisores*, *cuspidati*, *bicuspides*, and *molares*.

The INCISORES are eight in number, four in each jaw; they are situated in the front of the mouth, and are flat and sharp-edged, so as to cut the food; the roots or fangs are simple; those of the upper jaw are fixed obliquely backwards, so that they generally cover a small part of the incisors of the under-jaw.

The tooth on each side of the incisors is called CUSPIDATUS, or canine; they consequently are four in number. The fang of these teeth is single, and goes a considerable way in the jaw, especially the two of the upper jaw, which were supposed to go to the eye, and are therefore called the eye-teeth. The oral part of the cuspidati is rounded, and their end pointed, as their name implies.

The BICUSPIDES are eight in number, two being situated next to each cuspidatus; they appear at both extremities, as if they were formed by the junction of two incisors.

The MOLARES are twelve in number, and situated three at the extremity of each jaw. The fangs of these are varied; those of the under jaw have two, and those of the upper three. Their oral extremities are full of irregularities, so that they are able to grind the food between them. The two last molares are distinguished by the name of *dentes sapientiæ;* they are always the last that appear, and not unfrequently the first which decay: their fangs are squeezed, as it were, into one.

The teeth are fixed in the alveoli of the jaws by gomphosis, so that each tooth fills up its appropriate socket, which is separated from the next by an intermediate, thin, spongy, partition.

The arteries of the teeth are branches of the internal maxillary, the veins empty their blood into the internal jugulars.

The nerves of the teeth are from the fifth pair.

In the four-month's fœtus, several pulpy substances are observed in the alveoli, which are the rudiments of the future teeth. These pulpy substances consist of a gelatinous fluid, which is inclosed by a very vascular capsule. As the fœtus advances, the pulps become firmer and extremely vascular, and having increased to near the size of the body of the tooth, bone is deposited upon their extreme points, which by degrees forms an osseous shell, that extends over the surface of the pulps to the neck of the tooth. After the outer shell of a tooth is formed, bony matter gradually penetrates the greater part of the pulp, so as to form the body and cervix of the tooth; the cavity of the tooth is by degrees filled up, and the part of the pulp is pushed down, so as to form the place of the fang, which soon becomes ossified.

As the bony substance is formed, the enamel is secreted by the capsule which contains the pulp, and increases in thickness till within a little time before the tooth is about to pass through the gums.

In proportion as the teeth extend in their sockets, they press upon the capsules, and occasion their absorption.

In children, soon after birth, a double order of teeth is hidden in their sockets by the gums. The superior protrudes through the gums about the seventh month, which is called the cutting of the teeth; first the incisors, then the molares, and, last of all, the cuspidati. These teeth are termed *milk*, *shedding*, or *primary*: they gradually fall out about the seventh year, and are succeeded by the other order, which till now had been concealed in the bottom of the alveoli.

The teeth are very subject to caries, which may arise from an internal, though it mostly does from an external cause.

There are a variety of operations performed on the teeth: extraction and scaling are the chief.

CAVITY OF THE FAUCES.

This cavity is situated under the basis of the cranium, within the superior bodies of the vertebræ, and posterior part of

the nostrils. It is composed of ten bones, viz. the occipital, two palatine, the vomer, the bodies of the three first vertebræ, the os hyoides, and the two temporal bones.

USE. For the situation of the fauces, larynx, pharynx, and os hyoides.

OS HYOIDES.

Os linguale.

The os hyoides is a bone of a semilunar shape, situated in the fauces, between the basis of the tongue and the larynx.

PROMINENCES. Two *cornua majora*, and two *cornua minora*.

USE. To serve for the adhesion of the tongue, for deglutition, and for a point of adhesion to many muscles.

CONNEXION. It is connected to the styloid process of the temporal bone, the scapulæ, lower jaw, and sternum, by various muscles, and with the larynx by ligament.

CAVITY OF HEARING.

This cavity is situated within the petrous portion of the temporal bones, and consists of the meatus auditorius externus, the cavity of the tympanum, and the labyrinth.

The *meatus auditorius externus* is somewhat funnel-shaped, and terminates in a larger cavity, which is the tympanum, and from which it is separated, in the fresh subject, by a membrane.

The TYMPANUM is an irregular cavity, covered, in the fresh subject, by a membrane: it contains four bones, called *ossicula auditûs*. One is hammer-shaped, and therefore termed the *malleus*; it has a round head, a narrow neck, a manubrium, or handle, and two small processes. Another, formed of two legs, or crura, and a body, is called the *incus*.

The third, resembles a stirrup in miniature, and is therefore named *stapes*. The fourth is a very small round particle of bone, not larger than the third part of a pin's head; it is generally found adhering to the long crus of the incus, and is termed *os orbiculare*. These bones are placed in the following order:—the head of the malleus is turned upwards, and its handle rests on the tympanum; the body of the incus is attached to the head of the malleus; the short crus is attached by ligament to the edge of the mastoid opening, and extends backwards; the long crus is turned downwards, at the extremity of which the os orbiculare is fixed; the head of the stapes is attached to the os orbiculare, and its crura and base lie in an horizontal direction over the fenestra ovalis. There are many *inequalities* in the cavity of the tympanum, and the five following foramina:

1. The *opening of the Eustachian tube*, situated anteriorly; 2. A *canal*, in which the tensor tympani muscle is fixed, which extends from the former opening to the fenestra ovalis; 3. An oval opening, called *fenestra ovalis*—the stapes is attached to this opening; 4. The *fenestra rotunda*, which is less than the former; 5. An *opening* leading to the mastoid cells.

The LABYRINTH is composed of three parts; the vestibulum, cochlea, and semicircular canals. They are placed behind the cavity of the tympanum.

The VESTIBULUM is an equally rounded cavity, situated between the cochlea and semicircular canals. It has seven openings into it: five of the semicircular canals, the fenestra ovalis, by which it communicates with the tympanum, and an opening into the cochlea, called *scala vestibuli*, besides many perforations for the transmission of nerves. There is also to be noticed in the vestibulum, a small *spinous process*, to which the barbula adheres; and several *depressions*, cor-

responding with the alveus communis, and the ampullæ of the membranaceous semicircular canals, which are described in *Splanchnology*.

The COCHLEA has obtained its name from its figure: it has a bony nucleus in the middle, formed of two hollow cones, placed with their points to each other; one is called *modiolus*, the other *infundibulum*; and two spiral windings, like those of a snail's shell: that which opens into the tympanum, by the fenestra rotunda, is called *scala tympani*; the other communicates with the vestibule, and is termed *scala vestibuli*. These *scalæ* communicate with one another at the top of the *modiolus*. The partition between the wings is called the *spiral lamina*; it is partly bone, and partly membranous. The cochlea is divided into base and apex, or *cupola*; the base, containing the modiolus, is placed towards the meatus auditorius internus, and its apex, with the infundibulum, outwards.

The SEMICIRCULAR CANALS are three in number: one inferior and posterior, one superior and middlemost, and one exterior and foremost. They open into the vestibule, and contain the membranaceous semicircular canals.

In the fœtus the squamous and petrous portion are divided by a cartilaginous substance. In consequence of the bony fibres being much more delicate than in the adult bone, very beautiful preparations of the bony organ of hearing can be made by cutting away the surrounding parts: thus,

1. Take the petrous portion of a five-month's fœtus, cut away with a scalpel the bone from around the cochlea, which at this period is closed by a firmer lamina of bone than that which surrounds it: and in this way the cochlea will resemble exactly a snail-shell in miniature.

2. Cut away the surrounding bone from the semicircular canals, and expose the vestibulum, by enlarging the foramen ovale.

3. Make sections of the vestibulum to shew its depressions, and the openings of the semicircular canals, and the scala vestibuli.
4. Cut away the bony lamina surrounding the scalæ of the cochlea, to shew the spiral zone which separates the two scalæ, and to exhibit the modiolus.

These are all the circumstances to be noticed in the dry bone, connected with the organ of hearing. The soft part which are placed in this cavity, and which form the immediate organ of hearing, are considered in *Splanchnology*.

Of the Trunk.

The trunk of the skeleton is divided into the spine, chest, loins, and pelvis.

SPINE.

Columna spinalis. Columna vertebralis. Theca vertebralis. Spina dorsi.

The spine is a long, bony, and cartilaginous hollow column, extending from the occipital bone of the head, down to the os sacrum, in the posterior part of the trunk. In the neck it projects somewhat forward to support the head, which would otherwise require a greater number of muscles. Through the whole length of the thorax it is carried in a curved direction, backwards, and thus adds considerably to the cavity of the chest. In the loins the spine again projects forwards in a direction with the centre of gravity.

The spine is formed of twenty-four bones, called VERTEBRÆ, which are very intimately connected together.

Some anatomists consider the spine as extending from the head to the os coccygis, thereby including the sacrum and os coccygis, and compare them to two

irregular pyramids, which are united at their basis in the loins, where the last lumbar vertebra joins the sacrum. The bones of the upper pyramid, or what is generally called the spine, are termed *true vertebræ*, whilst the sacrum and os coccygis, which form the lower pyramid, are said to be composed of *false vertebræ*, because they do not resemble the others in every respect.

The vertebræ, from their situation with respect to the neck, back, and loins, are divided into *cervical*, *dorsal*, and *lumbar*; and each of these classes have particular characters.

Each vertebra is divided into surfaces, margins, a body, processes, and cavities.

The BODY is the thickest and foremost part, anteriorly convex, and posteriorly concave; its upper and under surfaces are somewhat hollowed, and covered with cartilage of a particular nature, called *intervertebral substance.*

PROCESSES. The processes of a vertebra are seven; two *transverse processes*, one on each side, and so named from their situation with respect to the spine;—the *spinous process*, extending outwards posteriorly: it gives the name of *spine* to the whole of this bony canal. The four remaining are processes, called *oblique*, and also *articular*; they are much smaller than the others, and two are placed on the upper, and two on the lower part of each vertebra, rising from near the base of the transverse processes. These four processes are covered with cartilage, and the two superior of one vertebra are articulated with the two inferior processes of the vertebra above it; around their edges a roughness is observed, for the attachment of the articulating ligaments.

CAVITIES. There is a considerable *foramen* in each vertebra, the anterior part of which is formed by the body, and the posterior by the spinous process: it is through this foramen the spinal marrow passes. There are also four *notches* in each vertebra; two on each side, one superior, the other

inferior. When two vertebræ are put together, the corresponding notches form *foramina*; and it is through these foramina that the spinal nerves pass out, and blood-vessels enter.

STRUCTURE. There is a considerable difference in the size, density, and firmness of the vertebræ. As they proceed from the head downwards, they gradually become larger, and in proportion as they increase in size, they diminish in density and firmness of texture; so that the lower vertebræ, though larger, are not so heavy, in proportion, as those above them. In consequence of this mode of structure, the size of the vertebræ is increased, without adding to their weight.

CONNEXION. The first bone of the spine is connected with the occipital bone by *ginglymus*; the second vertebra is united with the first by *trochoides*, and with the occipital bone by *syndesmosis*. The bodies of the vertebræ are connected with one another by the intervertebral substance; and posteriorly by a yellow elastic ligament, and by their oblique processes.

The *intervertebral substance* is of a particular nature; it is compressible like cork: in the fœtus it resembles more the structure of ligament, and in the adult it has a great similitude to cartilage. When cut horizontally, it appears to consist of concentral curved fibres. Externally it is firm and hard, internally it becomes thinner and softer, and in the centre it is like mucus. A considerable change takes place in the substance in advanced life, when it becomes shrivelled, and loses in a great measure, its elasticity, which occasions the decrease in stature, and the stooping forwards. Besides this change in old age, this substance also undergoes a temporary diminution, after the full growth of the subject, from the weight of the body in an erect posture; so that people who have been

long standing, or have carried a considerable weight, are found to be shorter than when they have been long in bed: hence we are taller in the morning than at night.

JOINTS. 1st. It is by means of the joint formed by condyles of the occipital bone, with the articular cavities of the atlas, that the motion of the head backwards and forwards is performed, as in nodding. This joint is surrounded by capsular ligaments, and is strengthened by several others.

2d. The *trochoid joint*, formed by the anterior arch of the atlas moving round the odontoid process of the dentatus, enables the head to rotate, as in moving from side to side: but as the head cannot move sufficiently around the dentatus, without injuring the medulla spinalis, all the cervical vertebræ likewise concur in this rotatory motion, when in any considerable degree. Strong ligamentous fibres pass from the sides of the odontoid process, over the atlas to the os occipitis, which strengthen the articulation, and limit its motion. The odontoid process is retained in its situation by the transverse ligament of the atlas.

The USE of the spine is to support the head and trunk, and to contain and defend the spinal marrow.

CERVICAL VERTEBRÆ.

These are seven in number; their bodies are smaller, and of a firmer texture than the other vertebræ. The transverse processes are short and bifurcated, and there is a foramen in their basis peculiar to them, for the passage of the vertebral artery and vein. The spinous processes are also forked, are shorter than those of the other vertebræ, and are much more inclined downwards. The oblique processes are more deserving of that name than either those of the dorsal or lumbar vertebræ

The two first of the cervical vertebræ differ from the rest: the first is called ATLAS; it has no body nor spinous processes, but forms an *arch*, which anteriorly surrounds the dentiform process of the second vertebra. Instead of upper oblique processes, there are two *articular sinuses*.

The second vertebra is termed DENTATUS EPISTROPHÆUS; and *dentata*. An *odontoid*, or *dentiform process* at the upper part of the body is peculiar to it.

DORSAL VERTEBRÆ.

These are twelve in number. They are distinguished by a *depression* at the sides of their bodies, and a superficial one in the points of the transverse processes, for the attachment of the great and little heads of the ribs.

The bodies of these vertebræ are more flattened at their sides, more convex before, and more concave behind, than the other bones of the spine: their upper and lower surfaces are horizontal. The spinous processes are long, flattened at their sides, divided at their upper and back part into surfaces, by a middle ridge, which is received by a small groove in the inner part of the spinous process, immediately above it, and connected to it by ligament: they are terminated by a kind of round tubercle. The transverse processes are of considerable length and thickness, and are turned obliquely backwards.

LUMBAR VERTEBRÆ.

The lumbar vertebræ are five in number; they are much larger than the dorsal, and the transverse processes have no depressions.

The vertebræ, at birth, consist of three parts, connected together by cartilage; one of these is the body, and the other two the transverse processes. The anterior

part of the first vertebra is entirely cartilage. The second vertebra often consists of five and six portions. The spinous processes are all cartilage.

When aneurism of the aorta is very large, the bodies of the vertebræ are occasionally absorbed, but the intervertebral substance remains entire. This is a singular fact, that bone should be sooner absorbed than cartilage. The same phenomenon takes place in caries from other causes. The spinal marrow is always defended in these cases by a deposit of coagulable lymph.

The spine is subject to caries, distortion, and *spina bifida*, called also *hydrorachitis*. The latter consists of a tumour filled with water, which makes its way between the processes of a vertebra, and divides it into two.

THORAX.

The thorax, or chest, forms the upper part of the trunk. It resembles an arched bony cavity, narrow above, broad below, flat anteriorly, hollow posteriorly, and convex laterally. The bones which compose the thorax, are the twelve dorsal vertebræ, already described, the sternum, and twenty-four ribs.

COSTÆ.

The ribs are twenty-four semicircular bones, situated twelve on each side of the chest, and extending obliquely from the dorsal vertebræ round towards the sternum, to which they are connected by strong cartilages. They are distinguished into seven *true ribs* on each side, or those whose cartilaginous extremities are affixed to the sternum; and five *spurious* or *false* on each side, whose extremities do not reach the breast-bone. Each rib may be divided into a *body*, or middle part, two *extremities*, two *margins*, and two *surfaces*.

The *first* rib is far the shortest, and is the most curved; it is broader than the other ribs, and placed in a transverse di-

rection, not oblique. The *second* rib is longer than the first, but shorter than the rest. The other ten differ chiefly in their length, which goes on gradually increasing, from the first, or uppermost, to the seventh, or last true rib, from which they gradually diminish to the twelfth. Their obliquity, in respect to the spine, likewise increases as they descend, as does the distance between the head and angle of each rib, from the first rib to the ninth. The two lowest ribs differ from all the rest, in having no tubercle for the articulation with the transverse processes, and in being much shorter.

Cartilages. The cartilage which unites the anterior extremity of a rib to the sternum, is long, broad, and strong, and in each of the true ribs reaches to the sternum, where its articulation is secured by a capsular ligament. The cartilages of the sixth and seventh ribs being much longer than the rest, are extended upwards to reach the sternum; they are usually united to one. The cartilages of the false ribs are supported in a different manner; they terminate in an acute point before they reach the sternum, the eighth rib being attached by its cartilage to the lower edge of the cartilage of the seventh, or last, of the true ribs; the ninth in the same manner to the eighth, and the tenth to the ninth; the cartilage of each rib being shorter than that of the rib above it. The two last are not fixed at their anterior extremities, but hang loosely, supported by ligamentous fibres.

Eminences. The *great head*, which is connected to the bodies of the dorsal vertebræ; the *neck*; the *lesser head*, which is joined to the transverse processes of the dorsal vertebræ; and the *angle* formed by a considerable curvature in the rib.

Cavities. A longitudinal groove on the inferior and interior surface of each rib, for the intercostal artery, vein, and

nerve. An *oval fossa* at the anterior edge of each rib, for receiving the cartilage of the sternum.

CONNEXION. Anteriorly with the sternum, by synchondrosis, and posteriorly with the bodies and transverse processes of the dorsal vertebræ, by ginglymus.

JOINTS. The joints formed by the connexion of the ribs with the vertebræ and sternum, are of the ginglymus kind, allowing the alternate motions of the ribs, rising and falling, as we draw in and let out our breath. The great head of each rib is hinged in the intervertebral substance, touching two vĕrtebræ; this joint is surrounded by a capsular ligament: the little head which is joined to the transverse process of a vertebra, is also covered by a capsular ligament; and this connexion is strengthened by two transverse ligaments, the one external the other internal. The cartilages of the ribs which join the sternum, are also connected by capsular ligaments, and ligamentous fibres, which expand over the sternum.

USE. To form the thorax, to serve for respiration, to defend the vital viscera, and to give adhesion to muscles.

The ribs, at birth, differ very little in substance and form from those of adults.

STERNUM.

Os pectoris.

The breast-bone is an oblong flat bone, shaped somewhat like a dagger, situated in the anterior part of the thorax, between the true ribs. It is of a very spongy texture, and mostly consists of two, and sometimes of three portions. A sharply-pointed cartilage is attached to the inferior extremity of the sternum, which is named, from its supposed resem-

blance, the *xyphoid*, or *ensiform cartilage*. It is situated at the pit of the stomach.

CAVITIES. The *jugular sinus*, at the superior and inner part. Two *clavicular sinuses*, for the attachment of the clavicles. Seven *costal depressions*, to which the ribs adhere.

CONNEXION. The sternum is connected by arthrodia with the clavicle, and with the seven true ribs by synchondrosis.

USE. To assist in forming the thorax, to give adhesion to the mediastinum, and various muscles, and to serve as a fulcrum for the clavicles to roll on.

The sternum, at birth, consists of cartilage shaped like the adult sternum, with two, three, or four round ossifications in its centre.

When an abscess forms in the anterior space of the mediastinum, a portion of bone is removed, by a trephine, from the sternum, to give an exit to the collected fluid.

LOINS.

The bones of the loins are five lumbar vertebræ, which have already been described.

PELVIS

The pelvis, so named from its resemblance to a bason formerly used by barbers, forms, as it were, the basis of the trunk of the skeleton. It consists of four bones: two *ossa innominata*, the *os sacrum*; and the *os coccygis*, which are situated at the bottom of the trunk, and above the lower extremities. It is within the cavity formed by these bones that the internal organs of generation, the urinary bladder, the rectum, and occasionally part of the small intestines are situated. The pelvis also serves as a firm support to the upper part of the body, and unites the bones of the trunk with those of the lower extremity.

Difference between the male and female pelvis.—There is considerable difference in regard of the capaciousness of the pelvis in the male and female subject. The os sacrum is shorter in the latter, and broader; the iliac portions of the ossa innominata are more expanded, whence it happens, that in women the centre of gravity does not fall so directly on the upper part of the thigh as in men. From these circumstances the brim of the pelvis is nearly of an oval shape, being considerably wider from side to side, than from the symphysis pubis to the os sacrum; whereas in man it is rounder, and every where of less diameter. The inferior opening of the female pelvis, is also proportionably larger in the female subject, the ischia being more separated from each other, and the foramen magnum ischii larger; so that where the ischiatic and pubic portions of the ossa innominata are united, they form a greater circle: the os sacrum is also more hollowed though shorter, and the os coccygis more loosely connected, and therefore capable of a greater degree of motion than in men.

The pelvis is a part very liable to become distorted, especially the female pelvis. The different kinds of distortion are fully treated by writers on midwifery.

OSSA INNOMINATA.

Ossa ilii. Ossa ischii. Ossa pubis. Ossa coxarum. Ossa coxendicis. Ossa anonyma.

These two bones constitute the sides and anterior part of the pelvis, and are extremely irregular in their shape.

Each bone is divided into three portions, viz. ILIUM, the uppermost; ISCHIUM, the lowest; and PUBIS, the anterior. These are very commonly termed os ilium, os ischium, and os pubis.

Eminences. The *crista, or spine, of the ilium*, which forms an arch turned somewhat outwards: it gives origin to the oblique and transverse muscles of the abdomen—at its posterior part are two *spinous processes*, which give adhesion to ligaments—at its anterior part are also two *spinous processes*; the *superior* gives adhesion to the sartorius, tensor vaginæ femoris, and Poupart's ligament; the *inferior anterior spinous process*, about an inch below the former, has, arising from it, the rectus femoris. The *external surface* of the iliac portion is covered by the glutæi muscles; the *internal* by the internal iliac. Upon the internal surface there is a *line* even with the pubis; this is called *linea innominata*, or rim of the pelvis; it divides the cavity of the abdomen from the pelvis. Upon the ischiatic portion, or *ischium*, are the *tuberosity of the ischium*, upon which we sit; the *spinous process of the ischium*, which projects backwards, and gives adhesion to the uppermost sacro-sciatic ligament; the *ramus ischii*, which joins the pubis. Upon the pubic portion, or *pubis*, are the *body*, near the socket; the *angles*, which pass forwards to form the symphysis; and the *ramus*, which proceeds downwards to meet the ascending ramus of the ischium.

Cavities. A *notch* between the anterior spines of the ilium; an *anterior* and *posterior ischiatic notch*; the anterior ischiatic notch, gives passage to the flexor muscles of the thigh, and the anterior crural vessels and nerves: the posterior notch gives exit to the great sciatic nerve, blood-vessels, and pyriform muscle; the *acetabulum*, which receives the head of the os femoris, and the *foramen thyroideum*, or *ovale*.

Connexion. Each os innominatum is connected with its fellow anteriorly by symphysis, with the sacrum posteriorly by strong cartilages and ligaments, and with the head of the thigh-bone by enarthrosis.

USE. To form the pelvis, to retain the gravid uterus in its situation, and to constitute the acetabulum for the thighs.

The os innominatum, at birth, and for a long time after, consists of three distinct bones, united together by cartilage: this probably gave rise to these portions receiving distinct names, as *os ilii*, *os ischii*, and *os pubis*, which in the adult form one bone, without a name, and hence the term os innominatum. The form of the adult pelvis is, nevertheless, perfect in the fœtus.

OS SACRUM.

Os latum. Os clunium.

The os sacrum, which derives its name either from its being offered in sacrifice by the ancients, or from its supporting the organs of generation, which they considered as sacred, is a bone of a triangular shape, bent forwards, and situated at the bottom of the spine, and the posterior part of the pelvis. It is by many described as a bone of the spine; and from the irregularities resembling spinous and transverse processes, and its foramina, it seems to have some just claim to be considered as such

EMINENCES. Two *superior oblique processes*; the *appearances* of the spinous processes; the *appearances* of the oblique and transverse processes; and the *appearances* of the vertebral bodies.

CAVITIES. Four pair of *external*, and four pair of *internal foramina*, for the passage of nerves; a *notch* at the inferior part of the bone, forming a foramen with that of the os coccygis, for the passage of the last spiral nerve, and five *longitudinal middle canals*. The *spinal canal*, of a triangular form, large above, but gradually decreasing in its descent, and terminating in an irregular opening at the back part; this, in the

fresh subject, is covered with ligament; it contains the cauda equina.

CONNEXION. Superiorly with the last lumbar vertebra, laterally with the ossa innominata, and inferiorly with the os coccygis.

USE. To constitute the pelvis, and sustain the spine.

At birth, this bone is shaped like that of an adult, but this shape is given it by cartilage. A number of ossified portions are embedded in the cartilage, and the similarity to vertebræ is very conspicuous.

OS COCCYGIS.

This bone, so called from its resemblance to a cuckoo's bill, consists very frequently of two, three, or four portions, which are triangular or irregularly shaped; they are placed at the extremity of the sacrum; after the age of twenty they unite, forming one bone: this takes place earlier in males than females.

USE. To sustain the rectum, and prevent the rupture of the perinæum, in parturition.

The os coccygis, at birth, consists of several portions of cartilage, and a round ossification is occasionally found in the uppermost.

It sometimes happens, that in labour this bone is separated from the sacrum.

Of the superior Extremities.

The upper extremities hang from the superior part of the sides of the thorax, and are composed of the bones of the shoulder, arm, fore-arm, and hand.

THE SHOULDER.

The shoulder consists of two bones, the clavicle and scapula, which are united together immediately over the top of the os brachii, and form, what is properly termed, the shoulder, *summitas humeri*.

CLAVICULA.

Clavis. Ligula. Furcula. Os jugale.

The clavicle, or collar-bone, is a long roundish bone, shaped like the letter *ſ*, and situated obliquely in the upper and lateral part of the chest.

PROCESSES. Like all long bones, it is distinguished into a *body*, or middle part, and two *extremities*, and these are called *scapular* and *sternal:* the former is slightly convex, and of a triangular figure; the latter broader, thinner, and more flattened. A *tubercle* on the under surface, near the scapular extremity, extends obliquely across the bone, from which a ligament goes across to the coracoid process of the scapula.

CAVITIES. A furrow, or *groove*, of the subclavian vessels on the inferior surface.

CONNEXION. Anteriorly it is articulated to the sternum, and posteriorly to the scapula, by arthrodia.

JOINTS. 1st. The *sternal joint* of the clavicle is the hinge upon which the whole of the upper extremity moves, and the only joint between the arm and chest, and consequently the round end of the clavicle is continually moving in the articular cavity of the sternum. In this joint is a thin interarticular cartilage, fixed around the head of the clavicle; a strong capsular ligament encloses the whole, and is surrounded by numerous ligamentous bands.

2d. The *scapular joint* of the clavicle is formed by the flat end of this bone touching the acromion process of the scapula. An interarticular cartilage is occasionally found, but more generally it is wanting. The joint is surrounded by a capsular ligament, which is strengthened by several ligamentous bands. The motion of this joint is very inconsiderable, and restrained by a firm ligament passing from the clavicle to the coracoid process.

Use. To connect the scapula and humerus to the thorax, to defend the subclavian vessels, and to give origin to muscles. It serves also to regulate the motions of the scapula, by preventing it from being brought too much forward, or carried too far backwards; it is, in fact, the axis on which the whole upper extremity rolls, the scapula serving rather as a socket for the os humeri: hence such animals as make use of their fore-legs, or arms, are furnished with clavicles; as the ape, bear, bat, mouse, opossum, mole, squirrel, and hedgehog.

The clavicle is perfectly formed at birth; indeed it is completely so at the third month after conception.

SCAPULA.

Omoplata. Scoptula.

The scapula, or blade-bone, is of a triangular figure, and is situated in the upper and lateral part of the back. Its anterior and internal surface is irregularly concave, from the impression of muscular and tendinous packets; its posterior and external surface is convex, and divided into two unequal parts by a considerable process or spine.

Eminences. The *spine,* which is in the middle of the external surface, arising small from the posterior edge of the

scapula, and becoming gradually higher and broader, as it approaches the anterior part of the scapula, where it terminates in a broad and flat process, called the *acromion*. The anterior edge of this projection of the spine is concave, and forms a surface of articulation for the clavicle. The triangular shape of this bone gives rise to the denomination of angles and sides; and of the three of the latter, the posterior one, which is turned towards the vertebræ, is termed the *basis*. The *coracoid process*, which stands out opposite to the acromion, and gives attachment to the pectoralis minor, and coraco-brachialis muscles. The borders of the bone are called *costæ*, and the corners *angles*. The circle below the articular cavity is called the *neck*.

CAVITIES. The *articular*, or *glenoid* cavity, which receives the head of the humerus. A *supraspinal* cavity, above the spinous process in which the supraspinatus muscle is lodged. The *infra-spinal* cavity, situated below the spine, is larger than the other, and gives origin to the infra-spinatus muscle; a *semilunar notch* on the superior margin, near its fore part, for the passage of the superior scapulary vessels and nerves.

CONNEXION. The scapula is united with the clavicle by arthrodia, with the ribs and os hyoides by muscle, and with the humerus by arthrodia.

JOINTS. The *shoulder-joint* is one of considerable importance; it is loose, moveable, and very free in its motions. It is formed by the large round head of the humerus, and the shallow articular cavity of the scapula, the sides of which are elevated with cartilage. A capsular ligament, large, wide, and loose, fixed to the neck of the scapula and humerus, surrounds this joint. A considerable quantity of synovia is requisite to lubricate it, and accordingly it is supplied by several bursæ mucosæ opening into it, independent of the natural

secretion of the capsule: of these bursæ we observe one under the tendon of the sub-scapularis, one under the short head of the biceps, one between the coracoid process and the scapula, and a very large one under the acromion process. The motion of the shoulder-joint is restrained, and the joint rendered more secure—by the acromion process, which projects over it:—by the coracoid process below:—by a strong ligament, which extends from the coracoid to the acromion process:—by a ligament extending from the acromion to the capsule of the joint:—and principally by the action of the four muscles which are inserted into the capsular ligament.

The shoulder-joint is more liable to luxation than any other in the body; and this arises from the looseness of its capsular ligament, the shallowness of the glenoid cavity, and great exposure of the upper extremity. The head of the humerus may be dislocated upwards, downwards, or laterally, and the dislocation may be simply the removal of the head of the humerus from the articular cavity, or it may be accompanied by a laceration of the capsule, the head protruding through it; in which case it is very difficult to reduce: it may also be accompanied by a laceration of the long head of the biceps muscle, which passes through the joint, and is attached to the side of the cavity.

Use. To defend the back, and give articulation to the humerus.

The scapula, with respect to shape, is perfect at birth. The acromion and coracoid processes are cartilage.

THE ARM.

The brachium, or arm, consists of one long bone, the os brachii.

OS BRACHII.

Os brachiale. Os humeri.

The bone of the arm occupies the space between the junction of the clavicle with the scapula and the fore-arm. It is a long cylindrical bone, thickest at its ends, and distinguished into body and extremities.

EMINENCES. The *head*, which is rounded on its superior part. The *neck*, which is immediately below the head. The *greater tubercle*, near the neck, on which are three surfaces: —the first of these, which is the smallest and uppermost, serves for the insertion of the supraspinatus muscle;—the second, or middlemost, for the infraspinatus;—and the third, or lowermost, for the insertion of the teres minor. The *lesser tubercle*, which is near the former, and has fixed to it the subscapularis. On the *inferior extremity* are three processes, namely, an *external* and an *internal* condyle; these condyles have a *ridge* continued from them upwards on the sides of the bone: from the external ridge and condyle arise the supinator radii longus, and the extensor muscles of the fore-arm, whilst the internal ridge and condyle give origin to the pronator radii teres, and flexors of the fore-arm; and the *trochlea* of the humerus, upon which the ulna moves.

CAVITIES. A *furrow* between the tubercles, for the long tendon of the biceps: the edges of this groove are continuations of the greater and lesser tubercles, and serve for the attachment of the pectoralis major, latissimus dorsi, and teres major muscles. This furrow in the fresh subject has extending over it a tendinous ligament. A *passage* is observed about the middle of the bone, in the fore and inner part, for the medullary vessels. In the *inferior extremity*;—a *posterior fossa*,

for the anconoid process of the ulna; and an *anterior depression*, for the coronoid process, and end of the radius.

CONNEXION. The humerus is connected with three bones; with the scapula by *arthrodia*, and the cubit and radius by *ginglymus*.

USE. To constitute the arm.

This bone is perfect in its shape at birth, but its extremities are cartilage.

THE FORE-ARM.

The fore-arm is composed of two bones, the *ulna* and *radius*: the first forms the internal and posterior part, and the second the external and anterior part.

ULNA.

Focile majus. Cubitus. Canna major.

This bone is long, and thicker above than below. It is placed in the inside of the fore-arm, from the elbow towards the little finger.

EMINENCES. The *olecranon*, or *anconoid process*, situated posteriorly, and upon which we lean: it has a considerable tuberosity on its back part, for the insertion of the triceps extensor cubiti. The *coronoid process*, which is opposite to the former, has a tubercle that gives adhesion to the brachialis internus muscle, and has externally a semilunar cavity, called the *lesser sigmoid*, for the head of the radius. In the lower extremity are, the *lower head*, the *neck*, and the *styloid process*, which gives a strong adhesion to the ligament that secures the wrist. The body of the ulna is somewhat triangular; its external and internal surfaces are flat, and separated by a sharp

angle or edge, which gives adhesion to a strong ligament that connects it with the radius.

Cavities. The *greater sigmoid cavity*, at the upper end, between the anconoid process and the olecranon. The *lesser sigmoid cavity*, at the side of the coronoid process in which the rounded sides of the head of the radius play; a *foramen*, near its upper end, for the entrance of the nutritious vessels.

Connexion. Superiorly with the trochlea of the humerus by *arthrodia*, inferiorly with the carpus by *arthrodia*, and with the radius by *trochoides*, as in pronation and supination.

Use. To constitute the chief support of the fore-arm.

The ends of the ulna, at birth, are cartilaginous; the body of the bone is very round.

RADIUS.

Manubrium manûs. Focile minus. Canna minor. Additamentum ulnæ.

The radius, the lesser bone of the two, is long and cylindrical, and situated in the external side of the fore-arm, towards the thumb.

Eminences. An *upper head*, which is small, round, and excavated; its sides are also rounded, for immediately behind this upper head is the *neck*, at the bottom of which, anteriorly, is a considerable tuberosity, which gives an insertion to the biceps flexor cubiti, and the capsular ligament. A *ridge*, which is posterior, and extends along the body of the bone for the attachment of the interosseous ligament, which unites it very firmly with the ulna.

The inferior extremity of the radius is much larger than the upper, and is formed into an oblong articulating cavity, called the *glenoid*: this extremity is sometimes termed the *inferior*

head; towards its anterior and convex surface is a remarkable eminence, termed the *styloid process* of the radius.

CAVITY. The *glenoid cavity* at its inferior extremity: it is divided into two by a slight transverse rising. On the anterior and external surface of the lower extremity, are several *grooves*, in which the tendons of some of the muscles of the fore-arm pass. A *fossa*, on the opposite side to the styloid process, which receives the rounded surface of the ulna; a *foramen*, about three or four inches from its upper end, for the passage of the medullary vessels.

JOINTS. The elbow-joint is constituted by three bones; the inferior extremity of the humerus, and the superior extremities of the radius and ulna, which are inclosed in a ligamentous bag, called the capsular ligament, besides which there is a coronary ligament peculiar to the head of the radius, and the joint is strengthened by the two lateral ligaments, a quantity of cellular substance, muscles, and tendons.

Its motions are like unto an hinge, the radius and ulna bending backwards and forwards upon the humerus. The radius has another motion, viz. that of rotation, which it performs upon the ulna.

The joint is supplied with synovia.

USE. To assist in forming the fore-arm, and to serve for flexion, supination, and pronation.

CONNEXION. The radius is connected to the humerus by *ginglymus*, to the cubit by an interosseous ligament and *trochoides*, and to the carpus by *arthrodia*.

Both extremities of this bone are epiphyses at birth.

THE HAND.

The bones of the hand consist of those of the *carpus*, *metacarpus*, and *fingers*.

CARPUS.

The *carpus*, or wrist, is situated between the fore-arm and *metacarpus*. It is composed of eight bones, which lie close to one another in a double row, one of which is superior, the other inferior. In the *superior row*, are (from the thumb to the little finger), *os scaphoides*, or *naviculare; os lunare; os cuneiforme;* and *os orbiculare*, or *sub-rotundum*. In the *lower row* are, *os trapezium; os trapezoides; os magnum*, and *os unciforme*.

All of these bones bear some resemblance to the names given to them; they are extremely difficult, nevertheless, to be known when separated: in general they may be said to have six unequal surfaces each: supposing, therefore, the hand to be laid flat on a table, with the palm downwards, the upper surface of each carpal bone, will be that which is towards the back of the hand; the posterior surface will be that which is nearest to the bones of the fore-arm, and the anterior surface that which is placed towards the fingers; of the two lateral surfaces, the external one will be that which is nearest to the little finger, and the internal one that which is nearest to the thumb. The os scaphoides has an oval cavity at its anterior and inner surface, the os lunare has its outer edge in the form of a crescent; the os cuneiforme has a convexity for the articulation of the os pisiforme; the os pisiforme is the smallest bone of the wrist; the os trapezium has four unequal edges at its posterior surface; the os trapezoides is like the former bone, but smaller; the os magnum is the largest bone of the wrist; the os unciforme has its unciform process.

Connexion. The bones of the carpus are united to those of the fore-arm and metacarpus by arthrodia. A capsular li-

gament surrounds them, and the joint is strengthened by several others, which proceed in all directions.

Use. To assist in forming the hand. See *Fingers*.

The bones of the carpus, at birth, are for the most part cartilage, but a small round ossification is frequently found in many of them.

METACARPUS.

The metacarpus is placed between the *carpus* and fingers. It consists of five long rounded bones; one of the thumb, and four metacarpal bones of the fingers.

The upper extremity of each is termed its *base;* it is irregularly shaped, and somewhat flattened, with a small cavity at its end, and a smooth surface laterally, where it is joined to the next bone. The lower extremity is called the *head;* it is oblong and smooth, and surrounded by a depression, or ring, and there is a small protuberance for the attachment of ligament.

Joints. The wrist may be said to be formed of three sets of articulations, or joints.

The *first* joint is formed by the os scaphoides and lunare, making a ball to be received into the great scaphoid cavity of the radius; by this arrangement the hinge-like motion is allowed.

The *second* joint is formed by the round end of the ula being received into the side excavation of the radius: this permits pronation and supination.

The *third* articulation is made by the metacarpal bones being united to the carpal by a series of joints.

The eight carpal bones which enter into the construction of the wrist, are arranged in two rows, and are connected to each other by capsular and transverse ligaments. A cap-

sular ligament surrounds the first joint, which incloses, besides the end of the radius, the scaphoid and lunated bones; also a moveable cartilage, which is affixed to the end of the ulna. There is a loose capsular ligament, which surrounds the second joint that is inclosed by the larger capsule. The joints are supplied with synovia, to prevent the effects of friction.

Use. To form the middle part of the hand. See *Fingers.*

The extremities of the metacarpal bones, at birth, are *epiphyses.*

DIGITI MANUS.

The fingers are situated at the inferior extremity of the metacarpus, and consist of a thumb and four fingers. The thumb has two bones, and each finger three, which are called *phalanges*, from their being placed in rows. Each bone is broadest at its upper extremity, and formed into a superficial cavity, whose edges are rough for the insertion of ligament: the body, or middle part, is convex externally, and concave before: the lower extremity is rounded, and like a trochlea, or a pulley.

Joints. The joints of the fingers are formed by a round head and hollow socket, secured by a capsular and lateral ligaments, with a fascia from the tendons.

Use. The uses of the hand and fingers, as the instruments of defence and labour, &c. are so well known, that it would seem superfluous to enumerate them; yet, it may be necessary to observe, that one half has a very obscure motion, and serves as the base for the other, which performs the chief of the motions. The carpus being composed of many small bones, yields a little to our force, and accommodates itself to the different motions of the hand. The metacarpus, by being composed of several bones, enables us to form a hollow in the

palm of the hand, whilst the spaces between them serve for the lodgment of muscles. Each finger being composed of three bones, enables us to grasp, and perform several motions which could not be effected were it one bone. Lastly, the general convexity of the bones of the hand strengthens the whole considerably, while the hollow on the inside affords a safe passage to the vessels and nerves.

Of the inferior Extremities.

The bones of the lower extremities consist of those of the *thigh*, *leg*, and *foot*.

THE THIGH.

The thigh has but one bone, which is by far the largest in the body, the *os femoris*, or *femur*.

OS FEMORIS.

The os femoris, so called because it bears the body, is a long cylindrical bone, thickest at its extremities, and situated between the *pelvis* and leg.

Eminences. The *head*, which is received into the acetabulum of the os innominatum, and has a small *dimple* in its middle, for the attachment of the round or restraining ligament: The *neck*, upon which the head stands; it is rough, and gives attachment to the capsular ligament. The *great trochanter*, which is a large unequal eminence below the neck, for the insertion of the glutæi muscles. The *little trochanter*, which receives the psoas and iliacus internus; a *rough eminence*, between the trochanters on the back part of the bone for the

insertion of the capsular ligament, and quadratus femoris, another line on the fore part of the bone, extending between the two trochanters, for the insertion of the capsular ligament. The body of this bone is smooth and convex before, and hollow behind, where there is a rough line, called *linea aspera:* it originates near the trochanters, and extends to the lower extremity, where it divides, and terminates in a protuberance behind each condyle. On the inferior extremity are the *external* and the *internal condyle,* and between them posteriorly a deep *notch,* for the passage of the great artery, vein, and nerve of the leg.

Substance. Compact on the outside, spongy in the extremities, and cancellated internally.

Connexion. The femur is connected to the acetabulum of the os innominatum by enarthrosis, and to the tibia and patella by ginglymus.

Joint. The hip-joint is formed by the acetabulum, the deep hollow cavity of the os innominatum, and the head of the thigh-bone which it receives. The socket is lined by cartilage, which rises on its edge, so as to deepen its cavity; the notch observed on the dry bone, at the inferior part, has a ligament stretched across it; the round ligament keeps the head of the thigh-bone down in its socket, and a very strong capsular ligament surrounds the whole joint. The varied motions of the joint are facilitated by the synovia secreted, particularly by a substance placed within the socket.

Use. To form part of the lower extremity.

The thigh-bone, at birth, is of the same shape as the adult femur. Its head is cartilage, its inferior extremity an *epiphysis.* The ossification of this bone, as well as of the os brachii, begins a month after conception, and has the same shape at four months as at nine.

A longitudinal section of the adult femur, beautifully exhibits the three substances of bones, viz. the *reticu-*

lated, which occupies the medullary cavity; the *spongy*, which forms the extremities; and the *compact*, of which the sides of the body of the bone are formed.

THE LEG.

The leg is that part of the lower extremity between the femur and foot. It consists of three bones; the *tibia*, *fibula*, and *patella*.

TIBIA.

The tibia is a long, thick, triangular, and cylindrical bone, much the thickest at its upper extremity, placed between the *femur* and *tarsus* in the anterior and inside of the leg.

EMINENCES. The *upper head* of the tibia, which is the largest part, formed at the top into two rather concave surfaces, and divided by an irregular protuberance, for its articulation with the condyles of the femur. The *tuberosity* of the tibia, to which the great ligament of the patella is fixed. The body of the tibia is triangular, and smaller than its extremities: of its three surfaces, the external is slightly hollowed by muscles; the internal is broad and flat, and the posterior is the narrowest, and nearly cylindrical. The anterior ridge, or angle of the tibia, is called the *spine*, or *shin*, and the external gives attachment to the interosseous ligament. At the *lower head* of the tibia there is a considerable process, which forms the inner ankle.

CAVITIES. Two *articular sinuses*, in the upper head, for the reception of the condyles of the femur; an *articular cavity*, at the side of the head, for the reception of the fibula. A deep cavity at the lower extremity of the bone, which receives the astragalus of the tarsus; a *foramen* for the entrance of the medullary vessels, situated at the back of the bone, a little above its middle; a *surface* at each extremity on the outer side, for the articulation of the fibula.

Connexion. The tibia is connected to the femur and patella by *ginglymus*, to the fibula by *syneurosis*, and to the astragalus by *arthrodia*.

Use. To support the leg, and serve for the flexion of the lower extremity.

Both extremities of the tibia, in the fœtus, are cartilage; but perfectly shaped like those of the adult. The body of the bone is more rounded.

This bone is more frequently attacked with venereal nodes than any other, and particularly the anterior part.

FIBULA.

The *fibula* is a longitudinal bone, situated in the outer part of the leg, by the side of the tibia.

Eminences. The *head* of the fibula, at the upper part; which is rough and protuberant, and gives attachment externally to the biceps flexor cruris, and part of the gastrocnemius internus. The body of the fibula is somewhat triangular, and appears as if it were twisted; it is covered by muscles, and gives attachment to the interosseous ligament; it has a *foramen* at its posterior part, for the entrance of medullary vessels. At its lower extremity the bone forms a considerable process, the *malleolus externus*, or outer ankle.

Connexion. It is connected to the tibia by an interosseous ligament, and to the astragalus by arthrodia.

Use. To form a fulcrum for the tibia, and assist in forming the leg.

The fibula, at birth, is perfectly formed, as to shape; its extremities are cartilaginous.

PATELLA.

Rotula.

The *patella*, or knee-pan, is a small, triangular, or heart-shaped spongy bone, situated between the inferior extremity of the thigh-bone, an the upper part of the tibia.

It is thickest at its middle, and gradually becomes thinne until it forms its edge: anteriorly it is convex and rough, for the insertion of muscles and ligament: posteriorly it is smooth, and divided into two surfaces by a longitudinal line.

CONNEXION. It is connected to the condyles of the femur by *ginglymus*, and with the tibia by *syneurosis*.

The patella covers the anterior part of the knee-joint, and is kept in this situation by a strong ligament which every where surrounds it, and adheres both to the tibia and os femoris, forming a part of the capsule. It is likewise firmly connected with the tibia, by means of a streng tendinous ligament, an inch in breadth, and upwards of two inches in length, which adheres to the lower part of the patella, and to the tuberosity at the upper part of the tibia. On account of this connexion it is very properly considered as an appendage to the tibia, w.ich it follows in all its motions, so as to be with it what the olecranon is to the ulna. There is this difference, however, that the olecranon is a fixed process, whereas the patella is moveable, being capable of sliding from above downwards, and from below upwards; which motion is essential to the rotation of the leg.

JOINT. The knee-joint is formed by the condyles of the femur; the patella, and the tuberosities of the tibia, united by the capsular ligament, the crucial ligaments, the lateral ligaments, and the ligaments of the patella. Two semilunar cartilages are placed on the tibia, forming a more perfect hollow for the reception of the condyles of the femur. The joint is

plentifully supplied with synovia, and surrounded with very large bursæ mucosæ.

The strength of the joint is dependant more on its numerous ligaments than the conformation of the bones. Its motions are flexion, extension, and a slight degree of rotation.

USE. To strengthen the knee-joint, and to serve as a common pulley for the extensor muscles of the tibia.

The knee-pan is always cartilaginous at birth. Ossification begins at different periods after birth, which depends upon the activity of the system. At first the artery is seen to deposit a few specks of bony matter. It next appears as if the vessel were itself converted into bone; a complete ring of bone is then observed; and at length the middle of this annulus is filled with bone, which goes on increasing until the whole is become bone. This process in the patella forms a most beautiful series of preparations, especially if injected. For this purpose, the knee-pans should be collected at all periods before they are completely ossified; dried, and put into spirit of turpentine.

The patella is very frequently fractured. It is never united by callus, which would subject it to be more frequently broken; but an union is effected between the divided portions by means of ligament.

FOOT.

The bones of the foot, like those of the hand, are distinguished into three orders; those of the tarsus, metatarsus, and toes.

TARSUS.

The tarsus, like the carpus, consists of a number of small bones. They are seven in number, and are placed between the leg and metatarsus. Viewed altogether, the superior part of the tarsus appears convex and headed, its hinder part forming the heel, its anterior part the back of the foot. Below it

is concave, and affords a secure passage for the blood-vessels and nerves.

Bones. The seven bones of the tarsus are disposed into two rows. In the *first row* are:—1st, the *astragalus*, or uppermost bone. It has a large smooth convex head, flattened at its sides, and surrounded by a depression or groove, by which it is articulated to the tibia and fibula: anteriorly it has a surface of articulation with the os naviculare, and inferiorly are two surfaces of articulation, separated by a depression for its connexion with the os calcis.

The *os calcis*, or *calcaneum*, is the largest bone of the tarsus, and of a very irregular shape. It is long, and somewhat flattened at its sides, and forms the projection of the heel, called its tuberosity, into which the tendo Achillis is fixed. On its upper surface is an irregular prominence, with a narrow groove for its articulation with the astragalus. Anteriorly it has a surface of articulation with the os cuboides. On its under surface, which is flattened and concave, are two tubercles that give origin to muscles. There is a groove on its external surface, in which the tendon of the peroneus longus passes.

In the *second row* are:—1st, the *os naviculare*, or *scaphoides*, situated between the astragalus and ossa cuneiformia at the inside of the foot. Its anterior surface is convex, and has three articulatory surfaces which answer to the cuneiform bones: and there is a tuberosity on its inside, into which the tendon of the tibialis posticus is inserted:—2. The *os cuboides*, which is the outermost bone, is of an irregular shape, and has a protuberance on its under surface, between which and the metatarsal bone, the tendon of the peroneus longus passes:—the remaining three bones are called cuneiform, and distinguished into the *os cuneiforme externum*, *medium*, and *internum*.

Eminences. The head of the astragalus, and the tuberosity of the heel.

CONNEXION. The connexion of the bones of the tarsus is with the tibia and fibula by *arthrodia*, and with the metatarsal bones, and also with one another by *amphiarthrosis*.

JOINTS. The ancle-joint is composed of three bones, viz. the lower end of the fibula, the lower end of the tibia, and the astragalus. The astragalus with its rounded surface, receives the end of the tibia, a part of which descends some way down on the side of the astragalus, forming the inner ancle; on the opposte side the fibula descends, forming the outer ancle, and by the end of the fibula being confined to that of the tibia by means of ligaments, a hollow is formed for the astragalus.

This joint is surrounded by a capsular ligament, and is further stregthened by tendons and fascia; besides the deltoid ligament, which goes from the inner ancle to the astragalus, the anterior, and perpendicular fibular ligaments, and some others variously placed. The tarsal bones are united to each other by a complex number of ligaments. The joint admits of varied motion, and is supplied with synovia, and surrounding bursæ mucosæ.

USE. To form the basis of the foot, and to serve for its motion.

The *os calcis*, and the *astragalus*, are become bone at birth; but the other bones are cartilaginous.

METATARSUS.

The metatarsus is situated between the tarsus and toes, and is composed of five longitudinal bones, which form the back and sole of the foot. These agree in their general character with those of the metacarpus, but are longer and thicker: the basis, or posterior extremity of each, is thicker than the other extremity, which is rounded. Their bodies are somewhat triangular.

DIGITI PEDIS.

The great toe is composed of two, and the other toes of three small bones, called *phalanges*. The general account of fingers will apply to the bones of the toes.

JOINTS. The joints of the toes are something like those of ie fingers, they have their capsular ligaments.

OSSA SESAMOIDEA.

The sesamoid bones are of the size of a small pea, and si- ated occasionally about the joints of the thumb and great e.

COLOUR OF BONES.

The natural colour of recent bones is various: in the fœtus ey are red; blueish in youth; and white in old age.

By feeding animals, as pigs, pigeons, rabbits, &c. with madder, the bones become of a beautiful red colour.

VESSELS AND NERVES OF BONES.

Bones have always their arteries arising from contiguous anks, and their veins return the blood into those in the ighbourhood. In the larger and cylindrical bones there is canal for these vessels. The nerves pass in, along with the teries, from contiguous branches. The absorbents come out th the veins.

CONNEXION OF BONES.

BONES are connected with one another, so as to admit of motion, and this kind of union is termed *diarthrosis;* or so as to admit of no motion, which is termed *synarthrosis;* and when connected with one another by an intervening substance, the union is termed *symphysis.* Diarthrosis, synarthrosis, and symphysis, are to be considered as the genera only of articulations, each genus comprehending several species, which are arranged as follows :—

Genera.	*Species.*
DIARTHROSIS.	ENARTHROSIS, when the round head of one bone is received into the deep cavity of another, so as to admit of motion in every direction; as the head of the os femoris with the acetabulum of the os innominatum.
	ARTHRODIA, when the round head of a bone is received into a superficial cavity of another, so as to admit of motion in every direction; as the head of the humerus with the glenoid cavity of the scapula.
	GINGLYMUS, when the motion is only flexion and extension: thus the tibia is articulated with the os femoris; and the cubit and radius with the os humeri.
	TROCHOIDES, when one bone rotates upon another; as the first cervical vertebra upon the odontoid process of the second, and the radius upon the ulna or cubit.
	AMPHIARTHROSIS, when there is motion, but that very obscure; as the motion of the metacarpal and metatarsal bones.

Genera.	Species.
SYNARTHROSIS.	SUTURE, when the union is by means of dentiform margins: as in the bones of the cranium; hence the sagittal, lambdoidal, or occipital, and coronal sutures. HARMONY, when the connexion is by means of rough margins, not dentiform; as in the bones of the face. GOMPHOSIS, when one bone is fixed within another, like a nail in a board; as the teeth in the alveoli of the jaws. SCHINDELYSIS, when one bone is furrowed into another, as the bones of the septum narium.
SYMPHYSIS.	SYNCHONDROSIS, when a bone is united with another by means of an intervening cartilage; as the vertebræ and bones of the pubis. SYSSARCOSIS, when a bone is connected with another by means of an intervening muscle; as the os hyoides with the sternum. SYNEUROSIS, when a bone is united to another by an intervening membrane; as the bones of the head of the fœtus. SYNDESMOSIS, when a bone is connected to another by means of an intervening ligament; as the radius with the ulna, &c. SYNOSTOSIS, when two bones, originally separated, are united to one another by bony matter, as the occipital bone with the sphænoid.

OSTEOGENY;

OR,

DOCTRINE OF THE FORMATION AND GROV OF BONES.

In what manner bones are first formed, has long been a ter of dispute. Duhamel was of opinion that they formed from layers of the periosteum, which gradually fied. This plausible doctrine, taught for many years, wa length opposed by Detleff, who, under the direction of ler, made many experiments to prove its fallacy. He wa opinion, from repeated observations, that the first rudim of bone are a glutinous substance, which quickly assumes consistence of cartilage, and then proceeds more slowly to firmness of bone. This hypothesis is now abandoned. dern physiologists are of opinion, that *ossification* is a spec action of small arteries, by which ossific matter is separa from the blood, and deposited where it is required.

Whilst ossification is going on, very little phospha lime (a component of ossific matter) can be detec in the urine, to be compared to what exists at o times. In rickets the urine is overcharged with p phat of lime.

The first thing observable in the embryo, where bone i be formed, is a transparent *jelly*, which becomes gradu firmer, and is formed into *cartilage*. The cartilage gradu increases to a certain size, and, when the process of ossi tion commences, vanishes as it advances. Cartilages, prev to the ossification, are solid, and without any cavity; when the ossific action of the arteries is about to comme the absorbents become very active, and form a *small ca*

in which the bony matter is deposited; bone continues to be separated, and the absorbents model the mass into its required shape.

The process of ossification is extremely rapid in utero; it advances slowly after birth, and is not completed in the human body till about the twentieth year.

Ossification in the flat bones, as those of the skull, always l gins from *central points,* and the radiated fibres meet the radii of other ossifying points, or edges of the adjoining bone. 'n these bones the ossific matter is deposited between mem- ines; whilst in some flat bones, as the ossa ilia, the deposi- ion takes place in cartilage.

In long bones, as those of the arm and leg, the clavicle, metacarpal, and metatarsal bones, a *central ring* is formed in the body of the bone, the head and extremities being cartilage, in the centre of which ossification afterwards begins. The central ring of the body shoots its bony fibres towards the head and extremities, which extend towards the body of the bone. The head and extremities at length come so close to the body as to be merely separated by a cartilage, which becomes gradually thinner until the twentieth year.

Thick and round bones, as those of the tarsus, carpus, sternum, and patella, are at first all cartilage; ossification begins in the centre of each.

At birth, the *bones of the fœtus* are very imperfect. The extremities and processes of almost all the long bones are connected to the body of the bone by cartilage. These portions ot bone are called *epiphyses.* The cranium has no sutures; its bones are connected together by a firm and almost cartilaginous membrane. On the anterior part of the cranium, between the parietal bones and the frontal, is a considerable membranous space, called the *anterior fontanel,* and a similar,

but smaller one, between the parietal bones and the occipital, termed the *posterior fontanel.* The frontal bone consists of two bones, and the occipital of four. The teeth are partly formed, especially the enamel, and are placed in a double series. The external auditory foramen is surrounded by a *bony circle,* in which there is a groove for the attachment of the membrana tympani:—this circle gradually elongates into the meatus auditorius. The articular cavities of all the bones are much more shallow than in the adult. The os innominata consists of three bones, the ilium, ischium, and pubis, which are connected together by very firm cartilage. The bodies of the vertebræ and its processes, are united by cartilages.

DISEASED APPEARANCES OF BONES.

The bones, like other parts of the body, are subject to diseases in which no alteration of structure is perceived. Those which the anatomist occasionally observes are, inflammation, suppuration, necrosis, morbid thickness, morbid thinness, mollities, hyperostosis, rachitis, exostosis, absorption, præternatural joints, diastasis, anchylosis, fracture, fissure, tophus, sarcostosis, caries, spina ventosa, and fragility.

Inflammation. Bones are supplied with arteries, veins, absorbents, and nerves; and when inflammation takes place, there is a greater number of vessels perceived carrying red blood than in a healthy state;—this diseased appearance is common in the bone lying immediately under old ulcers. When inflammation attacks the internal structure of bones, and produces suppuration, it forms the spina ventosa.

Suppuration. Abscesses in bones are not very frequent. They are often attacked with caries, and form the spina ventosa: but it sometimes happens that the absorbents remove a

considerable portion of bone while pus is deposited; and, in these cases, the abscess is lined by a thick coat of coagulable lymph:—this occurs most frequently in scrophulous caries of the vertebræ.

Necrosis. This disease consists in a considerable portion of bone losing its vitality, and the neighbouring vessels taking on the ossific action, and depositing a considerable quantity of new bone to supply its place. In most of these cases the dead bone is not protruded until a new one is formed. Necrosis happens most frequently in the cylindrical bones, as the humerus, tibia, femur, &c.

Morbid thickness. Bones are often observed remarkably thick, especially those of the calvaria; it sometimes is the effect of rheumatic inflammation. The body of a bone is occasionally found considerably thickened from a deposition of bony laminæ over the original bone: in these cases the bone is considerably heavier than in a healthy state.

Morbid thinness. This affection of the bones is mostly observed in those of the head, from rickets and hydrocephalus.

Mollities. Malacosteon. In mollities ossium there is a want of the due proportion of bony particles, and the bone which is formed is of a morbid nature, so that the whole may be bent in any direction. This disease often exists to so great a degree, that the bone may be cut with a knife.

Hyperostosis. When the whole of a bone is swelled, or the extremity of a bone, the disease is called hyperostosis. Anatomists frequently have occasion to examine this disease in the extremity of a bone; as in white swellings. A considerable deposition of a morbid fluid is observed in the cells of the bone, which is remarkably spongy.

Rachitis. This is merely a degree of mollities in which the

bones swell at their extremities, and, unable to support the weight of the body, often become deformed.

Exostosis. This disease consists in a bony excrescence arising from a bone. The fangs of the teeth are very subject to exostoses. When a bone has been fractured and there is a luxuriance of callus, it forms an exostosis. The structure of these unnatural formations of bone, is similar to that of compact healthy bone. Exostoses occasionally form to a considerable size, from the action of venereal and scrophulous virus, and then the diseased bone is very spongy.

Absorption of bone. In the honeycomb caries of the cranium, which is the effect of the venereal disease, portions of bone are removed here and there, so as to give somewhat the appearance of a honeycomb. During life, small ulcers, or a spongy flesh, occupy these cavities. Bone is likewise absorbed from pressure, as some of the ribs and of the dorsal vertebræ from aneurism.

Præternatural joints. When the patella and the collar-bone of old people, and occasionally the long cylindrical bones, are broken, the broken ends are united by ligament, and a new joint is sometimes formed, surrounded by a capsular ligament.

Diastasis. Bones, which in a healthy state are united by a firm and immoveable connexion, occasionally are separated by disease to a considerable distance from each other: thus diastasis of the bones of the calvaria from hydrocephalus, and diastasis of the bones of the pelvis from enlarged viscera.

Anchylosis. Bones, which in a natural state are united with each other, in such a way as to admit of considerable motion, are often found united to each other by a mass of bone interposing. Sections of such anchylosed joints, exhibit the ends of the bones sometimes in a healthy state, and a considerable quantity of spongy bone going across from each extremity.

There is not unfrequently a morbid enlargement of the extremities of such bones.

Fracture. The ends of fractured bones have been examined by anatomists at various periods after the accident, from almost the moment after to the time of the complete formation of callus. A coagulum of blood is first deposited; in a short time after, vessels are seen shooting into this coagulum, from whose extremities bone is secreted, and the coagulum is then absorbed. Callus becomes bone of a more or less compact structure. When a cylindrical bone is fractured, the callus between the broken ends of the bone is a solid mass, and has no medullary canal. A fractured tooth never unites again.

Fissure. The bones of the skull are often found cracked, or not completely divided. A fissure is observed in one table, whilst the other remains whole.

Tophus. A portion of a bone is occasionally observed elevated above the natural surface. When examined, it is found to arise from a diseased fluid deposited between the external lamellæ of the bone, raising these lamellæ so as to form a knot or tumour. Such diseased appearances are common to the tibia, and mostly arise from the action of the venereal virus.

Sarcostosis. This disease consists in a loss of a portion of a bone, and in its place a spongy, fleshy excrescence is formed. It most frequently is observed in the cranium and tibia, and generally becomes cancerous, producing death.

Caries. When a portion of a bone is deprived of its periosteum from disease, so that a gritty sensation may be felt by touching it with a probe, it is said to be carious. The whole carious portion is often separated altogether, when the bone is said to exfoliate; but it frequently happens, that in caries of the spongy bones, the bone crumbles insensibly away, until

the whole is lost: this happens to the sternum, carpal, tarsal bones, and vertebræ; whilst the long cylindrical bones, the calvaria, ribs, &c. mostly, when carious, exfoliate.

Spina ventosa. Caries of the internal structure of bones, often comes under the examination of the anatomist. A spina ventosa, or suppuration in the medullary canal of the femur, has given rise to a tumour the size of a human head. When the carpal and tarsal bones are examined with this disease, their internal structure is found carious, and crumbling away.

Fragility. When there are more earthy particles deposited than in a healthy state, the bones are extremely brittle. This is observed in the bones of very old people; such bones being commonly fractured by a force which, if applied to a young and healthy bone, would scarcely affect it.

Bone converted into chalk. The extremities of the metatarsal bones, and of the phalanges of some gouty people, are occasionally found converted into an earthy mass, of a chalky whiteness. This substance often fills the joint, so as to anchylose it.

CARTILAGES.

Definition. White, elastic, glistening substances, growing to the bones.

Division. Into *obducent*, which cover the articulatory surfaces of bones; *interarticular*, which are not accreted to the bones, but adhere to the capsular ligament, and lie between the articulating extremities, as in the knee-joint, &c.; and *uniting* cartilages, which unite bones firmly together, as the symphysis pubis, bodies of the vertebræ, &c.

Use. To lubricate the articulation of the cartilages; to connect some bones by an immoveable connexion; and to facilitate the motion of some articulations.

They are covered by a membrane, called *perichondrium*, which serves the same purposes as periosteum does to bone.

The diseases of cartilages are little if at all understood.

PERIOSTEUM.

A membrane which invests the external surface of all the bones except the crowns of the teeth.

NAMES. *Pericranium*, on the cranium; *periorbita*, on the orbits; *perichondrium*, when it covers cartilages; and *peridesmium*, when it covers ligaments.

SUBSTANCE. Fibrous, furnished with arteries, veins, nerves, and absorbent vessels.

CONNEXION. The periosteum coheres very firmly by means of vessels with the substance of bones, and its external surface is connected with cellular membrane, muscles, and ligaments.

USE. To distribute the vessels on the external and internal surfaces of bones, to which it also gives smoothness for the easier motion of muscles on its surface.

DISEASED APPEARANCES. *Inflammation*, in which there is a greater quantity of red vessels than in health, and a general thickening. *Gummi*, or an elevation of the periosteum, from a spongy thickening.

Many have contended for the insensibility of the periosteum; in a diseased state, however, it is highly sensible, and often gives excruciating pain.

In some birds the periosteum is black, and green in some fish.

MEMBRANA MEDULLARIS.

This has improperly been termed periosteum internum, from its forming an internal lining to the bones. It forms the little bags which contain the marrow, lines the cancelli, and affords a surface for the dispersion of the secretory vessels of the marrow.

SYNDESMOLOGY;

OR,

DOCTRINE OF THE LIGAMENTS.

Ligaments are elastic and strong membranes connecting the extremities of the moveable bones.

Division. Into *capsular*, which surround joints like a bag, and *connecting* ligaments.

Use. The capsular ligaments connect the extremities of the moveable bones, and prevent the efflux of synovia; the external and internal connecting ligaments strengthen the extremities of the moveable bones.

Ligaments of the lower jaw.—The condyles of the lower jaw are connected with the articular sinuses of the temporal bone by the *capsular ligament*, besides which there is a *lateral ligament*, which extends from the lower edge of the posterior maxillary foramen, on each side, to be fixed in the petrous portion of the temporal bone, before the vaginal eminence of the styloid process. An interarticular cartilage, placed on the condyles of the jaw, is enclosed by the capsular ligament.

Occipital bone, and vertebræ of the neck.—The condyles of the occipital bone are united with the articular depressions of

the first vertebra by the *capsular ligament*, surrounding its condyles; a ligamentous membrane which goes from the anterior and posterior arch of the atlas to the occipital bone; a ligament passing from the odontoid process to the occipital bone, called the *perpendicular ligament*; the lateral ligaments, which arise from each side of the dentatus, and are inserted into the occiput before the condyles; the *circular ligament*, which arises from the edge of the spinal hole, and is inserted into the edge of the foramen magnum, and the ligamentum nuchæ.

Vertebræ.---The vertebræ are connected together by means of their bodies and oblique processes; the bodies, by a soft cartilaginous substance, and the processes by ligaments, viz.

1st. The *transverse ligament* of the first vertebra, which passes behind the odontoid process of the second vertebra, and thus retains it in its proper situation.

When this transverse ligament is ruptured or absorbed by pressure, the odontoid process presses on the medulla spinalis. In the first case, death is the immediate consequence; in the latter, a paralysis gradually takes place; and if the bones do not anchylose, it at length terminates fatally.

2d. The *interspinous*, which passes between the spinous processes.

3d. The *intertransverse*, which proceed from one transverse process to another.

4th. An *external* and *internal ligament* common to all the vertebræ, extending in a longitudinal direction from the forepart of the body of the second vertebra of the neck over all the other vertebræ, and becoming broader as it descends towards the os sacrum, where it becomes thinner, and gradually disappears. This external longitudinal ligament is strength-

ened by the other shorter ligamentous fibres, or interverte-bral ligaments, which pass between the processes from one vertebra to another throughout the whole spine. The internal ligament, the fibres of which, like the external one, are spread in a longitudinal direction, is extended over the back part of the bodies of the vertebræ, where they assist in forming the cavity of the spine: it reaches from the foramen magnum occipitale to the os sacrum.

5th. Between the crura of the spinous processes is a *yellowish ligament*, which possesses great elasticity.

This elastic ligament is of considerable importance, and very conspicuous in birds of long necks, as the swan and ostrich, in which, by its elasticity, a considerable quantity of muscles is thereby rendered unnecessary.

6th. The *capsular ligaments* of the oblique processes; and the transverse ligament, which unites the last vertebra of the loins with the os sacrum, which is strong, and passes from the extremity and lower edge of the last lumbar vertebra to the posterior and internal surface of the spine of the ilium.

Ribs.----The posterior extremity of the ribs is united with the vertebræ; the anterior with the sternum. The ligaments of the posterior extremity are, the *capsular ligaments* of the greater and lesser heads; the *internal* and *external ligaments* of the neck of the ribs; the *external transverse* ligament, which arises from the transverse process, and is inserted into the angle of each rib; the *internal transverse* ligament, which arises from the body of each vertebra, and is inserted anteriorly a little beyond the head of each rib; the internal transverse ligaments, which arise from the inferior surface of the transverse processes, and are fixed to the upper margins at the necks of the nearest ribs; and a ligament *peculiar* to the last rib. The ligaments of the anterior extre-

mity are, the *capsular* ligaments of the cartilages of the true ribs, and the ligaments of the ribs *inter se.*

Sternum.---The ligaments connecting the three portions of the sternum to the ribs are, the *membrana propria* of the sternum; and the ligaments of the ensiform cartilage.

Pelvis.---The ligaments which connect the ossa innominata with the os sacrum are, two *sacro-ischiatic ligaments*, placed towards the posterior and inferior part of the pelvis: of these ligaments one is considerably larger than the other. The greater is attached to the posterior edge of the sacrum, to the tuberosity of the ilium, and the upper part of the os coccygis, from whence it passes to be inserted into the inner surface of the tuberosity of the ischium. At its upper part it is of considerable breadth, after which it becomes narrower, but expands again before it is inserted into the ischium, and extending along its tuberosity to the descending ramus of the pubis, it there terminates in a fine point, and forms a kind of falx, one end of which is loose, while the other is fixed in the bone. The lesser sacro-ischiatic ligament is sometimes thicker than the former, and is placed obliquely before it. It extends from the transverse processes of the sacrum, and the tuberosity of the ilium, on each side to the spine of the ischium. These two ligaments not only serve to strengthen the articulation of the ossa innominata with the sacrum, but to support the viscera contained in the pelvis, the back and lower part of which is closed by these ligaments. The posterior and external surface of the greater ligament gives attachment also to portions of the gluteus maximus and gemini muscles. The *ligamentum obturans* of the *foramen ovale*, which arises from the sides of this foramen, and gives adhesion to the obturator externus and obturator internus muscles. The *ligamentum Poupartii*, or *inguinale*, which passes from the

anterior superior spinous process of the ilium to the horizontal ramus of the pubis. It has an aperture at its upper part, for the passage of the obturator artery, &c. The *transverse* ligaments, which go from the transverse process of the fourth and fifth lumbar vertebræ, and are inserted into the posterior superior spinous process of the ilium. The *annular* ligament, which surrounds the articulation of the ossa pubis. The *ligamenta vaga*, which are small ligaments that pass from the ilium to the sacrum anteriorly, and the *lacertus ligamentosus*, which passes anteriorly from the body of the fourth lumbar vertebra, along the ridge of the os innominatum to the pubis.

Os coccygis.—The basis of the os coccygis is connected to the apex of the os sacrum by the *capsular* and *longitudinal* ligaments.

Clavicle.—The anterior extremity is connected with the sternum and first rib; and the posterior extremity with the acromion of the scapula, by the *interclavicular*, the *capsular* ligament, the *ligamentum rhomboideum*; and in the posterior extremity, the *capsular* ligament.

Scapula.—The proper ligament which connects the scapula with the posterior extremity of the clavicle is, the *conoid*, and the trapezoid. It extends from the whole external side of the coracoid process, and stretches across to the acromion scapulæ, becoming narrower as it approaches it; so as to be somewhat of a triangular shape. This ligament, and the coracoid process, and acromion, are evidently intended for the protection of the shoulder-joint, and to prevent a luxation upwards.

Humerus.—The head of the humerus is connected with the glenoid cavity of the scapula by the *capsular* ligament, which surrounds the neck of the scapula and os humeri, and is pene-

trated by the tendon of the biceps flexor cubiti. At the lower extremity of the os brachii are two intermuscular ligaments, which arise from the ridges going to the condyles.

Articulation of the cubit.—The elbow-joint is formed by the inferior extremity of the humerus, and superior extremities of the ulna and radius. The ligaments connecting these bones are, the *capsular*, the *brachio-cubital*, and the *brachio-radial* ligaments. The capsular ligament is attached to the anterior and posterior surfaces of the lower extremity of the os humeri, to the upper edges and sides of the cavities, above the condyles, and also to some part of the condyles; from thence it is spread over the ulna to the edges of the greater sigmoid cavity, so as to include in it the end of the olecranon and of the coronoid process: it is likewise fixed around the neck of the radius, so as to include the neck of that bone. The *brachio-radial* and *brachio-cubital* ligaments descend laterally from the lowest part of each condyle of the os brachii, and their fibres spread wide as they descend, so as to form some resemblance to a goose's foot. The brachio-cubital ligament is situated internally, and terminates in the coronoid process of the ulna, whilst the other, which is external, is lost in the radius.

Radius.—The radius is affixed to the humerus, cubit, and carpus, by peculiar ligaments. Its head is bound in the lateral sigmoid cavity of the ulna by a *circular* ligament, which is attached at the two extremities of the cavity, and from thence surrounds the head of the radius: a ligament extends along its internal ridge, and is implanted into the opposite ridge of the ulna. This is called the *interosseous* ligament. Besides these, there are several other ligamentous fibres in the superior and inferior part of the radius.

The bones of the carpus are articulated with those of the

fore-arm, with the metacarpus, and with each other. The articulation with the fore-arm is formed by the upper surfaces of the os scaphoides, lunare, and cuneiforme, with the lower end of the radius ; a strong capsular ligament surrounds them, strengthened by the two lateral ligaments, one of which, or the external, extends from the styloid process of the radius to the os naviculare ; while the other, or internal, is attached to the styloid process of the ulna, and to the os cuneiforme. The connexion of the second row with the upper extremities of the metacarpal bones is surrounded by a capsular ligament fastened round the neck of each metacarpal bone, and strengthened by several short and strong ligaments. All the metacarpal bones are firmly connected to each other by a number of short and very strong ligaments, which extend from one bone to another, and are farther strengthened by two considerable ligamentous expansions, which are called the *external* and *internal annular ligaments.* The first of these is stretched obliquely over the convex surface of the carpus from the os pisiforme to the styloid process of the radius : it is an inch and a half in breadth, and serves to bind down the extensor tendons of the wrist and fingers, by attaching itself to the little protuberances that separate them. The internal annular ligament is spread transversely at the inside of the carpus, and is attached on one side to part of the os naviculare and trapezium, and on the other to the os pisiforme ; serving to bind down the flexor tendons of the wrist and fingers, and by this mechanism facilitating the action of their muscles. An *interarticular cartilage* is placed between the head of the ulna and os cuneiforme.

Fingers.—The fingers and phalanges are connected together, and with the metacarpus, by strong capsular ligaments.

Articulation of the femur.—The head of the os femoris is

strongly annexed to the acetabulum of the os innominatum, by two very strong ligaments---the *capsular* ligament, and *ligamentum teres*, or restraining ligament. A *cartilaginous ligament* surrounds the brim of the acetabulum, and a ligament is stretched across the notch at the inferior part of the acetabulum, leaving an opening behind it for the entrance of vessels to the joint.

The *posterior* ligament of Winslow, which arises from the upper and back part of the external condyle of the os femoris, and descends obliquely over the capsular ligament, to be fixed to the tibia: this is often wanting; then a membrane supplies its place.

Articulation of the knee.---The knee-joint is formed by the condyles of the os femoris, head of the tibia, and patella. The ligaments are, the *capsular*, the *poplitial* ligament, which arises from the external condyle of the femur, and, passing on the posterior part of the capsular, is expanded upon the internal side of the joint, the external and the internal *lateral* ligaments, which arise from the tuberosities at the sides of the condyles, and are extended down to the tibia; two *crucial* ligaments, which arise from each condyle posteriorly: one of these passes from the right to the left, and the other from the left to the right, so that they intersect each other. The lateral ligaments prevent the motion of the leg upon the thigh to the right or left; and the crucial ligaments, which are also attached to the tibia, prevent the latter from being brought forwards. Besides these, the patella has the *anterior* ligament, which arises from the inferior point of the patella, and is inserted into the anterior tuberosity of the tibia, and the *alar* ligaments, which proceed from the inner side of the capsular ligament, and are inserted into the sides of the patella. There are two *inter-articular*,

or *semilunar cartilages*, placed at the top of the tibia: the cornua, or extremities, are fixed, by ligaments, to the protuberance of the tibia, and the anterior cornua are joined to each other by a *transverse* ligament.

Fibula.----The fibula is connected with the tibia by means of the *capsular* ligament of the superior extremity, the *interosseous* ligament, and by strong ligaments of the tarsus.

Articulation of the tarsus.----The inferior extremity of the tibia and fibula forms the cavity into which the astragalus of the tarsus is received. This articulation is effected by the *anterior*, *middle*, and *posterior* ligaments of the fibula, the *ligamentum tibiæ*, *deltoides*, the *capsular* ligament, and ligaments *proper* to the bones of the tarsus.

Metatarsus.----The bones of the metatarsus are connected in part together, and in part with the tarsus, by means of the *capsular* ligament, the *articular* ligaments, the *transverse* ligaments in the back and sole of the foot, and the *interosseous* ligaments of the metatarsus.

Toes.----The phalanges of the toes are united partly together, and partly with the metatarsus, by the *capsular* and *lateral* ligaments.

The ligaments which restrain the muscles of the foot in their proper places, are found partly in the back and partly in the sole of the foot. They are the *vaginal* ligament of the tibia, the *transverse* or *crucial* ligaments of the tarsus, the ligaments of the tendons of the peronei muscles, the *laciniated* ligament, the *vaginal* ligament of the extensor muscle and flexor pollicis, the *vaginal* ligaments of the flexor tendons, the *accessory* ligaments of the flexor tendons, and the transverse ligaments of the extensor tendons.

DISEASED APPEARANCES OF LIGAMENTS.

The diseases of the ligaments are very few; they are occasionally found carrying more red vessels than in an healthy state, and often thickened, lacerated, and gangrenous.

MYOLOGY;

OR,

DOCTRINE OF THE MUSCLES.

A MUSCLE is a fibrous body, divided into *head*, *belly*, and *tail*.

ADHESION. The head and tail are firmly attached to the bones; the place of attachment of the former is called its *origin*; it is usually that part nearest the trunk of the body: the latter is termed the *insertion*, which is more remote from the trunk of the body, and is implanted into the part to be moved. The body adheres laxly to other parts, by means of the cellular membrane, in order that it may swell when the muscle acts.

SUBSTANCE. Fleshy in the belly, tendinous in the extremities. The former is composed of fleshy fibres, which are irritable and sensible; the latter of white fibres, which are neither sensible nor irritable, and differs essentially, in their chemical properties, from those of the muscle. When the tendinous extremity of a muscle is rounded, it is called a *tendon;* when broad and expanded, *aponeurosis*, and sometimes *fascia*.

NAMES. Muscles are variously named, according to the arrangement of their fibres, or from their action, or from their origin and insertion, or from their figure or situation: thus, when the fibres go in the same direction, it is said to be a *simple* muscle; when they are in rays, a *radiated* muscle; when arranged like the plume of a feather, a *penniform* muscle; and, when two penniform muscles are contiguous, a *compound penniform*. Muscles sometimes surround certain cavities of the body, forming a thin lamina, as in the intestinal canal, bladder, &c. When they are situated around any opening, so as to shut or open it, they are termed *sphincters*. There are many muscles named from their action, as the *flexors*, *extensors*, *depressors*, *levators*, *corrugatores supercilii*, &c. The muscles which receive names from their origin and insertion are very numerous; as the *sterno-cleido-mastoideus*, *stylo-hyoideus*, *stylo-glossus*, &c. The *deltoid*, *pectineus*, *pyramidalis*, &c. are named from their figure; and the *pectoralis*, *lingualis*, *temporalis*, *pterygoideus*, &c. from ther situation. Muscles that concur in producing the same action, are called *congeneres;* and those that act contrary to each other, *antagonisti*.

VESSELS. Arteries, veins, and absorbents, abound in the fleshy part; but very few indeed in the tendinous.

NERVES of muscles are also numerous in the fleshy parts, and wanting in the tendinous.

USE. Muscles are the organs of motion.

MUSCLES OF THE INTEGUMENTS OF THE CRANIUM.

OCCIPITO-FRONTALIS *.—*Epicranius. Occipitalis et frontalis. Digastricus capitis.*—A broad, thin, muscular expansion, which *arises* from the upper ridge of the occipital bone, covers the back part of the head, from the mastoid process of one side around to that of the other side, becomes a flat aponeurosis on the top of the head, and is *inserted* into the skin and eyebrows, and the bone in that neighbourhood. The use of this muscle is to pull the skin of the head backwards, to raise the eyebrows, and corrugate the skin of the forehead.

CORRUGATOR SUPERCILII. — *Fronto-superciliaris.* — This muscle appears like a slip of the former; it arises above the root of the nose, and is inserted among the fibres of the occipito-frontalis. Its use is to wrinkle the eyebrows, by drawing them together.

MUSCLES OF THE EYELIDS.

ORBICULARIS PALPEBRARUM.—*Orbicularis oculi. Naso-palpebralis.*—This muscle *arises* and is inserted by the same small tendon at the inner angle of the orbit. It is a neat, regular, flat muscle, surrounding the eye, which it squeezes with violence when injured, as by dust.

LEVATOR PALPEBRÆ SUPERIORIS.—*Orbito-palpebralis.*—A small muscle, arising by a flat tendon, deep within the orbit,

---

⁂ *The reader will be pleased to observe, that though the muscles (a few only excepted, which are marked thus*) are in pairs, mention is made here only of the muscles of one side.*

near the optic foramen; it becomes fleshy as it passes the eyeballs, and ends in the eyelid by a broad expansion of muscular fibres, which finally terminate in a short flat tendon. It opens the eye by raising the upper eyelid.

MUSCLES OF THE EYEBALL.

The eyeball is completely surrounded by muscles, which move it in every direction. They arise from the very bottom of the orbit, around the optic foramen, and are implanted into the upper, under, and lateral surfaces of the sclerotic coat of the eye; and the expansions of their colourless tendons form the tunica adnata, or white of the eye: these muscles are termed *recti.*

Rectus superior.—*Attollens oculi. Levator oculi. Superbus.*—This muscle lifts the eye directly upwards, and is expressive of pride and haughtiness.

Rectus inferior.—*Deprimens oculi. Humilis.*—This is directly opposite to the former muscle, and is expressive of modesty and submission.

Rectus internus.—*Adducens oculi. Bibitorius.*—This moves the eye towards the nose.

Rectus externus.—*Abductor oculi. Indignabundus.*—This muscle turns the eye outwards.

When the recti muscles all act in succession, they roll the eye; but if they act all at once, the eye is immoveable.

Besides these, there are two whose action turns the eye obliquely.

Obliquus inferior.—*Longissimus oculi. Trochlearis.*—This *arises* with the former, from the bottom of the orbit, by a slender tendon, passes the upper part of the eyeball fleshy, then forms a smooth round tendon, which passes through a

cartilaginous pulley in the margin of the orbit, and returns down to be inserted in the middle of the eyeball.

Obliquus inferior.—*Brevissimus oculi.*—This muscle is opposed to the former in form, place, and office. It *arises* from the nasal process of the superior maxillary bone, in the edge of the orbit, and passes obliquely backwards and outwards under the ball of the eye, to be inserted opposite to the obliquus superior.

MUSCLES OF THE NOSE AND MOUTH.

Levator labii superioris alæque nasi.—*Super-maxilla-labialis major et medius. Pyramidalis. Dilator alæ nasi.*—A neat, delicate, pyramidal muscle, arising by a small double tendon from the nasal process of the superior maxillary bone, and spreading as it passes down the nose to be implanted by two fasciculi, one into the cartilage of the nose, and the other into the upper lip. Its office is to raise the upper lip, and dilate the nostrils.

Levator labii superioris proprius.—*Musculus incisivus.*—Arises immediately under the edge of the orbit, and above the incisors, by a broad flat origin, and runs downwards and obliquely inwards to the middle of the lip, where it meets its fellow. It pulls the upper lip directly upwards.

Depressor labii superioris alæque nasi.—Arises thin from near the incisores and caninus of the upper jaw; it runs upwards to be inserted into the furrow of the lip: it draws the upper lip and ala nasi downwards.

Levator anguli oris.—*Super-maxilla-labialis minor. Levator labiorum communis. Caninus.*—The origin of this muscle is between the infra-orbitar foramen of the superior maxillary bone and the first molaris, immediately above the canine tooth. It is inserted into the fibres of the *orbicularis oris*, at

the corner of the mouth, so that it raises the angle of the mouth upwards.

ZYGOMATICUS MAJOR.—*Zygomato-labialis major. Distortor oris.*—Arises from the cheek-bone, near the zygomatic suture; runs downwards and inwards to the corner of the mouth, and is lost in the fibres of the *orbicularis oris*, and depressor of the lip. Its action is that of distorting the mouth in laughter, rage, grinning, &c.

ZYGOMATICUS MINOR.—*Zygomato-labialis minor.*—Arises higher than the former from the cheek-bone. It is a much more slender muscle than the major, and is often wanting.

BUCCINATOR.—*Retractor anguli oris. Bucco-labialis.*—A large flat muscle which forms the sides of the cheek. It arises chiefly from the coronoid process of the lower jaw, and from the superior maxillary bone, close by the pterygoid process of the sphænoid bone, and proceeds directly forwards to be implanted into the corner of the mouth. In its middle it is perforated by the duct of the parotid gland. Its *use* is to flatten the cheek, assist in swallowing liquids, turning the morsel in the mouth while chewing: in blowing wind-instruments, it both receives and expels the wind; hence its name.

DEPRESSOR ANGULI ORIS.—*Maxillo-labialis. Triangularis labiorum.*—A triangular muscle arising fleshy from the edge of the lower jaw. It gradually grows smaller as it runs upwards to be implanted in the angle of the mouth, which it draws downwards.

DEPRESSOR LABII INFERIORIS.—*Mento-labialis. Quadratus genæ.*—A small square muscle which arises under the depressor anguli oris, and goes obliquely upwards and inwards, until it meets its fellow in the middle of the lip, where it mixes with the fibres of the *orbicularis*. It pulls the lip downwards.

ORBICULARIS ORIS*.—*Labialis. Constrictor oris. Sphincter oris. Osculator. Semi-orbicularis superior et inferior. Nasalis labii superioris.*—A regularly round muscle, an inch in breadth, surrounding the mouth after the manner of the orbicularis oculi, and constituting the thickness of the lips. There is a crossing of the fibres at the angles of the mouth, which has induced some to consider this as two semicircular muscles. Often there is a small slip going from the middle of the upper lip to the nose, called *nasalis labii superioris.* The orbicularis contracts the mouth, and antagonizes with the muscles inserted into it.

DEPRESSOR LABII SUPERIORIS ALÆQUE NASI.—*Incisivus medius. Constrictor, vel compressor alæ nasi.*—A very small muscle concealed under the former. It arises from the socket of the fore teeth, and goes into the root of the cartilage of the nose and upper lip, which it pulls down.

CONSTRICTOR NASI.—*Super-maxilla nasalis. Compressor nasi.*—A small scattered bundle of muscular fibres, which crosses the cartilage of the nose, and goes to the very point of the nose, meeting on the top with its fellow.

LEVATOR MENTI.—*Levator labii inferioris. Incisivus inferior.*—Arises from the lower jaw, at the root of the incisors, and is inserted into the skin on the very centre of the chin. By its contraction it draws the centre of the chin into a dimple, and moves the lip at the same time.

MUSCLES OF THE EXTERNAL EAR.

SUPERIOR AURIS.— *Temporo-auricularis. Attollens.*—A very thin flat expansion of muscular fibres, scarcely distinguishable from the fascia of the temporal muscle, upon which it lies. It arises broad and circular from the expanded tendon of the

occipito-frontalis, and is inserted narrow into the root of the cartilaginous tube of the ear. It appears to have been intended to lift the ear upwards.

ANTERIOR AURIS.----*Zygomata auricularis.*----A delicate, thin, narrow expansion, arising from near the back part of the *zygoma,* and inserted into the eminence behind the helix. This muscle is frequently not to be distinguished from the former. Its use is to raise the eminence forwards.

POSTERIOR AURIS.----*Mastoido-auricularis. Retrahens auris. Triceps auris.*----A very small, delicate, thin muscle, arising by three narrow distinct slips from about the mastoid process of the temporal bone, and going directly forwards to be inserted into the concha. Its use is to draw the ear back, and stretch the concha.

HELICIS MAJOR.---Arises from the anterior and acute part of the helix; is inserted into the cartilage of the helix, a little above the tragus. It depresses the upper part of the helix.

HELICIS MINOR.----Arises lower than the former, and is inserted into the crus of the helix. Its use is to contract the fissure.

TRAGICUS.---This muscle lies upon the concha, and stretches to the tragus. It depresses the concha, and pulls the tragus a little outwards.

ANTITRAGICUS.---A very small muscle lying in the antitragus. It dilates the mouth of the concha.

TRANSVERSUS AURIS.----Arises from the upper part of the concha, and is inserted into the inner part of the helix. It draws these parts together.

MUSCLES OF THE INTERNAL EAR.

LAXATOR TYMPANI.----*Externus mallei.*----This muscle arises from the spinous process of the sphænoid bone, and proceeds into the cavity of the tympanum, to be inserted into the long process of the malleus. Its use is to draw the malleus obliquely forwards towards its origin.

TENSOR TYMPANI.----*Internus mallei.*----Arises from the cartilaginous extremity of the Eustachian tube, within the tympanum, and is inserted into the *manubrium* of the malleus. By contracting, this muscle pulls the malleus and membrana tympani inwards.

STAPEDIUS.----This delicate muscle arises from a little cavern in the tympanum, near the cells of the mastoid process, and passes in a bony furrow to be inserted into the posterior part of the head of the stapes, which, by contracting, it draws upwards.

MUSCLES OF THE LOWER JAW.

TEMPORALIS.----*Temporo-maxillaris.*----This great muscle of the lower jaw arises from a semicircular ridge in the lower part of the parietal bone, and from the sphænoid, temporal, and frontal bones in the hollow behind the eye, where they meet to form the squamous suture; and from the aponeurosis which covers it. Its fibres are bundled together, and pass in a narrow compass under the zygoma, to be inserted all around the coronoid process of the lower jaw. Its use is to pull the lower jaw upwards, which it does very powerfully.

Spasm of this muscle constitutes *trismus*, or locked-jaw.

Masseter.—*Zygomato-maxillaris.*—A short, thick, fleshy muscle, which gives roundness to the back part of the cheek. It arises from the superior maxillary bone, near its junction with the cheek-bone, and also from the lower edge of the zygoma, and passes over the coronoid process of the lower jaw, and covers that part of the jaw quite down to its angle, where it is inserted. The parotid gland lies on the upper part of the masseter, and its duct passes over it as it crosses the cheek. The office of this muscle is the same as the temporalis.

Pterygoideus internus.—*Pterygo-maxillaris minor. Pterygoideus minor.*—Arises from the internal or flat pterygoid process of the sphænoid bone, and passes downwards and outwards to be inserted into the angle of the jaw on its inside. When this muscle contracts, it raises the jaw, and draws it a little to one side.

Pterygoideus externus. — *Pterygo-maxillaris major. Pterygoideus major.*—This arises from the external pterygoid process, and passes directly outwards, not downwards, to be implanted into the lower jaw, just below the capsular ligament, to a part of which it is connected. The use of this muscle is to move the jaw, and prevent the capsular ligament from being pinched.

MUSCLES WHICH APPEAR ABOUT THE ANTERIOR PART OF THE NECK.

Platysma myoides.—*Thoraco-facial. Musculus cutaneus. Latissimus colli. Quadratus genæ.*—This delicate, flat, and expanded muscle arises from the cellular membrane covering the pectoral and deltoid muscles. Its fibres pass upwards, to be inserted into the side of the chin and integuments of the cheek. When this muscle contracts, it pulls the skin of the cheeks and face downwards.

STERNO-CLEIDO-MASTOIDEUS.—*Sterno-mastoideus,* and *cleido mastoideus. Mastoideus.*—This arises from the upper part of the sternum, and by another head from the fore part of the clavicle. These two portions pass upwards and outwards, unite and form a big, strong, round muscle, which is inserted into the mastoid process. When one of these muscles acts, the head is pulled to one side; but, when both contract together, the head is bent forward.

Spasm of this muscle causes the wry-neck, or *caput obstipum.*

MUSCLES SITUATED BETWEEN THE LOWER-JAW AND OS HYOIDES.

DIGASTRICUS.—*Mastoido-mentalis. Biventer maxillæ inferioris.*—This muscle arises fleshy from the notch along the root of the mastoid process of the temporal bone, goes obliquely forwards and downwards, and becomes a long, thick, and round tendon, which perforates the stylo-hyoides muscle, and is affixed by a tendinous bridle to the os hyoides; then, turning upwards towards the chin, becomes again fleshy, and is inserted into the lower and anterior part of the chin. When the jaw is fixed, as in swallowing, this muscle raises the os hyoides; but when the os hyoides is fixed, it pulls down the jaw.

MYLO-HYOIDEUS.—*Maxillo-hyoideus.*—A flat and broad muscle arising from the whole semicircle of the lower jaw internally, and proceeding with very regular straight fibres to the basis of the os hyoides. It is divided from its fellow by a white tendinous line, which extends from the symphysis of the jaw to the os hyoides. When these muscles contract, the os hyoides is moved upwards.

Genio-hyoideus.—*Musculus polychrestus.*—A small neat muscle, which arises from the rough point of the chin, and proceeds downwards, becoming flat and broad, to be implanted into the basis of the os hyoides. When the jaw is fixed, these muscles move the os hyoides forwards and upwards; and when the os hyoides is fixed, they pull the jaw down.

Genio-glossus.—Arises by a narrow pointed origin from the rough tubercle behind the symphysis of the chin; spreads out like a fan as it proceeds towards the tongue, whose substance it chiefly forms. It moves the tongue in various directions.

Hyo-glossus.—*Basio-glossus. Chondro-glossus. Cerato-glossus. Basio-chondro-cerato-glossus.*—This muscle arises by three fasciculi, (one from the basis, one from the horn, and the other from the cartilage of the os hyoides,) which proceed upwards, with very slight marks of any division, to be inserted into the side of the tongue, which they pull downwards; and when both act, the tongue is made somewhat round.

Lingualis.—This muscle arises from and is inserted into the tongue. It is an irregular bundle of fibres, which runs along the side between the stylo-glossus and the genio-glossus, unconnected with any bone. The tongue is shortened and drawn backwards by these muscles.

MUSCLES SITUATED BETWEEN THE OS HYOIDES AND TRUNK.

Sterno-hyoideus.—A flat, broad, riband-like muscle, which arises from the upper part of the sternum, rather within the breast, and partly also from the clavicle and cartilage of the first rib, and goes straight up to be implanted into the base of the os hyoides, which it draws downwards.

Omo-hyoideus.—*Coraco-hyoideus.*—This is a very long thin muscle, arising fom the scapula near the coracoid process, and passing around the throat, to be inserted into the side of the os hyoides. When one of these muscles acts, the os hyoides is pulled to one side, and when both act, it is pulled downwards.

Sterno-thyroideus.—This muscle lies under the sterno-hyoideus, which it very much resembles, except that it is much shorter. It arises immediately under it, from the sternum and cartilage of the first rib, and goes upwards to be inserted into a rough ridge in the thyroid cartilage, which it pulls downwards.

Hyo-thyroideus.—*Thyreo-hyoideus.*—Arises from the basis and horn of the os hyoideus, and goes down to be implanted into the lower border of the thyroid cartilage. It raises the thyroid cartilage, and depresses the os hyoides.

Crico-thyroideus.—A very short muscle, passing from the upper edge of the cricoid to the lower margin of the thyroid cartilage. It pulls the thyroid towards the cricoid cartilage.

MUSCLES SITUATED BETWEEN THE LOWER JAW AND OS HYOIDES LATERALLY.

Stylo-glossus.—Arises from the styloid process of the temporal bone, goes obliquely downwards and forwards to be inserted into the side of the tongue in a radiated form, so as to make part of the flesh of the tongue. Its office is to pull the tongue backwards into the mouth.

Stylo-hyoideus.—*Stylo-hyoideus alter.*—Arises, like the former, from the styloid process, and goes obliquely downwards and forwards to be inserted into the side of the os hyoides. Just above its insertion, its fibres are slit so as to form a small loop for the tendon of the digastricus to pass

through. The stylo-hyoideus is sometimes accompanied by a small fleshy muscle, called *stylo-hyoideus alter*. These muscles draw the os hyoideus upwards.

STYLO-PHARYNGEUS.—This arises from the root of the styloid process. It is a long, slender muscle, expanding its fibres upon the side of the pharynx. It lifts the pharynx up to receive the food, and then straightens and compresses it to push the morsel down the œsophagus.

CIRCUMFLEXUS PALATI.—*Pterygo-palatinus. Tensor palati. Palato-salpingus. Staphilinus externus. Sphæno-salpingo-staphilinus. Musculus tubæ. Pterygo-staphilinus.* — This muscle arises from the spinous process of the sphænoid bone, and from the beginning of the Eustachian tube, along with which it runs down betwixt the pterygoid processes; it then becomes tendons, and turns around the hamulus of the pterygoid process to ascend again to the side of the velum: hence, when in action, the soft palate is made tense, by being drawn downwards.

LEVATOR PALATI MOLLIS.—*Glosso-palatinus. Salpingo-staphilinus. Sphæno-staphilinus. Pterygo-staphilinus. Petro-salpingo-staphilinus.*—This arises from the point of the petrous portion of the temporal bone, from the Eustachian tube, and also from the sphænoid bone, from which it descends to the velum pendulum palati, and spreads out in it. When these muscles contract, the soft palate is raised against the posterior opening of the nostrils, and the opening of the Eustachian tube, whilst any thing is passing into the pharynx.

MUSCLES SITUATED ABOUT THE ENTRY OF THE FAUCES.

CONSTRICTOR ISTHMI FAUCIUM.—*Glosso-staphilinus.*—This muscle arises from the very root of the tongue on each side,

goes round the middle of the velum, and ends in the *uvula*. This semicircle forms the first arch which presents itself when looking into the mouth. Its office is to pull down the soft palate, and raise the root of the tongue at the same time.

PALATO-PHARYNGEUS. — *Pharyngo-palatinus. Salpingo-pharyngeus*.—Arises in the middle of the soft palate, goes round the entry of the fauces, forming the second arch in the mouth, and ends in the edge of the thyroid cartilage. It assists in contracting the arch of the fauces.

AZYGOS UVULÆ*.—*Palato-uvularis*.—A slip of straight fibres, which goes directly down from the peak of the palate-bones to the uvula, which it pulls directly upwards.

MUSCLES SITUATED ON THE SUPERIOR PART OF THE PHARYNX.

CONSTRICTOR PHARYNGIS INFERIOR.—*Laryngo-pharyngeus*.—Arises partly from the thyroid, and partly from the cricoid cartilage, and meets its fellow in a tendinous middle line. It assists in pushing down the morsel through the pharynx.

CONSTRICTOR PHARYNGIS MEDIUS.—*Hyo-pharyngeus*.—Arises from the round point of the os hyoides and its cartilage, and is inserted into the ambit of the pharynx, its uppermost part touching the occipital bone. It compresses the pharynx, and at the same time draws the hyoid bone upwards.

CONSTRICTOR PHARYNGIS SUPERIOR.—*Cephalo-pharyngeus*.—Arises from the basis of the cranium, from the jaws, palate, and root of the tongue, and surrounds, with its fellow, the upper part of the pharynx, which it moves upwards and forwards, and also compresses.

MUSCLES SITUATED ABOUT THE GLOTTIS.

Crico-arytænoideus posticus.—A small pyramidal muscle, which arises broad from the back part of the cricoid cartilage, and goes directly upwards to be inserted by a narrow point into the back of the arytænoid cartilage. This pair of muscles pulls the arytænoid cartilage directly backwards, and lengthens the *rima glottidis*.

Crico-arytænoideus obliquus.—*Cryco-arytænoideus lateralis*.—Arises from the side of the cricoid cartilage, and goes obliquely to be inserted into the side of the arytænoid. It opens the glottis.

Thyreo-arytænoideus.—Arises from the back of the wing of the thyroid cartilage, from the hollow, and is inserted into the fore part of the arytænoid cartilage. It widens the glottis by pulling the arytænoid cartilage forward.

Arytænoideus obliquus.—These delicate muscles arise from the root of each arytænoid cartilage, and go obliquely upwards to the points of the opposite one. They draw the cartilages together, and close the glottis.

Arytænoideus transversus*.—A delicate muscle, which arises from the whole length of one arytænoid cartilage, and goes across to be implanted into the whole length of the opposite one. By drawing these cartilages together, the glottis is contracted.

Thyreo-epiglottideus.—Arises from the thyroid cartilage, and is inserted into the side of the epiglottis. It pulls the epiglottis obliquely downwards.

Arytæno-epiglottideus.—This muscle arises from the upper part of the arytænoid cartilage laterally, and is inserted into the side of the epiglottis, which it moves outwards.

MUSCLES SITUATED ON THE ANTERIOR PART OF THE ABDOMEN.

Obliquus externus.—*Costo-abdominalis. Obliquus externus descendens. Obliquus major descendens. Declivis.*— This muscle, which is the outermost of all the abdominal muscles, arises by distinct fleshy tongues, from the eight lower ribs. Its fibres pass down all in one parallel direction with each other, but oblique with respect to the abdomen. Its fleshy belly ceases about the middle of the side, and becomes a flat tendon, which goes over the fore part of the belly, until it meets its fellow in the middle. This meeting of the tendons, along with that of the other muscles to be described, forms a white line extending from the pubis to the sternum, called *linea alba.* Before the tendon of this muscle reaches the middle of the belly, it unites with the flat tendon of the inner oblique muscle, about four inches on either side of the *linea alba*, and forms a semilunar white line, called *linea semilunaris.* Besides the insertion of this muscle into the linea alba, it is implanted into the spine of the ilium, and the ligament, which extends from the spine of the ilium to the crest of the pubis, called Poupart's ligament. It compresses the abdomen ; hence its utility is very considerable in expiration, evacuation of the fæces, urine, fœtus, &c.

The operation for removing the water in abdominal ascites is now performed in the linea alba, in the middle between the pubis and umbilicus, care being taken to cause the urine to be evacuated previous to it.

Obliquus internus.—*Ilio-abdominalis. Obliquus internus ascendens. Obliquus minor.*—This muscle arises fleshy from

all the circle of the spine of the ilium ; and by a thin tendon, common with the *serratus* and *latissimus dorsi,* from the three lower spinous processes of the loins. From the spine of the ilium it ascends upwards in a radiated direction, aad crosses the abdomen to the linea alba; its higher fibres reaching the sternum, and the lower ones the pubis. Its flat tendon is inserted into the cartilages of all the false ribs, into the sternum, and into the linea alba, throughout its whole length. It acts in conjunction with the former.

TRANSVERSALIS ABDOMINIS.—*Lumbo-abdominalis.*—This muscle arises fleshy from the inner surface of the six lower ribs; from the transverse processes of the four last lumbar vertebræ; from the whole spine of the ilium, and from part of Poupart's ligament. Its fibres run directly across the abdomen, and are inserted tendinous into the whole length of the *linea alba.* This muscle also acts in conjunction with the two former in compressing the abdomen.

RECTUS ABDOMINIS.—*Pubio-sternalis.*—These two muscles cover the fore part of the abdomen, in a line between the sternum and pubis, one on each side the linea alba, and are enclosed all this way by a sheath of tendon, formed by a separation of those of the oblique, which are uppermost, from that of the transversalis, which lies underneath. The origin is fleshy from the outside of the sternum ; it proceeds about four inches in breadth all down the abdomen, and is inserted by a short flat-pointed tendon on the side of the symphysis of the pubis. It is crossed at intervals by four tendinous intersections. The recti muscles not only compress the abdomen, but bring the trunk forwards towards the pubis.

PYRAMIDALIS.—*Pubio-sub-umbilicalis.*—A small triangular

muscle immediately above the symphysis pubis, from the side of which it arises broad, and is inserted a little above into the linea alba. Its use is to assist the rectus in drawing down the sternum, and also to tighten the linea alba. Frequently it is wanting on both sides; the rectus is then found larger at its under-end.

The *umbilicus*, or navel, was originally an opening in the fœtus, through which the umbilical vein and two umbilical arteries passed. After birth, the vessels degenerate into ligaments within the abdomen, and the opening is closed, like a ring, in the middle of the *linea alba*. The tendinous fibres are very firmly connected together in this place; yet they occasionally give way, and furnish an outlet to the abdominal viscera, which constitutes the *exomphalos*, or umbilical hernia.

The *abdominal ring*, or, as it is also termed, the inguinal ring, is an opening in the lower part of the abdomen, just above the pubis, through which the spermatic cord of men passes, and the round ligament of women. It is an opening in the external oblique muscle only, the other muscles having nothing to do with it; formed by the splitting, as it were, of its tendinous fibres at that part. It begins about an inch and a half above the pubis, is oblique, looking towards the pubis. The tendinous fibres forming the upper part of the opening, go directly towards the highest point of the pubis; and the slip of fibres which form the lower edge of the slit, turn in behind the upper one, and are implanted into the pubis, within and behind the upper edge of fibres. It is this crossing of the fibres which secures the opening; for the more the muscle pulls in pressing the abdomen, the tighter the ring is drawn. Protrusions of the viscera of the abdomen at this place form *bubonocele*.

Umbilical and inguinal *herniæ* do not consist in the rupture of any part to allow the viscera to protrude. The tendinous fibres lose their strength, and constant pressure upon them causes them to be elongated, or to separate from one another: when this separation is

effected, the peritoneum lining the abdomen, an elastic membrane, always goes before the protruding viscus, and constitutes the *sac* of the hernia. Original malformation of the inguinal ring is the most frequent cause of hernia in that part: this runs through families.

MUSCLES ABOUT THE MALE ORGANS OF GENERATION.

DARTOS*.—The membrane so termed is said by many to be muscular; it appears, however, to be no more than a condensation of cellular membrane lining the scrotum, which admits of being corrugated and relaxed. It is placed immediately under the skin of the scrotum.

CREMASTER.—*Musculus testis.*—A number of fleshy fibres which arise about the ring and Poupart's ligament, and run downwards to be inserted into the *tunica vaginalis testis.* When this flat sheet of fibres contract, the testicle is drawn upwards.

ERECTOR PENIS.—*Ischio-suppenialis. Collateralis penis. Ischio-cavernosus.*—A small muscle which lies along the crus penis on each side. It arises by a slender tendon from the tuberosity of the ischium, and goes fleshy, thin, and flat over the crus penis, to be inserted about two inches up into the crus of the penis. These muscles are supposed, by pressing the penis against the pubis, to compress the *vena magna ipsius penis*, and so cause an erection.

ACCELERATOR URINÆ.—*Bulbo-urethralis. Ejaculator se-seminis.*—Arises from the sphincter of the anus, and a little above the bulb of the urethra, and meets its fellow in a white tendinous line along the lower part of the bulb of the urethra; so that these two muscles surround the whole of

the bulb. Their use is to compress the urethra in emptying it of the last drops of urine, and to expel forcibly the semen, which they do with a kind of involuntary or convulsive action.

TRANSVERSALIS PERINÆI.—*Ischio-perinealis. Transversalis penis. Transversalis perinæi alter.*—Arises by a delicate tendon from the tuberosity of the ischium, and crosses the perinæum, to be inserted into the very back part of the bulb of the urethra. There is occasionally another muscle accompanying it, called *transversalis perinæi alter.* Its chief use is to prevent the anus being too much protruded in discharging the fæces.

MUSCLES OF THE ANUS.

SPHINCTER ANI.—*Coccygio-analis.*—A broad circular band of muscular fibres surrounding the anus. It arises from a point of the os coccygis behind, and sends a neat slip forwards, by which it is attached to the back part of the *accelerator urinæ.* When it contracts, the anus is shut.

In performing the operation for *fistula in ano,* this muscle, or some part of it, is mostly divided.

LEVATOR ANI*.—*Sub-pubio-coccygius. Musculus ani latus.*—One broad thin muscle arising from the internal surface of the fore part of the pelvis; so that its origin is continued from the internal pubis all the way round to the sacrum. It grows gradually smaller as it grows downwards to surround the anus, and is inserted into the circle of the anus, the point of the os coccygis, and is mixed with the *sphincter ani.* This muscle raises the anus, dilates it, and supports it during the evacuation of the fæces.

MUSCLES OF THE FEMALE ORGANS OF GENERATION.

Erector clitoridis.—*Ischio-sub-clitorideus.*—A small delicate muscle arising from the internal part of the crus of the ischium, and inserted into the upper part of the crus, and into the body of the clitoris. Its use is to draw the clitoris downwards, and make it tense.

Sphincter vaginæ*.—*Perinæo-clitorideus.*—A circular bundle of fibres arising from the sphincter ani and sides of the vagina, which it surrounds, and inserted into the union of the *crura clitoridis.* It contracts the entrance of the vagina.

Transversus perinæi.—Origin, insertion, and use, the same as in the male.

MUSCLES SITUATED WITHIN THE PELVIS.

Obturator internus. — *Marsupialis. Bursalis.*—This muscle arises from all the internal surface of the obturator ligament, from the edges of the foramen thyroideum within the pelvis, and comes out by turning round the ischium in the notch between the tuberosity and the spine of the ilium; it proceeds between the crura of the gemini and its tendon, is united to theirs, and inserted with them by one common tendon into the root of the great trochanter. It rolls the thigh obliquely outwards.

Coccygeus.—A thin flat muscle which arises by a narrow point from the inside of the spinous process of the ilium, and is inserted, after being expanded, fleshy into the whole length of the os coccygis. It pulls the point of the os coccygis upwards.

MUSCLES SITUATED WITHIN THE CAVITY OF THE ABDOMEN.

DIAPHRAGMA*.—*Septum transversum.*—The diaphragm is called in English, midriff. It is a transverse vaulted muscle, dividing the cavity of the thorax from that of the abdomen. It is fleshy towards its borders, and tendinous in the centre, convex towards the thorax, concave towards the abdomen. It arises by one broad fleshy attachment from all the lower borders of the chest; and this fleshy origin constitutes what is considered by some as the upper or *greater muscle* of the diaphragm. It arises also by many small tendinous feet from the fore part of the loins, which soon unite in two fleshy bellies, termed the *crura diaphragmatis*, which, meeting, form what is termed the *lesser muscle* of the diaphragm. The middle of the diaphragm is a strong aponeurosis, and is distinguished by the epithet of *centrum tendinosum.* The shape of this tendinous centre is determined by the fleshy bellies; the large one above almost surrounds it, and the lesser one below meeting the larger, the two divisions give it a pointed form behind, not unlike a trefoil leaf, or the ace of hearts. The tendinous centre is fixed to the spine, so that the two sides form two convexities in the cavity of the chest.

Apertures. This great muscle is perforated by several vessels passing reciprocally betwixt the thorax and abdomen; and the apertures through which they pass, have received appropriate names:—1. *Foramen dextrum.* The vena cava passes through this foramen to the heart. The opening is of a triangular shape, tendinous, and larger than the vein requires, so that there is no danger of strangulation.—2. The *foramen sinistrum*, which is in the lower fleshy belly; it transmits the œsophagus and par vagum into the cavity of the abdomen,

and the muscular fibres are so disposed as to make some anatomists believe they acted as a sphincter to the cardia.—3. The *foramen posterius*, which is formed by the crura of the diaphragm bestriding it like an arch, to defend it from pressure. The aorta passes through this opening into the abdomen, and the thoracic duct and *vena azygos* from the cavity of the abdomen into the thorax.

Coverings. The upper surface of the diaphragm is covered by the pleura, and its under-surface by the peritoneum.

Arteries. The diaphragmatic arteries arise from the descending aorta.

Veins. The veins follow the arborescent course of the arteries, and empty their blood in the vena azygos.

Nerves. The nerves of the diaphragm are called *phrenic*, it being formerly the supposed seat of the mind: they arise from the spinal nerves of the neck.

Use. Next to the heart, this muscle is the most useful; it is the principal muscle in respiration, and is so perfect in this office, that though there be a complete anchylosis of the ribs, the person lives and breathes by the diaphragm, without feeling the loss. Its actions, in assisting those of the abdominal muscles in agitating the bowels, expelling the fæces, urine, and fœtus during labour, are of the utmost assistance.

> Inflammation of the diaphragm constitutes the disease called *paraphrenitis*, or *diaphragmatitis*. It is sometimes an idiopathic affection, but more frequently a symptomatic one.

Quadratus lumborum.—*Ilio-costalis.*—A flat, oblong' though somewhat square muscle, arising fleshy from the back part of the os ilium and ligaments of the pelvis, which tie the

back part of the ilium to the side of the sacrum and transverse processes of the lumbar vertebræ. It goes upwards to be inserted into the points of the transverse processes and the lower edge of the last rib. It supports the loins, and draws the spine to one side.

PSOAS PARVUS. — *Prelumbo-pubialis.* — A muscle of the loins, which arises from the last dorsal and first lumbar vertebræ, and passes down by the side of the psoas magnus to be inserted into the brim of the pelvis, near the acetabulum. It is often wanting. It bends the loins forwards.

PSOAS MAGNUS.—*Prelumbo-trochantineus.*—A very long and fleshy muscle filling the space upon the sides of the spine. It arises by an upper head from the last vertebra of the back, then successively from each lumbar vertebra, not only from the sides of their bodies, but likewise from their transverse processes. The muscle then descends thick, round, and fleshy, to be united with the internal iliac muscle, under Poupart's ligament, and the common tendon then bends obliquely round to be inserted into the lesser trochanter. The psoas muscles are in constant use in moving the thigh forwards, and supporting the pelvis upon the thigh-bone.

Inflammation of the cellular membrane near this muscle very frequently terminates in abscess, called *psoas abscess.* Dissections prove that it more commonly happens in the cellular structure around the muscle, than in the muscle. After a short time, the pus descends under Poupart's ligament, following the course of this muscle in the cellular substance surrounding the tendon and femoral vessels. At other times it insinuates itself under the fascia of the thigh, and opens in various places very remote from the psoas muscle; nor is its appearance upon the loins and about the hip-joint unfrequent. It mostly proves fatal.

Iliacus internus.—*Ilio-trochantineus.*—A thick, fleshy, fan-like muscle, occupying the internal surface of the iliac portion of the os innominatum. It arises from the inner edge of the crista of the ilium, and adheres to the concavity of that bone down to the brim of the pelvis, to the fore part of the bone under the spinous process. All its radiated fibres are gathered together into a tendon under Poupart's ligament, where it unites with the psoas, and the common tendon turns obliquely round to be inserted into the lesser trochanter. It acts in conjunction with the psoas in moving the thigh forwards.

MUSCLES SITUATED ON THE ANTERIOR PART OF THE THORAX.

Pectoralis major.—*Pectoralis. Sterno-humeralis.*—A large, thick, and fleshy muscle which covers all the breast. It arises from the clavicle next the sternum, ftom the edge of the sternum and the cartilaginous endings of the fifth and sixth ribs. All its fibres converge to form a flat twisted tendon, which goes before the armpit, to be inserted into the edge of the groove in the humerus for the tendon of the biceps. When this muscle contracts, the arm is brought forwards obliquely.

Cancer of the breast is situated over this muscle; and is occasionally very firmly attached to it.

Subclavius.—*Subclavianus.*—A small muscle concealed under the clavicle. It arises by a flat tendon from the cartilage of the first rib, and is inserted fleshy into a great part of the clavicle. Its use is to fix the clavicle more firmly.

Pectoralis minor.—*Costo-coracoidalis. Serratus minor anticus.*—This muscle lies underneath the pectoralis major,

close upon the ribs. It arises thick and fleshy from the third, fourth, and fifth ribs, and its fibres all converge to form a thick fleshy point, to be inserted into the very apex of the coracoid process of the scapula. It pulls the scapula directly forwards.

SERRATUS MAJOR ANTICUS.—*Costo-scapularis.*—This muscle covers the side of the chest. It arises by sharp-pointed slips or digitations from all the true ribs, except the first, and from three of the false ribs. It proceeds upwards and backwards to form a fleshy cushion, as it were, for the scapula; and its fibres all converge to be inserted into the basis of the scapula. It pulls the scapula downwards and forwards.

MUSCLES SITUATED BETWEEN THE RIBS, AND WITHIN THE THORAX.

INTERCOSTALES EXTERNI.—The external layer of muscular fibres between the ribs is so termed. They run from the spine towards the sternum, having their fibres directed from behind forwards, and stopping at the cartilages of the ribs. They assist in inspiration, by raising the ribs.

INTERCOSTALES INTERNI.—These muscles run from before backwards, underneath the former, and cross them. They raise the ribs.

STERNO-COSTALIS.—*Triangularis sterni.*—This is very generally considered as a triangular muscle lying on each side, chiefly on the inner face of the sternum, and on the cartilages of the ribs; whilst some think it is three or four muscles:—they are, in fact, three or four slips, arising from the ensiform cartilage, and going over the middle of the sternum to

be inserted into the second, third, and fourth rib. Their office is to depress the rib.

MUSCLES SITUATED ON THE ANTERIOR PART OF THE NECK CLOSE TO THE VERTEBRÆ.

LONGUS COLLI.—*Predorso-altoideus.*—This is the chief of the muscles which lie on the fore part of the neck. It arises within the thorax, from the flat part of the bodies of the three uppermost dorsal vertebræ, and from the transverse processes of the four last vertebræ of the neck; and is inserted into the fore part of the second cervical vertebra, where the opposite large muscles meet. It pulls the neck to one side, and, with its fellow, the head and neck directly forwards.

RECTUS INTERNUS CAPITIS MAJOR.—*Rectus anterior longus. Trachelo-sub-occipitalis major.*—Arises from the transverse processes of the five lower cervical vertebræ, and proceeds obliquely to be inserted into the cuneiform process of the occipital bone, just before the *foramen magnum occipitale.* It pulls the head and neck directly forwards.

RECTUS INTERNUS CAPITIS MINOR.— *Rectus anterior minor. Trachelo-sub-occipitalis minor.*—A very small muscle immediately underneath the former. It arises from the fore part of the atlas, and goes obliquely inwards to be inserted into the occipital bone, near the condyle. It assists the former.

RECTUS CAPITIS LATERALIS.—*Atloido-sub-occipitalis.*—A very small muscle like the former. It arises from the transverse processes of the atlas, and is inserted into the side of the cuneiform processes of the os occipitis. It lies immediately under the exit of the internal jugular vein. It moves the

head to one side; and, when both act, they assist the former muscles in pulling the head forwards.

MUSCLES SITUATED ON THE POSTERIOR PART OF THE TRUNK.

TRAPEZIUS.—*Dorso-super-acromialis.* *Cucullaris.*—These two muscles cover the back part of the neck and shoulders, extending from the tip of one shoulder to the tip of the other, and from the nape of the neck quite down to the loins; hence it has been compared to a monk's cowl hanging back upon the neck. It arises by a strong tendon from the most pointed part of the os occipitis, and along the transverse spine to the mastoid process: from this point, all down the neck, it has no hold of the vertebræ, but arises from the *ligamentum nuchæ:* it then arises from the spines of the two last cervical vertebræ, and those of the back. From this long origin its fibres converge into one point, the tip of the shoulder, to be inserted into the scapular end of the clavicle, the acromion of the scapula, and the whole length of its spine. The trapezius is chiefly a muscle of the scapula: it also bends the neck and head backwards.

LATISSIMUS DORSI.—*Lumbo-humeralis.*—The broadest muscle of the whole body. It covers all the lower part of the back and loins. It arises by a broad flat tendon in the middle of the back, loins, and sacrum, and fleshy from the circle of the ilium. The tendon gradually becomes a flat regular muscle, which proceeds upwards, passes over the corner of the scapula, from which it receives a small fleshy bundle, and several smaller ones as it passes over the ribs; it then becomes a twisted tendon, which, passing to the axilla,

turns under the os humeri to be inserted into the inner edge of the groove of the tendon of the biceps. Thus it appears that the anterior part of the axilla is formed by the *pectoralis major*, and the posterior by the *latissimus dorsi:* hence they support the whole body when on crutches. The latter muscle brings the arm down, when raised, as in striking with the hammer; and downwards and backwards, as in knocking with the elbow; it also turns the palm of the hand behind the back.

SERRATUS POSTICUS INFERIOR.—*Lumbo-costalis.*—A very broad thin muscle, situated in the lower part of the back, under the former, with which it arises from the three lower dorsal and four uppermost lumbar vertebræ. It soon becomes fleshy, and divides into three or four slips, each of which is inserted separately into the ninth, tenth, eleventh, and twelfth lower ribs, near their cartilage. It pulls the ribs downwards and backwards.

RHOMBOIDEUS.—*Dorso-scapularis. Rhomboideus major et minor.*—A neat, flat, square muscle, situated between the spine and the whole length of the basis of the scapula. One part arises from the three lower spinous processes of the cervical vertebræ, and goes across to be inserted into the uppermost part of the basis of the scapula. The other portion arises from the spinous processes of the four first dorsal vertebræ, and goes directly across under the former piece, to be implanted into the lowermost part of the basis of the scapula. These are generally considered as two distinct muscles, though it often happens that there is no division, and most frequently only a partial one. The use of the rhomboideus is to move the scapula upwards and backwards.

SPLENIUS.—*Splenius capitis. Splenius colli.*—This muscle lies immediately under the *trapezius* and above the *complexus*, and is named *splenius*, from its lying like a surgical splint along the side of the neck. It is a flat and broad muscle, arising from the four uppermost spinous processes of the back, and five lowest of the neck, and proceeds upwards and outwards to be implanted into the whole length of the occipital ridge and mastoid process of the temporal bone. Immediately under this portion is another arising with it, but terminating by four or five distinct tendons in the transverse processes of the upper cervical vertebræ. This portion is considered by some as a distinct muscle, and called *splenius colli*, and the former *splenius capitis*. When the muscle of one side acts, the head is pulled backwards to one side; when both act, it is drawn directly backwards; and when the muscle of one side with the *sterno-cleido mastoideus* of the same side act together, the ear is brought down upon the shoulder.

SERRATUS SUPERIOR POSTICUS.—*Dorso-costalis.*—This is a flat muscle lying on the posterior part of the chest, over the splenius. It arises by a flat and shining tendon from the spinous processes of the lower cervical and two uppermost dorsal vertebræ, and goes obliquely downwards under the upper corner of the scapula, to be inserted into the second, third, and fourth ribs, by three fleshy digitations. They elevate the ribs.

SPINALIS DORSI.—There is one long mass of muscular and tendinous fibres going from spine to spine along the whole length of the back and neck; and which is divided into *spinalis dorsi* and *cervicis*. The former arises from the two upper spinous processes of the loins and three lower of the back, and passing two spines untouched, is inserted into all

the spinous processes of the back, except the uppermost. It raises the spine.

LEVATORES COSTARUM.—*Supra-costales. Levatores costarum longiores.*—These are twelve muscles on each side, for the direct purpose of raising the ribs. They arise from the transverse processes of the last cervical and eleven uppermost dorsal vertebræ, and go down to the angle of each rib. The three last are twice as long as the others.

SACRO-LUMBALIS.—*Sacro-costalis. Additamentum ad sacro-lumbalem. Musculi accessorii.*—This muscle arises by a tendon common to it and the *longissimus dorsi,* from all the spinous processes of the lumbar vertebræ, from the spines of the sacrum, and back part of the os ilium. Just opposite the lowest rib the tendons separate, and the sacro-lumbalis goes away to be inserted by a flat tendon into each rib. From the surface of the six or seven lowest ribs there arises a small slip, which mixes with the substance of this muscle: these slips are termed *additamenta ad sacro-lumbalem,* and sometimes *musculi accessorii.* There is also a fleshy slip connected with the sacro-lumbalis, sometimes described as a distinct muscle, when it is termed *cervicalis descendens.*

CERVICALIS DESCENDENS.—This muscle is connected with the former; it arises from the transverse processes of the five lower cervical vertebræ, and passes downwards small and slender, to be inserted into the six uppermost ribs. It turns the neck obliquely backwards, and to one side.

LONGISSIMUS DORSI.—*Sacro-spinalis.*—A round, thick, firm muscle, filling up the hollow betwixt the spine and the angle of the ribs. It arises by a tendon common to it and the former muscle, and is implanted by two distinct sets of insertions into the heads of the ribs and the transverse processes of the vertebræ. The chief use of this muscle is to

assist in returning the spine to the erect posture, and to keep it erect.

TRANSVERSALIS COLLI.—Arises from the five upper transverse proceses of the dorsal vertebræ, and passes upwards to be inserted into the transverse processes of the neck. It is sometimes considered as belonging to the longissimus dorsi.

COMPLEXUS.—*Implicatus. Trigeminus. Biventer cervicis. Complexus major. Trachelo occipitalis.*—This is so called from the intricacy of its muscular and tendinous parts. It lies immediately under the splenius, and arises by ten or more tendinous feet from the transverse processes of the four lower cervical and seven uppermost dorsal vertebræ. It then becomes a large, thick, fleshy, and tendinous mass, filling up the hollow by the sides of the cervical spinous processes, and terminates by a broad fleshy head in the lower occipital ridge. It draws the head backwards.

TRACHELO-MASTOIDEUS.—*Complexus minor. Mastoideus lateralis.*—Arises from the transverse processes of the three first vertebræ of the back and the five lowest of the neck, and is inserted into the mastoid process. When one muscle contracts, the head is drawn obliquely backwards; and when both act together, it is pulled directly backwards.

LEVATOR SCAPULÆ.—*Levator proprius angularis. Musculus patientiæ. Trachelo scapularis.*—A small thin muscle which arises from the transverse processes of the four or five uppermost vertebræ of the neck, by as many distinct heads, which soon unite, and the muscle goes downwards to be inserted into the upper part of the scapula by a thin tendon. It pulls the scapula up, as in shrugging the shoulders.

SEMI-SPINALIS DORSI.—*Transverso-spinalis dorsi.*—Arises from the transverse processes of the seventh, eighth, ninth, and tenth dorsal, and is inserted into the spinous processes of

the four uppermost and last cervical vertebræ. It extends the spine obliquely backwards.

MULTIFIDUS SPINÆ.—*Semi-spinalis internus*, sive *transverso spinalis dorsi. Semi-spinalis*, sive *transverso-spinalis colli, pars interna. Transversalis lumborum*, vulgò *sacer. Transversalis dorsi. Transversalis colli.*—The many irregular portions of muscle, which authors have variously described, running from the sacrum all along the spine to the vertebræ of the neck, are comprehended under the name of *multifidus spinæ.* It begins tendinous and fleshy from the upper part of the sacrum, from the oblique processes of the lumbar vertebræ, from the transverse processes, and from the oblique processes of the cervical vertebræ; and its many bundles are inserted into the spinous processes of the third or fourth, above that from which the bundle arose. These muscles prevent the spine from being too much bent forwards, and also move the spine backwards.

SPINALIS CERVICIS.—*Semi-spinalis colli. Transverso-spinalis colli.*—Arises from the transverse processes of the six uppermost dorsal vertebræ, and is inserted into all the spinous processes of the cervical vertebræ, except the first and last. It stretches the neck obliquely backwards.

RECTUS CAPITIS POSTICUS MAJOR.—*Oxoido-occipitalis.*—Arises tendinous fram the spinous transverse process of the second cervical vertebra, and mounts up fleshy, to be inserted into the lower occipital ridge. It draws the head backwards.

RECTUS CAPITIS POSTICUS MINOR.—*Atloido-occipitales.*—A shorter muscle than the former, arising tendinous from the middle of the first vertebra of the neck, and is inserted fleshy with the former into the lower occipital ridge. Its action assists that of the major.

Obliquus capitis superior.—*Altoido-sub-mastoideus.*—The oblique muscles very much resemble the recti, except in their direction. This arises from the transverse process of the atlas, and goes obliquely to be inserted into the end of the lower occipital ridge. It assists in turning the head.

Obliquus capitis inferior.—*Oxoido-altoideus.*—Arises from the spinous process of the second cervical vertebra, and is inserted into the transverse process of the atlas. It assists in turning the head quickly.

Scalenus.—*Costo-cervicalis. Scalenus primus et secundus.*—The ancients considered this as one triangular muscle. It has since been distinguished as two, three, four, and even five distinct muscles. It is, in fact, one great, flat, triangular muscle, stretching from the ribs to the neck, closing the thorax above, and giving passage to the nerves and vessels of the arm. It arises from the transverse processes of the six lower cervical vertebræ: one part of it is inserted into the flat part of the first rib close by its cartilage; another portion is inserted into the whole length of the outer edge of the first rib; and a third portion is inserted into the upper edge of the rib. It moves the head forwards, or pulls the neck to one side.

Interspinalis.—*Interspinalis colli, dorsi, et lumborum.*—Under this term are comprehended the muscular, tendinous, and ligamentous fibres passing from one spinous process to the next throughout the spine. In the neck they are muscular; in the back, ligamentous; and in the loins, tendinous, or ligamentous. They draw the spinous processes towards each other.

Inter-transversales.—These are small bundles, strongest where there is most motion, passing between the transverse processes of the spine. They draw these parts together.

MUSCLES OF THE SUPERIOR EXTREMITIES.

SUPRA-SPINATUS. — *Super-scapulo-trochitereus parvus.* — A muscle occupying the hollow of the scapula above its spine. It arises from the back, spine, and edge of the scapula; is very thick and fleshy, and is inclosed by an aponeurosis. It runs along the scapula under the acromion, and there becomes tendon, which passes over the head of the humerus, to be inserted into the great tuberosity of the head of the humerus. In its passage, taking hold of the capsular ligament, it raises the arm directly upwards, and lifts the capsular ligament up so as to prevent its being pinched.

INFRA-SPINATUS.—*Super-scapulo-trochitereus magnus.*—This arises from the back, spine, and lower margin of the scapula, occupying the cavity below the spine of the scapula, and is covered with a strong aponeurosis like the former muscle. It becomes perfectly tendinous at the capsular liagament of the shoulder-joint, to which it is attached, and then passes over it, to be inserted into the great tuberosity of the humerus. It assists the former.

TERES MINOR.—*Super-scapulo-trochitereus minimus.*—A flat muscle, which appears somewhat round when superficially dissected. It is closely connected at its origin with the infra-spinatus; it is long, small, and fleshy; arises from the angle and all the lower edge of the scapula, and accompanies the infra-spinatus to be attached to the capsular ligament, and then inserted into the great tuberosity of the os brachii. It assists the former muscles in raising the arm.

TERES MAJOR.—*Scapulo-humeralis.*—This is a thicker and longer muscle than the former, situated below it, and arising chiefly from the angle of the scapula, and is closely con-

ected with the teres minor and infra-spinatus. Its tendon asses under the long head of the triceps, and is inserted nto the ridge on the inner side of the groove along with the endon of the latissimus dorsi. Its chief use is to draw the rm downwards and backwards.

DELTOIDES.—*Sub-acromio-humeralis.*—A thick fleshy musle which covers the top of the shoulder. It arises from the uter end of of the clavicle; from the point of the acromion of the scapula, and also from the spine of the scapula: the muscular fibres from these origins all converge over the shoulder, and form a flat, strong tendon, which is inserted nto the os brachii, one third down. Its use is to raise the rm.

CORACO-BRACHIALIS.—*Musculus perforatus Casserii.*—A ng and rather slender muscle, so named from its origin and sertion. It arises fleshy from the coracoid process of the scapula, along with the short head of the biceps, which it accompanies, and is inserted by a short tendon into the middle of the *os brachii*, and sends down an aponeurosis to the internal condyle. It raises the arm obliquely forwards and upwards.

SUBSCAPULARIS.—*Sub-scapulo-trochineus.*—This muscle lines all the convexity of the scapula, and is consequently of a triangular shape. It is very fleshy, thick, and strong, and ts fibres all converging from their origin in the two edges and base of the scapula, to form a tendon, give it a radiated or fan-like appearance. The tendon accompanies that of the supra-spinatus, and goes round the head of the humerus to be inserted into the lesser tuberosity of the os brachii. In its passage it adheres to the capsular ligament. It rolls the arm inwards, and prevents the capsular ligament from being pinched.

The superior extremity is covered by an aponeurosis

which arises from the muscles and bones of the shoulder: its use is to give origin or attachment to the muscles, and to increase their strength while in action.

MUSCLES SITUATED ON THE OS BRACHII.

Biceps flexor cubiti.—*Scapulo-radialis. Biceps. Biceps flexor brachii.*—A very thick and strong muscle situated in the fore part of the arm. It arises by two distinct heads: one, the larger and thicker head, arises by a long tendon from the coracoid process of the scapula; the other, the longer head, arises from the edge of the glenoid cavity of the scapula. About one third down the arm the two heads meet, and form a firm fleshy belly, which terminates in a tendon implanted into the tubercle on the fore part of the radius, a little below its neck. An aponeurosis is sent off from this muscle just above the flexure of the arm. It bends the fore-arm with great strength.

The aponeurosis of the biceps is sometimes punctured in bleeding. When the puncture is in the direction of the fibres, and the arm kept still, it seldom produces any mischief; but when the fibres are divided transversely, and the muscle put into much action, inflammation and its consequences take place.

Brachialis internus.—*Humero-cubitalis.*—This muscle lies immediately under the biceps, which it assists. It arises by a forked head from two thirds of the os brachii at its fore part, and continues its attachment all the way down to within an inch of the joint. It is inserted by a flat tendon into the coracoid process of the ulna, and into the capsular ligament of the joint.

Triceps extensor cubiti.—*Scapulo-humero-olecraneus. Extensor longus. Extensor brevis. Brachialis internus.*—This

muscle is situated on the back part of the arm, and was formerly described as three distinct muscles. It arises by a long tendon from the edge of the scapula; by an outer head from the os brachii, just under the greater tuberosity; and by an internal head, which is the shortest from the inside of the os brachii, just under the insertion of the teres major. All these heads unite and are continued downwards, adhering to the os brachii, to within an inch of the joint, where a strong thick tendon is formed, which is implanted into the olecranon, and partly into the capsular ligament. It extends the fore-arm with considerable force.

ANCONEUS.—*Epicondylo-cubitalis.*—A small triangular muscle, placed on the back part of the elbow. It arises from the external condyle of the os brachii, and is inserted into the back part, or ridge of the ulna. It assists in extending the fore-arm.

MUSCLES SITUATED ON THE FORE-ARM.

SUPINATOR RADII LONGUS.—*Humero-super-radialis.*—This muscle forms the very edge of the fore-arm, arising from the edge above the external condyle of the os brachii, becomes very fleshy as it passes the elbow-joint, then tendinous and long, and is inserted into the radius, near the styloid process. It assists in turning the palm of the hand upwards.

EXTENSOR CARPI RADIALIS LONGIOR.—*Radialis externus longior.*—*Humero-super-metacarpeus.*—Arises from the ridge of the os brachii, just above the external condyle: having become a thick fleshy belly, it passes along the back of the radius, and then forms a thin tendon, which passes over the wrist, under the annular ligament, and is inserted into the root of the metacarpal bone of the fore-finger. It extends the wrist.

EXTENSOR CARPI RADIALIS BREVIOR.—*Radialis externus brevior.—Epiconydlo-super-metacarpeus.*—This muscle is almost the same in origin and use with the former. It is inserted into the fore-part of the metacarpal bone of the middle finger.

EXTENSOR DIGITORUM COMMUNIS.—*Epicondylo-super-phalangeus communis.*—This muscle covers the middle of the back part of the fore-arm, and betwixt the extensor radialis secundus and the extensor minimi digiti. It arises from the outer condyle of the humerus; it grows very fleshy and thick as it descends, and about the middle of the fore-arm divides into three slips. The tendons pass under the annular ligament, along the metacarpal bones, and first phalanx of the fingers, where they are joined by those of the interossei and lumbricales, and form a tendinous sheath, which surrounds the back of all the fingers. It extends the fingers.

EXTENSOR MINIMI DIGITI.—*Auricularis.*—The little finger is raised by this muscle, as in picking the ear. It arises from the outer condyle of the humerus, and accompanies the extensor digitorum communis, passes under the annular ligament, in a channel peculiar to it, and is inserted into the second joint of the little finger.

EXTENSOR CARPI ULNARIS.—*Ulnaris externus. Cubito super. metacarpeus.*—Arises from the external tubercle of the humerus, and proceeds along the ulnar edge of the arm, to be affixed tendinous into the outside of the lower head of the metacarpal bone of the little finger. Its use is to extend the carpus.

FLEXOR CARPI ULNARIS.—*Ulnaris internus. Cubito-carpeus.*—This muscle arises tendinous from the inner condyle of the os humeri, and fleshy from the olecranon; it proceeds fleshy along the lower edge of the arm; about the middle it be-

comes tendon, which goes to be inserted into the os pisiforme. The flexor carpi radialis with this muscle bend the wrist with great force ; alone it pulls the hand side-ways.

PALMARIS LONGUS.—*Epitro-palmaris.*—A long, thin muscle, that arises from the internal condyle of the os humeri ; its fleshy belly is but two or three inches long ; it then forms a slender tendon, and passes along the middle of the fore-arm to be inserted into the annular ligament, just under the root of the thumb. It expands from thence into an aponeurosis, which covers and protects the muscles and blood-vessels of the hand. It bends the hand.

FLEXOR CARPI RADIALIS.—*Radialis internus; Epitrochlo-metacarpeus.*—A long, thin muscle, arising, by a thick, short, and split tendon, from the internal condyle of the humerus, from which it proceeds fleshy, along the middle of the fore-arm in the course of the radius. Its thin tendon passes under the annular ligament, in a groove peculiar to itself, to be inserted into the metacarpal bone of the fore-finger. It bends the wrist.

PRONATOR RADII TERES.—*Epitroclo-radialis.*—A small, round muscle, which arises from the internal condyle of the humerus, and from the coronoid process of the ulna. It is chiefly fleshy, and of a conical shape, stretching obliquely across the arm, to be inserted into the outer ridge of the radius, about the middle of its length. It turns the hand downwards.

SUPINATOR RADII BREVIS.—*Epicondilo-radialis.*—A short, thick, and fleshy muscle : it arises from the external condyle of the os brachii, from the edge of the ulna, and from the interosseous ligament ; and is turned over the radius, to be inserted into its ridge. It rotates the radius outwards.

EXTENSOR OSSIS METACARPI POLLICIS MANUS.—*Cubito-super-metacarpeus pollicis. Extensor primus pollicis. Exten-*

sor primi internodii. Abductor longus pollicis manûs.—This muscle crosses the fore-edge of the radius ; arising from the edge of the ulna, about the middle of the arm. Its fleshy belly divides into two, three, or four slips, with distinct tendons, which go under the ligament of the carpus, to be inserted into the root of the first metacarpal bone of the thumb. Its use is to extend the thumb.

EXTENSOR PRIMI INTERNODII.—*Cubito-super-phalangeus primus pollicis. Extensor minor pollicis manûs. Extensor pollicis primus. Extensor secundi internodii. Extensor secundus pollicis.*—This muscle lies close to the former, arising just below it, and accompanying it under the ligament of the wrist; it passes on to be inserted into the first phalanx of the thumb, which it extends.

EXTENSOR SECUNDI INTERNODII.—*Cubito-super-phalangeus secundus pollicis. Extensor major pollicis manûs. Extensor pollicis secundus. Extensor tertii internodii. Extensor tertius pollicis.*—A thick fleshy muscle, arising higher than the former on the ulna, and passing straight down that bone. Its small tendon passes the ligament of the wrist in a peculiar ring, and goes on to be inserted into the last bone of the thumb, which it extends.

INDICATOR.—*Extensor indicis proprius. Cubito-super-phalangeus primus indicis.*—Arises from the ridge of the ulna, is attached to the interosseous ligament : its tendon passes under the annular ligament, and then joins with the indicator tendon of the common extensor. It extends all the three joints of the fore-finger.

FLEXOR DIGITORUM SUBLIMIS.—*Perforatus.—Epitriclo-phalangeus communis.*—A large fleshy muscle, which lies between the palmaris longus, and flexor ulnaris ; it arises from the internal condyle of the os brachii, from the ligament of the elbow-joint, the coronoid process of the ulna, and from

the upper part of the radius. Its fleshy and thick belly divides about the middle of the fore-arm into four fleshy slips, each of which gives off a slender tendon, which passes under the annular ligament, to be inserted, after being perforated near the first phalanx of the fingers, by the tendons of the flexor digitorum profundus, into the fore part of the second phalanx. The use of this strong muscle is to bend the first and second phalanges.

Flexor digitorum profundus.—*Perforans.—Cubito-phalangeus communis.*—This muscle lies deeper than the former, which it accompanies: it arises from the internal surface of the ulna, and the interosseous ligament; divides into four slips, whose tendons pass under the annular ligament, perforate those of the flexor sublimis, and are inserted into the fore part of the last phalanx of the fingers. It bends the last joint of the fingers.

Flexor longus pollicis.—*Radio-phalangeus pollicis. Flexor tertii internodii.*—This muscle runs by the inside of the radius, arising from it, and the interosseous ligament; it has often, also, another head from the condyle of the humerus, and fore part of the ulna. It passes under the annular ligament, and is inserted into the last bone of the thumb. It bends the thumb.

Pronator radii quadratus.—*Cubito-radialis.*—This lies flat upon the interosseous ligament in the fore part of the arm, about two inches above the wrist. It is nearly square, its fibres going across between the radius and ulna. It turns the radius upon the ulna.

MUSCLES SITUATED CHIEFLY ON THE HAND.

Lumbricales.—*Palmo-phalangeus. Musculi fidicinales.* Four round small muscles, resembling earth-worms. They

arise in the palm of the hand, from the tendons of the profundus: their small tendons reach the middle of the second phalanx. They are chiefly useful in performing the quick short motions of the fingers on musical instruments, &c.

FLEXOR BREVIS POLLICIS MANUS.—*Carpo-phalangeus pollicis. Flexor secundi internodii.*—A two-headed muscle, situated on the inside of the thumb; one head arises from the os trapezium, the other from the os magnum. They are inserted into the sesamoid bones, and edge of the first bone of the thumb. The use of this muscle is to bend the first joint of the thumb.

OPPONENS POLLICIS.—*Flexor ossis metacarpi pollicis. Carpo-metacarpeus pollicis.*—Lies under the abductor pollicis, arising from the os scaphoides and ligament of the wrist. It is inserted into the fore part of the metacarpal bone of the thumb. It bends the thumb, as in clenching the fist.

ABDUCTOR POLLICIS MANUS.—*Carpo-super-phalangeus pollicis.*—This muscle lies immediately under the common integuments: it arises from the annular ligament of the wrist, and from the os scaphoides; then bends gradually round the thumb, to be inserted into the first bone of the thumb. A second muscle is described by Albinus, by the same name. It pulls the thumb from the fingers.

ADDUCTOR POLLICIS MANUS.—*Metacarpo-phalangeus pollicis.*—The metacarpal bone of the middle finger gives origin to this triangular muscle; it goes directly across to meet the thumb, and is inserted into the root of the first phalanx. It draws the thumb towards the fore-finger.

ABDUCTOR INDICIS MANUS.—A flat and broad muscle: it arises from the os trapezium, and the first bone of the thumb, and is inserted into the back part of the first bone of the finger, which it pulls forwards towards the thumb.

Palmaris brevis.—*Palmaro-cutaneus. Palmaris cutaneus.* A thin, flat, cutaneous muscle: it arises from the palmar aponeurosis, and stretches across the hand, to be inserted into the metacarpal bone of the little finger, and the superincumbent fat. It stretches the aponeurosis of the palm of the hand.

Abductor minimi digiti manus.—*Carpo-phalangeus minimi digiti.*—A thin, fleshy muscle, upon which the hand rests in writing: it arises from the os pisiforme, and the outer end of the annular ligament, and is inserted laterally into the first bone of the little finger. It draws the little finger away from the rest.

Adductor minimi digiti.—*Carpo-metacarpeus minimi digiti.*—Arises from the ligament of the wrist and cuneiform bone, and turns round the metacarpal bone of the little finger, to be inserted into the outside of it. It pulls the metacarpal bone of the little finger towards the thumb.

Flexor parvus minimi digiti.—A small thin muscle, which arises from the ligament of the wrist and unciform bone, and accompanies the abductor minimi digiti, and has nearly the same insertion. It bends the little finger.

Interossei externi et interni.—*Metacarpo-phalangei-laterales.*—These are small muscles, lying between the metacarpal bones, and assisting the lumbricales in bending the fingers.

MUSCLES OF THE INFERIOR EXTREMITIES.

The muscles of the inferior extremity, are covered by a strong aponeurosis, or fascia, which appears to originate from the outside of the bones of the pelvis, but is a continuation of the flat tendons which cover the muscles of the loins and the abdomen. It attaches itself to the linea aspera, to

the head of the tibia and fibula, to the spine of the tibia, to some of the bones of the tarsus; it forms the annular ligament, and terminates upon the foot. In its course it is considerably strengthened by the aponeurosis, sent off from the muscles, and is strongest on the outside of the thigh. Its use is to strengthen the power of the muscles when in action. See *Tensor Vaginæ femoris, page* 141.

PECTINALIS.—*Super-pubio-femoralis. Pectinæus.*—A broad flat, square muscle, lying under the skin, and arising from the os pubis, or *pectinis,* from that part of it which forms the brim of the pelvis, immediately above the foramen thyroideum; it then proceeds downwards, to be inserted by a long flat tendon into the linea aspera of the thigh-bone, just below the little trochanter. Its use is to bring the knees together; to raise the thigh upwards, and give it a degree of rotation outwards.

TRICEPS ADDUCTOR FEMORIS.—A broad flat muscle, with three heads, which have so little connexion with one another, that they are usually described as three muscles:—

1. *Adductor longus femoris. Pubio-femoralis.*—This is the uppermost head; it arises from the upper and fore part of the pubis, by a short roundish tendon, which becomes a thick fleshy belly, and is inserted by a flat tendon along the middle part of the linea aspera.

2. *Adductor brevis femoris. Sub-pubio-femoralis.*—This portion lies under the former: it arises from the symphysis of the pubis, by a thick flat tendon, which swells into a thick fleshy belly; it then becomes flat, and is inserted by a flat tendon, into the upper part of the linea aspera.

3. *Adductor magnus femoris. Ischio-femoralis.* The head of this muscle lies behind the former: it arises from the symphysis pubis, and all along the flat edge of the foramen thyroideum, from whence it goes to be inserted into the linea

aspera throughout its whole length, its fibres having various degrees of obliquity.

The use of all these muscles is the same; to bring the thigh forwards and upwards.

Obturator externus.—*Sub-pubio-trochanterius externus.* This short muscle, so named from its origin, arises from the obturator ligament, and from the ramus ischii and pubis, forming the sides of the thyroid foramen. Its fleshy fibres are soon gathered into a round tendon, which twists under the os femoris, to be inserted into the cavity at the root of the great trochanter, attaching itself to the capsular ligament. Its use is to roll the thigh obliquely outwards, and to prevent the capsular ligament from being pinched.

Gluteus maximus.—*Sacro-femoralis. Gluteus magnus. Gluteus major.*—This muscle lies immediately under the skin, upon the posterior part of the thigh, upon which we sit: it arises fleshy from the posterior half of the spine of the ilium, from the junction of the ilium and sacrum, from the whole external surface of the sacrum, and from the sacro-sciatic ligament. All the fibres from these origins run obliquely forwards and downwards to the thigh-bone, where they are gathered into a broad tendon, which is implanted into about three inches of the linea aspera, at its upper and outer part. It extends the thigh, by pulling it directly backwards and a little outwards.

Gluteus medius.—*Ilio-trochanterius magnus.*—This lies immediately under the former: it arises from the anterior half of the spine of the ilium, and from its anterior superior spinous process. Its fibres all converge towards the great trochanter, into which the muscle is inserted by a broad tendon. Its use is to draw the thigh outwards and a little backwards, and to roll the thigh outwards, especially when it is bended.

GLUTEUS MINIMUS.—*Ilio-trochanterius parvus. Gluteus minor.*—A muscle radiated like the former, but much smaller: it arises from the middle of the external surface of the ilium, from a ridge which is continued from the superior anterior spinous process. Its short flat tendon is inserted into the fore and upper part of the great trochanter. The use of this is to assist the other glutei muscles.

PYRIFORMIS.—*Sacro-trochanterius. Iliacus externus. Pyramidalis.*—This muscle is so named from its shape: it arises by three fleshy and tendinous beginnings from the hollow of the sacrum and sacro-sciatic notch, and growing gradually narrower, it passes between the gluteus minor and gemini, and its round tendon is inserted into the upper part of the cavity, at the inner side of the root of the great trochanter. The use of the pyriformis is to move the thigh upwards, and roll it outwards.

GEMINI.—*Ischio-trochanterius. Gemelli.*—This is a biceps muscle, and its heads are so distinct, that they are often taken for two muscles. The uppermost head is the larger and stronger one: it arises from the spinous process of the ischium: the smaller head begins from the outer end of the tuberosity of the ischium. Both heads are fleshy in their length, and, meeting, form a tendon to be inserted into the root of the great trochanter. This muscle rolls the thigh-bone outwards.

OBTURATOR INTERNUS.—*Marsupialis. Sub-pubio trochanterius internus.*—A short muscle: it arises within the pelvis, from the anterior half of the foramen thyroideum, and partly from the obturator ligament. Its fibres converge, and give off a round tendon, which passes in a hollow between the spine and tuberosity of the ischium to be inserted with the gemini into the root of the great trochanter: it rolls the thigh obliquely outwards.

QUADRATUS FEMORIS.—*Ischio-sub-trochanterius.*—A thin, flat muscle, which passes in a transverse direction, between the tuberosity of the ischium and the thigh-bone. It arises from the outside of the tuberosity of the ischium, and is inserted into the ridge, between the large and little trochanters. It rolls the thigh outwards.

MUSCLES SITUATED ON THE THIGH.

TENSOR VAGINÆ FEMORIS.—*Ilio-aponeuroso-femoris. Fascialis. Musculus aponeurosis*, vel *fasciæ latæ.*—The anterior superior spinous process of the ilium gives rise to this muscle, by a narrow, tendinous, and fleshy slip, from whence it proceeds to be inserted into the inside of the fascia of the thigh, which it stretches.

SARTORIUS.—*Ilio-pretibialis.*—A long muscle, that extends obliquely across the whole thigh. It arises tendinous from the anterior superior spinous process of the ilium; it then forms a thin, flat belly, somewhat like a strap, which goes obliquely round the thigh, to be inserted into the inner side of the head of the tibia, by a broad aponeurosis. This muscle acts in bending the leg obliquely inwards, and bringing one leg across the other, an action common to tailors, whence it is termed the tailor's muscle.

The first incision in the modern operation for popliteal aneurism, is made in the middle of the thigh, in the direction of this muscle; and the dissection is by some surgeons carried on below the sartorius; whilst others, not less skilful, preferhaving the sartorius on the underside of the incision.

GRACILIS.—*Sub-pubio-pretibialis.*—*Gracilis internus. Restus internus femoris.*—A small, thin, and flat muscle: it arises tendinous from the pubis, near its symphysis, and passes di-

rectly under the integuments down to the knee, to be inserted under the sartorius, into the side of the head of the tibia. It assists the sartorius in bending the leg.

RECTUS FEMORIS.—*Ilio-rotuleus. Rectus cruris. Rectus* sive *gracilis anterior*.—A thin flat biceps muscle, in the anterior part of the thigh, called *rectus*, from its straight direction. It arises from the inferior anterior spinous process of the ilium, by a short round tendon, and from the edge of the acetabulum and capsular ligament. A flat tendon is formed by the union of these heads, which soon becomes fleshy, and the muscle passes directly down towards the patella. This muscle is united at the sides to the vasti, at the back part to the cruræus; and its tendon, along with that of the cruræus, goes to be implanted into the patella. It assists in extending the leg in a very powerful manner.

VASTUS EXTERNUS.—Outer part of *Tri-femoro-rotuleus*.—A large muscle, situated on the fore part of the thigh. It arises by a thick and strong tendon from the root of the great trochanter, and upper part of the linea aspera; passes down the thigh, attached to the cruræus, and forms a flat tendon, which embraces the patella, and goes round the head of the tibia, to be inserted into the inner side of the knee. It extends the leg.

VASTUS INTERNUS.—Inner part of *Tri-femoro-rotuleus*.—This muscle resembles very much the former, but is not so large. It arises tendinous and fleshy from the fore part of the little trochanter, and from the whole of the linea aspera: its fibres run obliquely forwards and downwards, accompanying the cruræus, and the tendon surrounds the knee-pan, to be inserted into the outer part of the head of the tibia. The vastus internus assists the externus in extending the leg.

CRURÆUS.—Middle of *Tri-femoro-rotuleus. Cruralis*.—The little trochanter, and nearly the whole of the fore-part

of the os femoris, give origin to this muscle. On its outer edge and fore part it is united to the vastus externus, and on its inner edge and fore part, to the vastus internus. At its lower part the cruralis is joined to the tendon of the rectus, and forms one tendon, which is inserted into the patella.

SUBCRURÆI.—Two little muscular slips, sometimes found under the cruræus; they are inserted into the capsular ligament, which they pull up. The cruræus assists in extending the leg.

SEMITENDINOSUS.—*Ischio-pretibialis. Seminervosus.*—A muscle, so called because its lower half is composed of a small round tendon. It arises tendinous and fleshy from the posterior portion of the tuberosity of the ischium, and continues a little way connected with the biceps cruris; it then leaves it, and goes obliquely inwards to form a long tendon, which passes down behind the inner tubercle of the knee, to be inserted into the inside of the tibia, a little below its tuberosity. Its use is to bend the leg backwards, and a little inwards.

SEMIMEMBRANOSUS.—*Ischio-poplito-tibialis.*—This muscle begins and ends by a flat tendon, somewhat like a membrane: it arises by a broad, thin, and flat tendon, from the fore part of the tuberosity of the ischium, becomes thick and fleshy in its middle, and terminates in a short tendon, which is inserted behind the head of the tibia, and, with the tendon of the semitendinosus, forms the inner ham-string. Its use is to bend the leg, and bring it directly backwards.

BICEPS FLEXOR CRURIS.—*Ischio-femoro-peronealis. Biceps cruris.*—This muscle, so named from its having two heads, lies immediately under the skin in the back part of the leg. It arises tendinous from the outer part of the tuberosity of the ischium, with the semitendinosus. The other, which is the short head, begins from the linea aspera, all the way down

to its bifurcation. A little above the condyle of the femur the two heads unite, and the muscle proceeds outwards, to be inserted into the head of the fibula, forming the outer hamstring. Its use is to bend the leg.

POPLITEUS.—*Femoro-poplito-tibialis.*—A small triangular muscle, lying across the back part of the knee-joint. It arises from the outer condyle of the femur, and is inserted into a ridge on the back part of the tibia. It assists in bending the leg, and prevents the capsular ligament from being pinched.

MUSCLES SITUATED ON THE LEG.

GASTROCNEMIUS EXTERNUS.—*Bifemoro-calcaneus. Gemellus.*—The large fleshy muscle that forms the calf of the leg. It arises, by two heads, from the external and internal condyle of the femur: the two heads meet, and run down the calf, with the appearance of a raphè between; they then form a flat tendon, very broad at its commencement, which passes down the leg, and unites with the tendon of the gastrocnemius internus, a little above the ankle.

GASTROCNEMIUS INTERNUS.—*Tibio-calcaneus. Soleus. Extensor tarsi suralis.*—Some have compared this muscle to a sole-fish. It arises, like the former, by two heads: the one from the back part of the head of the fibula, the other from the posterior, and upper part of the tibia: these immediately unite, and form a large fleshy belly. About half way down the leg it becomes tendinous, and soon unites with the tendon of the gastrocnemius externus. From this union the great tendon, called *tendo Achillis*, is formed, which inserts both muscles into the extremity of the os calcis.

PLANTARIS.—*Femoro-calcaneus parvus. Tibialis gracilis,* vulgò *plantaris. Extensor tarsi minor,* vulgò *plantaris.*—This muscle appears to have been named *plantaris*, from a

mistaken notion that it formed the plantar aponeurosis, like the palmaris of the hand. It is a long and slender muscle, arising fleshy from the external condyle of the femur, and adhering firmly to the capsular ligament of the knee. It soon forms a small flat tendon, which runs between the inner head of the external gastrocnemius, and the soleus, to be attached to the tendo Achillis, with which it is inserted into the inner side of the os calcis. The use of this muscle is to prevent the capsular ligament of the knee-joint from being pinched, and to assist the gastrocnemii muscles.

TIBIALIS ANTICUS. — *Tibia-super-tarseus.* — This muscle arises from the fore part and outside of the tibia, beginning just under the head of that bone. About two-thirds down the bone it becomes tendon, which passes obliquely over the leg, crosses the ankle, and goes under the annular ligament, to be inserted into the upper and inner part of the os cuneiforme internum, and metatarsal bone of the great toe. It extends the foot, and turns the toes inwards.

TIBIALIS POSTICUS. — *Tibio-sub-tarseus.* — A penniform muscle, so named from its situation. It arises from the back part, and ridge of the tibia, from the opposite part of the fibula, and from the interosseous ligament quite down to the ankle. About the middle of the tibia it becomes tendinous and fleshy, and the tendon passes in a groove at the inner ankle, and expands so as to grasp the bones of the tarsus, and is inserted into the two first metatarsal bones, os calcis, and os cuboides. Its contraction pulls the foot in, so as to put the toes together.

PERONEUS LONGUS.—*Peroneo-sub-tarseus. Peroneus maximus*, vulgò *peroneus posterior. Peroneus primus*, seu *posticus.* —This muscle arises from the fore-part of the head of the fibula, and from the upper part of that bone. It has

also a small slip coming from the upper part of the tibia. About the middle of the leg its tendon emerges towards the integuments, and passing the outer ankle in a cartilaginous pulley, which also transmits the peroneus brevis, it is reflected to the sinuosity of the os calcis, and runs along a groove in the os cuboides, to be inserted tendinous into the outside of the root of the metatarsal bone of the great toe, and the os cuneiforme internum. It moves the foot outwards, and assists in extending it.

PERONEUS BREVIS.—*Peroneo-metatarsus magnus. Peroneus medius,* vulgò *peroneus anticus. Peroneus secundus,* seu *anticus.*—Arises fleshy from above the middle of the external part of the fibula, all the way down to the ankle; it also adheres to the tendinous partition between it and the common extensors. Its tendon passes under that of the peroneus longus, by the outer ankle, to be inserted into the metatarsal bone of the little toe. This muscle assists the former in pulling the foot outwards and extending it a little.

EXTENSOR LONGUS DIGITORUM PEDIS.—*Peroneo-super-phalangeus communis. Extensor longus. Peroneus tertius. Nonus Vesalii.*—A common extensor muscle of the toes. It arises from the outer and fore part of the head of the tibia, just below the knee; also from the head of the fibula, the interosseous ligament, and the tendinous fascia of the leg. It soon becomes a thick fleshy muscle, and is divided into three distinct portions, which form three round tendons, that pass obliquely inwards under the annular ligament of the tarsus, where the first portion divides its tendon into two. These four tendons are inserted flat into the root of the first joint of each of the four small toes, expanding along the upper side, as far as the root of the last joint. A portion of this muscle also arises from the middle of the fibula, and sends its fleshy

fibres forwards to a tendon which goes under the annular ligament, to be inserted into the root of the metatarsal bone of the little toe. This portion is termed, by Albinus, *peroneus tertius.*

Extensor proprius pollicis pedis.—*Peroneo-super-phalangeus pollicis. Extensor longus.*—An extensor muscle of the great toe. It arises by an acute, tendinous, and fleshy beginning, from the head of the fibula: it continues a slender muscle down the fibula, and its tendon passes under the annular ligament, to be inserted into the posterior part of the last and first joint of the great toe.

Flexor longus digitorum pedis. — *Tibio-phalangeus communis. Profundus. Perforans.*—This muscle arises from nearly the whole of the back part of the tibia. Near the ankle it becomes tendinous, crosses the tendon of the tibialis posticus behind the ankle-joint, and goes forward in a groove of the os calcis, and about the middle of the sole of the foot divides into four tendons, which pass through the slits of the *perforatus,* to be inserted into the extremity of the last joint of the four lesser toes. Just before the division of the tendon, it receives a considerable tendon from that of the flexor pollicis longus. The use of the perforans is to bend the last joint of the toes.

Flexor digitorum accessorius. — *Massa carnea Jacobi Sylvii.*—This is a small fleshy mass connected with the former muscle, whose office it assists. It arises from the lower part of the os calcis, and from its tuberosity, and is inserted into the flexor longus digitorum pedis, at its division into four tendons.

Flexor longus pollicis pedis.—*Peroneo-sub-phalangeus pollicis.* — A flexor muscle of the great toe, arising fleshy from the upper part of the fibula, and being continued down the same bone, almost to the ankle, by a double order of ob-

lique fleshy fibres. Its tendon passes under the annular ligament, to be inserted into the last joint of the great toe.

MUSCLES CHIEFLY SITUATED ON THE FOOT.

EXTENSOR BREVIS DIGITORUM PEDIS.—*Calco-super-phalangeus communis. Extensor brevis.*—A common extensor of the toes, very closely connected with the extensor longus digitorum pedis. It arises fleshy and tendinous from the fore part of the os calcis, and, passing forwards, soon divides it into distinct muscular heads, from each of which a tendon is sent off to be inserted into the great toe, and the three next to it, with the extensor longus.

FLEXOR BREVIS DIGITORUM PEDIS.—*Perforatus. Calco-sub-phalangeus communis. Sublimis.*—This muscle is placed on the sole of the foot: it arises from the inferior and posterior part of the os calcis, soon becomes a fleshy belly, and divides into four tendons, which are split about the root of the first bone of the toes for the passage of the tendons of the flexor longus digitorum pedis. The tendons of the brevis then go on to be inserted into the second phalanx of the four lesser toes, which they bend.

LUMBRICALES PEDIS.—These four small muscles resemble somewhat the earth-worm, or *lumbricus*. They arise from the forks of the tendons of the flexor profundus, and pass on to be inserted by slender tendons into the inside of the first joint of the four lesser toes. Their use is to bend the first joint of the toes, and to draw them towards the great toe.

FLEXOR BREVIS POLLICIS PEDIS. — *Tarso-sub-phalangeus pollicis.*—Arises by a long tendon from the under and fore part of the os calcis, and from the os cuneiforme externum; it soon divides into two heads, one of which goes to the abduc-

tor, and the other to the abductor pollicis, and is inserted with the tendons of those muscles into the external sesamoid bone and root of the first joint of the great toe, which it bends.

Abductor pollicis pedis.—*Calco-sub-phalangeus pollicis. Thenar.*—Arises by short tendinous fibres from the inner and lower part of the os calcis, and is inserted tendinous into the internal sesamoid bone and root of the first joint of the great toe. Its use is to pull the great toe from the rest.

Adductor pollicis pedis. — *Metatarso-sub-phalangeus pollicis. Antithenar.*—Arises by a long delicate tendon from the ligament extending from the os calcis to the os cuboides, soon divides into two fleshy heads, which again unite, and go obliquely inwards to be inserted into the sesamoid bone, or first bone of the great toe. Its use is to bring this toe nearer to the rest.

Abductor minimi digiti pedis. — *Calco-sul-phalangeus minimi digiti.*—A slender muscle lying on the outside of the foot. It arises from the tuberosity of the os calcis: it forms two small tendons; the shorter one is inserted into the root of the metatarsal bone of the little toe, and the longer goes on to be fixed into the root of the first bone of that toe. Its use is to bend the little toe, and carry it somewhat outwards, and to support the tarsus in walking.

Flexor brevis minimi digiti pedis.—*Tarso-sub-phalangeus minimi digiti. Parathenar minor.*—A very small muscle, arising from the metatarsal bone of the little toe, which it goes over, to be inserted into the root of the first bone of the little toe. Its use is to bend this toe.

Transversalis pedis.—*Metatarso-sub-phalangeus. Transversalis pedis.*—This muscle extends transversely across the sole of the foot, arising from the ligament which connects

the bones of the tarsus, going across to be inserted into the tendon of the adductor pollicis. It contracts the foot.

INTEROSSEI EXTERNI ET INTERNI.—*Metatarso-phalangei laterales.*—Four small double-headed muscles situated externally, and four internally, all arising from the metatarsal bones they lie between. Their tendons meet those of the long and short extensors, forming all together the sheath which covers the upper part of the toes.

The muscles situated on the sole of the foot are covered by a strong flat tendon, called the *plantar aponeurosis*, extended from the os calcis to the first joint of all the toes, protecting the muscles, blood-vessels, and nerves running under it.

PHYSIOLOGY AND PHENOMENA OF MUSCULAR MOTION.

Muscular motions are of three kinds; namely, voluntary, involuntary, and mixed.

The VOLUNTARY MOTIONS of muscles are such as proceed from an immediate exertion of the active powers of the will: thus the mind directs the arm to be raised or depressed, the knee to be bent, the tongue to move, &c.

The INVOLUNTARY MOTIONS of muscles are those which are performed by organs, seemingly of their own accord, without any attention of the mind or consciousness of its active power; as the contraction and dilatation of the heart, arteries, veins, absorbents, stomach, intestines, &c.

The MIXED MOTIONS are those which are in part under the controul of the will, but which ordinarily act without our being conscious of their acting; as is perceived in the muscles of respiration, the intercostals, the abdominal muscles, and the diaphragm.

When a muscle acts, it becomes shorter and thicker; both its origin and insertion are drawn towards its middle. The sphincter muscles are always in action; and so likewise are antagonist muscles, even when they seem at rest. When two antagonist muscles move with equal force, the part which they are designed to move, remains at rest; but if one of the antagonist muscles remain at rest, while the other acts, the part is moved towards the centre of motion. The extensor muscles are generally weaker than the flexors: hence the most natural situation, in which all the powers maintain a just equilibrium, is that which our limbs take during sleep. The middle state, between flexion and extension, we preserve the longest time without fatigue. This preponderance of the flexor muscles arises from their fibres being more numerous than the extensors; their insertion into bones is farther from the centre of their motions, under an angle more open, and which increases in proportion as the limbs are in a state of flexion.

The irritability of muscles destined to perform voluntary motions, is in a direct ratio of the number and magnitude of the nerves and arteries, distributed in their structure. The tongue receives the greatest supply of nerves, and, of all other contractile organs, is the most subject to volition.

All the muscles of living animals are constantly endeavouring to shorten themselves.

When a muscle is divided, it contracts. If a muscle be stretched to a certain extent, it contracts, and endeavours to acquire its former dimensions, as soon as the stretching cause is removed: this takes place in a dead body, in muscles cut out of the body, and also in parts not muscular, and is called by the immortal Haller *vis mortua*, and by some *vis elastica*.

It is greater in living than in dead bodies, and is called the *tone* of the muscle.

When a muscle is wounded, touched, or otherwise irritated, it contracts, independent of the will; this power is called IRRITABILITY, and, by Haller, *vis insita*; it is a property peculiar to, and inherent in, the muscles. The parts of our body which possess this property, are called irritable, as the heart, arteries, muscles, &c. to distinguish them from those parts which have no muscular fibres.

With regard to the degree of this property peculiar to various parts, the heart is the most irritable, then the stomach and intestines, the diaphragm, the arteries, veins, absorbents, and at length the various muscles follow; but the degree of irritability depends upon the age, sex, temperament, mode of living, climate, state of health, idiosyncrasy, and likewise upon the nature of the stimulus.

When a muscle is stimulated, either through the medium of the will, or any foreign body, it contracts, and its contraction is greater or less in proportion as the stimulus applied is greater or less. The contraction of muscles is different according to the purpose to be served by their contraction: thus, the heart contracts with a jerk; the urinary bladder, slowly and uniformly: puncture a muscle, and its fibres vibrate; and the abdominal muscles act slowly in expelling the contents of the rectum. Relaxation generally succeeds the contraction of muscles, and alternates with it.

The use of this property is very considerable; for upon it depend all muscular action, and the function of every viscus, except the nerves.

DISEASED APPEARANCES OF MUSCLES.

Muscles are subject to a variety of diseases, many of which affect their functions without producing any alteration in their organization.

The diseases of structure which are observed by the anatomist, *post mortem*, are, a conversion of a part or a whole muscle into bone; they are often seen considerably diminished in size, different in their colour from surrounding muscles, inflamed, suppurated, gangrenous, particularly soft, and also morbidly contracted.

Conversion into bone. A portion of a muscle is occasionally converted into bone: this is observed in the heart, in the muscular coat of arteries, and in the diaphragm. It consists in a diseased action of the nutritious arteries, by which they deposit bony or earthy particles, instead of muscular matter.

Diminution of size. A general diminution of the bulk of muscles in the body, or emaciation, is a very common occurrence: but, besides this, the anatomist occasionally finds an obvious wasting of a single muscle; as the heart, the biceps, &c. This, in most instances, arises from a deficiency of nervous power in the muscle.

Change of colour. The healthy colour of muscle is a florid or flesh colour. Muscles that have become paralytic, and muscles of dropsical subjects, are mostly of a paler hue. Besides this, a muscle has been known to have changed its colour to a pale yellow, resembling fat, whilst the surrounding ones possessed their healthy appearance.

Inflammation. This affection occurs very frequently. It consists in an increase of vascularity; the muscle appears of

a dark red colour, and is more readily torn than healthy muscles.

Abscess. These are frequently met with in anatomical investigations. It does not appear, when an abscess is found in a muscle, that any part of the muscle is converted into pus, but the fibres have the appearance of being separated from one another, and compressed together, to make way for the formation of the abscess, and very frequently they are absorbed. This, perhaps, accounts for the speedy filling of the space occupied by an immense abscess in two or three days after affording an exit to the pus: *i. e.* by the elastic and compressed muscular fibres regaining their former situation. The sides of the abscess are not formed of muscular fibre, but of a condensed cellular membrane, and sometimes a tunic of coagulable lymph, in which an immense number of small arteries are found, as is evinced by dissection, and injections. When the latter are pushed to a great extent, and the injection is successful, small vessels are found to have shot out here and there, so as to give the internal surface of the abscess a somewhat flocculent appearance. In scrofulous abscesses between muscular fibres, the coat of the abscess is mostly much thicker than in other cases.

Gangrene. In this disease, the muscle is pulpy, black, and fetid.

Flaccidity. This is occasionally observed to a considerable degree. In general it depends upon a sluggish action of the powers of life, for some time before death.

Morbid contraction. This may arise from the want of action in the antagonists, or from some other causes. It consists in a permanent contraction of the muscle to a degree beyond its healthy contraction. It is met with principally in the flexors of the legs of the aged.

BURSALOGY;

OR,

DOCTRINE OF THE BURSÆ MUCOSÆ.

Bursæ mucosæ are mucous bags, composed of a proper membrane, containing a kind of mucous fat, formed by the exhaling arteries of their internal surface. They are of different *sizes* and *firmness*, and *connected* here and there by cellular membrane, with the capsular ligaments of cavities, tendons, bones, or ligaments. Their *internal surface* is highly vascular, smooth, and shining.—SITUATION. Various.

DIVISION. Into *vaginal* and *vesicular*.

USE. To lubricate the muscles and tendons, which are very frequently in motion.*

BURSÆ MUCOSÆ OF THE HEAD.

1. *A bursa of the superior oblique muscle* of the eye, situated behind its trochlea in the orbit.—2. *The bursa of the digastricus*, situated in the internal surface of its tendon.—3. *A bursa of the circumflexus*, or tensor palati, situated between the hook-like process of the sphænoid bone and the tendon of that muscle.—4. *A bursa of the sterno-hyoideus muscle*, situated between the os hyoides and larynx.

BURSÆ MUCOSÆ SITUATED ABOUT THE SHOULDER-JOINT.

1. *The external acromial*, situated under the acromion, between the coracoid process, deltoid muscle, and capsular ligament.—2. *The internal acromial*, situated above the tendon of the infra-spinatus and teres major: it often communi-

cates with the former.—3. *The coracoid bursa*, situated near the root of the coracoid process: it is sometimes double, and sometimes triple.—4. *The clavicular bursa*, found where the clavicle touches the coracoid process.—5. *The subclavian bursa*, between the tendon of the subclavicularis muscle and the first rib.—6. *The coracobrachial*, placed between the common origin of this muscle, the biceps, and the capsular ligament.—7. *The bursa of the pectoralis major*, situated under the head of the humerus, between the internal surface of the tendon of that muscle and another bursa placed on the long head of the biceps.—8. *An external bursa of the teres major*, under the head of the os humeri, between it and the tendon of the teres major.—9. *An internal bursa of the teres major*, found within the muscle where the fibres of its tendon diverge. —10. *A bursa of the latissimus dorsi*, between the tendon of this muscle and the os humeri.—11. *The humero-bicipital bursa*, in the vagina of the tendon of the biceps. There are other bursæ mucosæ about the humerus, but their situation is uncertain.

BURSÆ MUCOSÆ SITUATED NEAR THE ELBOW-JOINT.

1. *The radio-bicipital*, situated between the tendon of the biceps, brachialis, and anterior tubercle of the radius.—2. *The cubito-radial*, between the tendon of the biceps, supinator brevis, and the ligament common to the radius and ulna. —3. *The anconeal bursa*, between the olecranon and tendon of the anconeus muscle.—4. *The capitulo-radial bursa*, between the tendon common to the extensor carpi radialis brevis, and extensor communis digitorum and round head of the radius. There are other bursæ, but as their situation varies, they are omitted.

BURSÆ OF THE INFERIOR PART OF THE FORE-ARM AND HAND.

On the inside of the wrist and hand.

1. A very *large bursa*, for the tendon of the flexor pollicis longus.—2. *Four short bursæ* on the fore-part of the tendons of the flexor sublimis.—3. *A large bursa* behind the tendon of the flexor pollicis longus, between it and the fore-part of the radius, capsular ligament of the wrist, and os trapezium.—4. *A large bursa* behind the tendons of the flexor digitorum profundus, and on the fore-part of the end of the radius, and fore-part of the capsular ligament of the wrist. In some subjects it communicates with the former.—5. *An oblong bursa*, between the tendon of the flexor carpi radialis and os trapezium. —6. *A very small bursa*, between the tendon of the flexor carpi ulnaris and os pisiforme.

On the back part of the hand and wrist.

7. *A bursa* between the tendon of the abductor pollicis longus and the radius.—8. *A large bursa* between the two extensores carpi radiales.—9. *Another* below it, common to the extensores carpi radiales.—10. *A bursa* at the insertion of the tendon of the extensor carpi radialis.—11. *An oblong bursa*, for the tendon of the extensor pollicis longus, and which communicates with 9.—12. *A bursa*, for the tendon of the extensor pollicis longus, between it and the metacarpal bone of the thumb.—13. *A bursa* between the tendons of the extensor of the fore, middle, and ring fingers.—14. *A bursa* for the extensors of the little finger.—15. *A bursa* between the tendon of the extensor carpi ulnaris and ligament of the wrist. There are also bursæ mucosæ between the musculi lumbricales and interossei.

BURSÆ SITUATED NEAR THE HIP-JOINT.

On the fore-part of the joint.

1. *The ileo-puberal*, situated between the iliacus internus, psoas magnus, and the capsular ligament of the head of the femur.—2. *The pectineal*, between the tendon of the pectineus and the thigh-bone.—3. *A small bursa* of the gluteus medius muscle, situated between it and the great trochanter, before the insertion of the pyriformis.—4. *A bursa* of the gluteus minimus muscle, between its tendon and the great trochanter.—5. *The gluteo-fascial*, between the gluteus maximus and vastus externus.

On the posterior part of the hip-joint.

6. *The tubero-ischiatic bursa*, situated between the obturator internus muscle, the posterior spine of the ischium, and its tuberosity.—7. *The obturatory bursa*, which is oblong, and found between the obturator internus and gemini muscles and the capsular ligament.—8. *A bursa of the semi-membranosus*, under its origin and the long head of the biceps femoris.—9. *The gluteo-trochanteral bursa*, situated between the tendon of the psoas muscle and the root of the great trochanter.—10. *Two glutei-femoral bursæ*, situated between the tendon of the gluteus maximus and os femoris.—11. *A bursa of the quadratus femoris*, situated between it and the little trochanter.—12. *The iliac bursa*, situated between the tendon of the iliacus internus and the little trochanter.

BURSÆ MUCOSÆ SITUATED NEAR THE KNEE-JOINT.

1. *The supra-genual*, which adheres to the tendons of the vastus and cruralis and the fore-part of the thigh-bone.—2. *The infra-genual bursa*, situated under the ligament of the pa-

tella, and often communicates with the above.—3. *The anterior genual*, placed between the tendon of the sartorius, gracilis, and semi-tendinosus, and internal and lateral ligament of the knee.—4. *The posterior genual*, which is sometimes double, and is situated between the tendons of the semi-membranosus, the internal head of the gastrocnemius, the capsular ligament, and internal condyle.—5. *The popliteal*, conspicuous between the tendon of that muscle, the external condyle of the femur, the semilunar cartilage, and external condyle of the tibia.—6. *The bursa of the biceps cruris*, between the external part of the tendon of the biceps cruris, and the external lateral ligament of the knee.

BURSÆ MUCOSÆ SITUATED IN THE FOOT.

On the back, side, and hind part of the foot.

1. *A bursa of the tibialis anticus*, between its tendon, the lower part of the tibia, and capsular ligament of the ankle.—2. *A bursa* between the tendon of the extensor pollicis pedis longus, the tibia and capsular ligament of the ankle.—3. *A bursa of the extensor digitorum communis*, between its tendons, the tibia, and ligament of the ankle.—4. *A large bursa*, common to the tendons of the peronei muscles.—5. *A bursa of the peroneus brevis*, proper to its tendon.—6. *The calcaneal bursa*, between the tendo Achillis and os calcis.

In the sole of the foot.

1. *A bursa for the tendon of the peroneus longus.*—2. *A bursa* common to the tendon of the flexor pollicis pedis longus, and the tendon of the flexor digitorum pedis communis longus profundus.—3. *A bursa of the tibialis posticus*, between its tendon, the tibia, and astragalus.—4. *Five bursæ for the flexor tendons*, which begin a little above the first joint of each toe,

and extend to the root of the third phalanx, or insertion of the tendons.

DISEASED APPEARANCES OF THE BURSÆ.

The bursæ mucosæ are very frequently found inflamed, relaxed, and containing a diseased fluid.

ANGIOLOGY;

OR,

DOCTRINE OF THE VESSELS.

Vessels are long membranous canals, which carry blood, lymph, chyle, or a secreted fluid.

Division. Into arteries, veins, absorbents, and excretory ducts.

Situation. Except the epidermis, membrana arachnoidea, and nails, every part of the body has vessels, which injections demonstrate.

ARTERIAL SYSTEM.

Arteries are elastic membranous canals, which pulsate. They always become narrower as they proceed from the heart towards the extremities.

Origin. From the ventricles of the heart; namely, the *pulmonary artery* from the right, and the *aorta* from the left ventricle: so that there are only two arteries, the rest being branches of these two.

Termination. In veins, or exhaling vessels; or they anastomose with one another.

Structure. They are composed of three membranes, called *coats* ; an *external* one, a *middle* coat, which is *muscular*, and an *inner* one, which is smooth. The arteries are nourished by their own blood-vessels, termed vasa vasorum.

Use. To convey blood from the heart to the different parts of the body, for nutrition, preservation of life, generation of heat, and the secretion of different fluids.

AORTA.

The aorta arises from the left ventricle of the heart, forms an *arch* towards the dorsal vertebræ, then *descends* through the diaphragm into the abdomen, in which it proceeds by the left side of the spine to the last vertebra of the loins, where it divides into the *two* iliac arteries. In this course it gives off, just above its origin, two *coronary* arteries to the heart, and then forms an arch.

Ossification of the coronary arteries of the heart is very common in old age. It is supposed, by some, to be the cause of *angina pectoris*. In three instances, however, where these arteries were completely become bone to the extent of two and three inches, no such disease existed.

The ascending portion of the aorta and its arch, are most frequently the seat of aneurism.

The arch of the aorta gives off three branches, which supply the head, neck, and arms with blood: these are,

I. Arteria innominata, which divides into the right carotid and right subclavian arteries.

II. The left carotid.

III. The left subclavian.

The carotid arteries, having emerged from the chest, run up along the neck, one on each side of the trachea, to the

angle of the lower jaw, where they divide into external and internal.

The external carotid has been the seat of aneurism; and, in one case, two aneurisms were found in the left carotid.

The EXTERNAL CAROTID gives off eight branches to the neck and face:

1. *Arteria thyroidea*, or *A. laryngea superior*, or *A. gutturalis superior*, which is very tortuous, supplies the thyroid gland, and gives off branches to several adjacent muscles.

2. *A. lingualis*, which lies flat upon the side of the tongue, and gives off the *ramus hyoideus, dorsalis linguæ, sublingualis*, and *ranina*.

3. *A. labialis*, called also the *external maxillary*, the *angular*, and *facial* artery: it gives off the *palatina inferior*, the *submentalis, inferior labial*, and the superior and inferior *coronary of the lips*.

4. *A. pharyngea inferior*, vel *ascendens*, which send a number of small twigs about the fauces and basis of the cranium.

5. *A. occipitalis*, from which the *posterior temporal* arises.

6. *A. posterior auris*, or *stylo-mastoid*, which furnishes the parts about the cartilages of the ear with blood, and transmits the *arteria tympani* and *stylo-mastoidea*.

7. *A. maxillaris interna*, which is extremely tortuous, and gives off—the *spinous artery*, or *arteria meningea*, or *arteria duræ matris*, to the dura mater; the *lower maxillary artery*, which is included in the lower jaw, and supplies the teeth and face; the *pterygoid arteries*, which nourish the pterygoid muscles; *two deep temporal arteries*, which lie wider than the temporal muscle. The internal maxillary then gives off a *branch*, which almost immediately divides into the *alveola*

and *infra-orbital;* then an artery to the palate, the *superior palatine;* the *upper pharyngeal,* which plays about the sphænoid sinus; and lastly, the *nasal artery,* which is transmitted through the sphæno-palatine foramen to the cavity of the nostrils.

8. *A. temporalis,* called also *superficial temporal,* which perforates the parotid gland, and sends off the *transversalis faciei,* which inosculates with the arteries of the face; the deep temporal and several branches which go to the ear, forehead, and about the temples.

This artery is frequently opened in inflammatory affections of the head.

The INTERNAL CAROTID leaves the external at the angle of the jaw, and proceeds by the par vagum and intercostal nerve to the carotid canal in the petrous portion of the temporal bone, where it is shaped like the letter *s*, and enters the cranium at the side of the sella turcica, having given off *two* very small *twigs* to the pituitary gland, and 3d 4th, and 5th pair of nerves; and when it has reached the anterior clinoid process, it sends off—

1. *Arteria ophthalmica,* which is distributed on the eye, and gives off the *arteria lachrymalis, centralis retinæ,* the *musculares,* the *ethmoidalis anterior et posterior,* and the *supra-orbitalis* vel *frontalis.*

2. *A. anterior cerebri,* which proceeds before the sella turcica, unites with its fellow, and forms the circle of Willis, from which a branch proceeds to the third venticle, septum lucidum, and the *arteria corporis callosi.*

3. *A. media cerebri,* or *fossæ Silvii,* which runs between the anterior and middle lobes of the brain, gives off the *artery of the choroid plexus,* and is lost on the middle lobe of the brain.

4. *A. communicans*, which proceeds backwards, and soon inosculates with the vertebral.

> The cerebral arteries are mostly ossified, or have opacities which are progressive to ossification, in old age. In almost every instance of apoplexy in aged people, from extravasated blood in the brain, not produced from external violence, this diseased state of the arteries exists.

The SUBCLAVIAN ARTERY arises on the right side, from the arteria innominata; and on the left, from the arch of the aorta.

> The subclavian artery is sometimes morbidly dilated. Aneurism arising by the side of the clavicle has been incautiously opened, by mistaking it for a common abscess.

Each SUBCLAVIAN gives off five branches:

1. The *internal mammary*, from which arise the *A. thymica*, *A. comes phrenici*, the *pericardiac*, and the *phrenico-pericardiac*.

2. The *inferior thyroid*, or *inferior guttural*, from which arise the *ramus thyroideus*, the *tracheal arteries*, the *ascending thyroid*, and the *transversalis humeri*.

3. *A. vertebralis*, which proceeds into the vertebral foramina, to ascend into the cavity of the cranium, where it unites upon the cuneiform process of the occipital bone with its fellow of the other side, and forms the BASILARY ARTERY, which immediately gives off the *posterior* artery of the cerebellum; it then proceeds, upon the tuberculum annulare, to give off four branches, two to the right, and two to the left, which constitute the *A. anterior cerebelli*, which branch to the crura cerebelli, the cerebellum, vermis, crura cerebri, corpora quadrigemina, pineal gland, and fourth ventricle; and the *A. posterior cerebri*, which being joined by the *communicans*,

supplies the thalami nervorum opticorum, the centrum geminum semicirculare, infundibulum, and crura fornicis, and the posterior lobes of the brain, inosculating with several arteries; it also gives off the *auditoria interna*, for the labyrinth.

4. *A. cervicalis profunda.*

5. *A. cervicalis superficialis*, both of which are distributed about the muscles of the neck.

6. *A. intercostalis superior*, which lies between the two upper ribs.

7. *A. supra-scapularis*, which sometimes arises from the *A. thyroidea*, when it is called the *transversalis humeri.*

As soon as the subclavian has arrived in the axilla, it is called the AXILLARY ARTERY, which runs into the arm, where it is termed the BRACHIAL.

The AXILLARY ARTERY gives off—

1. The *four mammary arteries*, called *thoracica superior, thoracica longior, thoracica humerina*, and *thoracica alaris* or *axillaris*, which supply blood to the muscles about the breast.

2. The *subscapularis*, which supplies the lower surface of the scapula.

3. The *circumflexa posterior.*

4. *Circumflexa anterior*, which ramify about the joint.

The BRACHIAL or HUMERAL artery gives off—

1. *Many lateral vessels.*

2. *A. profunda humeri superior*, which terminates at the outer condyle, by a branch which anastomoses with the radial recurrent.

3. *A. profunda humeri inferior*, which descends to the inner condyle, and anastomoses with the ulnar and radial.

4. *Ramus anostomoticus magnus*, which anastomoses round the elbow joint, and gives off the *A. nutritia.*

The brachial artery is frequently the seat of aneurism.

The brachial artery then becomes the ulnar, and gives off the RADIAL.

The ULNAR OF CUBITAL ARTERY sends off—

1. The *recurrent branches*, which anastomose with the ramus anastomoticus magnus.

3. *A. interossea communis.* It then sends small branches to the adjacent muscles, as it proceeds down to the wrist; just before it arrives here, it gives off *A. dorsalis ulnaris*, which goes round to the back of the little finger. At the wrist it gives off *A. palmaris profunda;* then forms a great arterial arch, called the *superficial palmar arch*, which supplies branches to the fingers.

The RADIAL gives off the *radial recurrent*, proceeds to the wrist, where the pulse is felt, and gives off the *superficialis volæ*, and then divides into the *A. dorsalis pollicis*, *A. radialis indicis*, *A. magna pollicis*, and *A. palmaris profunda.*

The radial artery is generally felt by the physician, to count the frequency of the pulse. Malformation or disease about the arm often causes the pulse in one arm to be different from that of the other; therefore both pulses should be felt.

The radial artery is frequently ossified throughout; it then feels knotty, and the pulsation is very obscure, and often wanting.

The THORACIC OF DESCENDING AORTA gives off, in the breast—

1. The *bronchial*, which nourish the lungs.

2. The *œsophagal*, which go to the œsophagus.

3. The *intercostals*, between the ribs, about ten in number, called also *aortic intercostals.*

4. The *inferior diaphragmatic*, or *phrenic.*

Within the abdomen it gives off eight branches, and is termed ABDOMINAL AORTA.

1. The *cœliac*, which divides into three branches:

1. *Arteria hepatica*, which gives off—

α. *A. duodeno-gastrica*, which sends off the *right gastro-epiploic* and the *pancreatico-duodenalis.* The latter transmits the *pilorica inferior* and the *transverse pancreatic.*

β. *A. pilorica superior hepatica.*

The hepatic artery then ramifies through the liver.

2. *A. coronaria ventriculi*, or *gastrica*, which gives off the *superior coronary* and *superior piloric arteries.*

3. *A. splenica*, from which arise the *pancreatica magna* and *pancreaticæ parvæ*, the *posterior gastric arteries*, the *left gastro-epiploic artery*, and the *vasa brevia.*

The cœliac artery has been found aneurismal.

2. The *superior mesenteric*, or *meseraic*, of which the *colica media*, *colica dextra*, and the *ileo-colica*, are branches.

3. The *renal arteries*, or *emulgents*, which are short, and divide into three or four branches in the pelvis of the kidney.

4. The *spermatic arteries*, which are very small and long, and proceed with the spermatic cord to the testicles in the male, and to the ovaria and uterine tubes in the female.

5. The *inferior meseraic*, from which arises the *left colic artery* and the *internal hæmorrhoidal.*

6. The *lumbar arteries*, which nourish the muscles and vertebræ of the loins.

7. The *middle sacral artery*, which is distributed about the sacrum.

The aorta then bifurcates, and becomes the iliac arteries. The iliac soon divides into *internal* and *external.*

Each INTERNAL ILIAC, or HYPOGASTRIC ARTERY, gives off five branches:

1. The *lateral sacral arteries*, three or four in number.

2. The *gluteal*, which ramify upon the back of the iliac

portion of the os innominatum, and supply the gluteal muscles.

3. The *ischiatic*, which turns downwards along the hip, and gives off the *coccygial artery*.

4. *Arteria pudica communis*, which is sometimes a branch of the sciatic artery; it proceeds out of the pelvis, through the sciatic notch, returns into the pelvis, and runs towards the symphysis of the pubis. In this course it gives off *branches* to the vesiculæ seminales and prostate gland; and the *lower* or *external hæmorrhoidal artery* to the anus, and then forms the *arteria perinæi*, the *arteria penis*, which proceed one on each side; and a *branch* which plunges deep into the substance of the penis.

5. The *obturatory*, which passes through the oval foramen, and is distributed on the thick muscles in the centre of the thigh. *A. uterina* is given off in females.

Each EXTERNAL ILIAC gives off—

1. The *epigastric*, which is reflected from Poupart's ligament upwards, along the abdomen; arises from the inner side of the external iliac, as the iliac is about to pass under the ligament of the thigh; it crosses obliquely upwards and inwards at the upper and outer part of the ring behind the spermatic cord in the male, and round ligament in the female; it then passes obliquely under the inferior part of the transversus to the origin of the pyramidalis; it next ascends perpendicularly at the back part, and about the middle of the rectus abdominis, and anastomoses with the internal mammary.

This artery is occasionally wounded by the trochar, in the operation of tapping an ascites, when a fatal hæmorrhage sometimes takes place. In one instance the patient died about twenty minutes after perforating the abdomen, which was found, *post mortem*, full of blood.

The improved method of tapping, however, in the *linea alba*, does away this inconvenience.

2. *Arteria circumflexa iliaca*, which runs backwards along the crista ilii.

THE EXTERNAL ILIAC then passes under Poupart's ligament, becomes the FEMORAL OR CRURAL ARTERY, and is continued along the thigh into the popliteal. In this course, after having given off the *external pudicals* and several smaller branches, it gives off, near the groin—

1 The *profunda femoris*, which gives off the *external* and *internal circumflex*; the *arteria perforans prima*, the *arteria perforans secunda magna*, the *arteria perforans tertia*, the *arteria perforans quarta*, which nourish the muscles of the thigh. The femoral artery, after giving off the *superior* and *inferior perforants*, passes under the sartorius at the middle of the inside of the thigh, proceeds downwards and inwards, and perforates the triceps to get round to the ham. About two hands breadth from the knee it gives out—

2. The *ramus anastomoticus magnus*, which ramifies about the knee-joint.

The femoral artery, having reached the ham, is called the POPLITEAL, which gives off several small branches about the joint, called *articulars*, and divides below the ham into the *tibialis antica* and *tibialis postica*.

The popliteal artery is more frequently affected with aneurism than any other.

The TIBIALIS ANTICA soon perforates the interosseous ligament, passes along the tibia over the bones of the tarsus, and then inosculates with the back arteries. In this course it gives off—

1. The *recurrent*, which inosculates with the anterior

branches of the popliteal; it then sends off small branches to neighbouring muscles as it passes down the leg.

2. *Arteria mallcolaris interna,* about the inner ankle.

3. *Arteria malleolaris externa,* about the outer ankle.

4. *Arteria tarsea,* which lies upon the bones of the tarsus.

5. *Arteria metatarsea,* to the tendons of the peronei muscles.

6. *Dorsalis externa hallucis,* which runs along the metatarsal bone of the great toe.

The TIBIALIS POSTICA passes along the back part of the tibia, goes round the inner ankle, and divides at the heel into the two plantar arteries. In this course it sends off—

1. *Arteria nutritia tibiæ,* which gives branches to the popliteus, soleus, and tibialis anticus muscles, before it enters the bone.

2. The *fibular* or *peroneal and many small branches,* as it passes downwards.

3. *Arteria plantaris interna,* which runs along the inner edge of the sole of the foot, and sends off *four branches* about the foot.

4. *Arteria plantaris interna,* which sforms an arch and inosculates with the anterior tibial artery, and gives off the *digital branches* to the toes.

PULMONARY ARTERY.

The *pulmonary artery* arises from the right ventricle of the heart, and conveys the dark-coloured blood into the lungs, which is returned to the heart, of a florid colour, by the veins. It does not convey this blood into the lungs for their nutrition, but to receive from the air in the lungs a *certain principle,* necessary for the continuance of life, and which the arterial blood distributes to every part of the body. The

pulmonary artery soon divides into a *right* and *left*;—the right going to the right lung, and the left to the left lung; where they divide into innumerable ramifications, and form a beautiful *net-work*, or *plexus of vessels*, upon the air-vesicles, called the *rete mirabile*, and then terminate in the pulmonary veins, which convey the blood, now become florid, to the left side of the heart.

The pulmonary artery seldom becomes ossified; and is very rarely attacked with aneurism. One case, however, of aneurism of the pulmonary artery, the author has seen, which was of the size of his fist.

ACTION OF ARTERIES.

The arteries, by the impulse of the blood from the ventricles of the heart, are dilated and irritated, and by means of their muscular coat contract upon the blood, and thus propel it to the glands, muscles, bones, membranes, and every part o the body, for their nutrition and the various secretions; and then into the veins. This dilatation and contraction is called the PULSE, which is perceptible in the trunks and branches of the arteries, but not in the capillary vessels, except when inflammation is going on.

DISEASED APPEARANCE OF THE ARTERIES.

The diseases of arteries, which are detected by the anatomist *post mortem*, are, aneurism, white patches, ossification, inflammation, and redness of the internal membrane.

VENAL SYSTEM.

Veins are membranous canals which do not pulsate; they gradually become larger as they advance towards the heart, in which they terminate, and bring back the blood from the arteries.

Origin. From the extremities of the arteries by anastomosis.

Termination. The termination of all the veins is in the auricles or the heart.

Division. Into trunks, branches, ramuli, &c.

Situation. They run by the sides of arteries, but more superficially.

Structure. Veins, like arteries, are composed of three membranes, but they are semi-transparent, and more delicate.

Valves. These are thin semilunar membranous folds, which are found in most veins, and prevent the blood in the vein from being pressed backwards out of its natural course.

The blood is returned from every part of the body into the right auricle:—the vena cava superior receives it from the head, neck, thorax, and superior extremities; the vena cava inferior, from the abdomen and inferior extremities; and the coronary vein receives it from the coronary arteries of the heart.

VENA CAVA SUPERIOR.

This vein terminates in the superior part of the right auricle, into which it evacuates the blood from

The *right* and *left subclavian veins*, and the *vena azygos*.

The right and left subclavian veins receive the blood from the head and upper extremities, in the following manner:

The veins of the fingers, called *digitals*, receive their blood from the digital arteries, and empty it into—

1. The *cephalic of the thumb*, which runs on the back of the hand along the thumb, and evacuates itself into the external radial.

2. The *salvatella*, which runs along the little finger, unites with the former, and empties its blood into the internal and external cubital veins.

This vein, the *salvatella*, is frequently opened to take away blood; the hand should be soaked for some time before in warm water, and a ligature put round the wrist.

At the bend of the fore-arm are three veins, called the great cephalic, the basilic, and the median.

The GREAT CEPHALIC runs along the superior part of the fore-arm, and receives the blood from the external radial.

The BASILIC ascends on the under-side, and receives the blood from the external and internal *cubital veins*, and some branches which accompany the brachial artery, called *venæ satellitum*.

The MEDIAN is situated in the middle of the fore-arm, and arises from the union of several branches. It is divided into two branches; the *median cephalic*, and the *median basilic*.

Either of these veins may be opened with the greatest ease; and it is at the bend of the arm that blood is most frequently taken from one of these branches.

Thrombus is nothing more than blood that escapes from the bleeding vein into the cellular membrane;—a mere ecchymosis, or extravasation.

When the lancet penetrates the vein, and perforates the artery that lies underneath at the same time, the arterial blood rushes into the vein. This communication between the artery and vein continues ever after, and

the vein becomes dilated and serpentine, from the continual influx of the blood from the artery: and this constitutes what is called a *varicose aneurism*.

These three veins all unite above the bend of the arm, and form—

The BRACHIAL VEIN, which receives all their blood, and is continued into the axilla, where it is called

The AXILLARY VEIN. This receives also the blood from the scapula, and superior and inferior parts of the chest, by the *superior* and *inferior thoracic vein*, the *vena muscularis*, and the *scapularis*.

The axillary vein then passes under the clavicle, where it is called the SUBCLAVIAN, which unites with the external and internal jugular veins, and the vertebral vein which brings the blood from the vertebral sinuses; it receives also the blood from the *mediastinal*, *pericardiac*, *diaphragmatic*, *thymic*, *internal mammary*, and *laryngeal* veins; and then unites with its fellow, to form the vena cava superior, or, as it is sometimes called, *vena cava descendens*.

The blood from the external and internal parts of the head and face is returned in the following manner into the external and internal jugulars, which terminate in the subclavians:

The *frontal*, *angular*, or *facial*, *temporal*, *auricular*, *sublingual*, and *occipital* veins receive the blood from the parts after which they are named; these all converge to each side of the neck, and form a trunk called the EXTERNAL JUGULAR.

The external jugular may be opened with more facility than the veins in the arm. In ophthalmias it gives speedier and more certain relief, and in many diseases of the head is preferable to taking blood from the arm. The application of a bandage under the arm is useless; simple pressure with the finger is far better.

The blood from the brain, cerebellum, medulla oblongata, and membranes of these parts, is received into the lateral sinuses, or veins of the dura mater, one of which empties its blood through the foramen lacerum in basi cranii into the INTERNAL JUGULAR, which descends in the neck by the carotid arteries, receives the blood from the *thyroideal* and *internal maxillary veins*, and empties itself into the subclavians within the thorax.

The vena azygos receives the blood from the *bronchial superior œsophageal*, *vertebral*, and *intercostal veins*, and empties it into the superior cava.

VENA CAVA INFERIOR.

The vena cava inferior is the trunk of all the abdominal veins, and those of the lower extremities, from which parts the blood is returned in the following manner:

The veins of the toes, called the *digital veins*, receive the blood from the digital arteries, and form on the back of the foot three branches, one on the great toe, called the *cephalic*; another, which runs along the little toe, called the *vena saphena*; and one on the back of the foot, *vena dorsalis pedis*; and on the sole of the foot they evacuate themselves into the *plantar veins*.

The three veins in the upper part of the foot coming together above the ankle, form the *anterior tibial*; and the plantar veins, with a branch from the calf of the leg, called the *sural vein*, form the *posterior tibial*: a branch also ascends in the direction of the fibula, called the *peroneal vein*. These three branches unite before the ham, into one branch, the *subpopliteal vein*, which ascends through the ham, carrying all the blood from the foot; it then proceeds upon the ante-

rior part of the thigh, where it is termed the *crural* or *femoral vein*, receives several muscular branches, and passes under Poupart's ligament into the cavity of the pelvis, where it is called the EXTERNAL ILIAC.

The veins of the leg and thigh are more frequently found in a varicose state than any other veins, especially in females.

The arteries which are distributed about the pelvis, evacuate their blood into the *external hæmorrhoidal veins*, the *hypogastric veins*, the *internal pudendal*, the *vena magna ipsius penis*, and *obturatory veins*, all of which unite in the pelvis, and form the INTERNAL ILIAC VEIN.

The exernal iliac vein receives the blood from the external pudendal veins, and then unites with the internal iliac at the last vertebra of the loins, and forms the VENA CAVA INFERIOR, or ASCENDENS, which ascends on the right side of the spine, receiving the blood from the *sacral, lumbar, right spermatic veins*, and the *vena cava hepatica;* and, having arrived at the diaphragm, it passes through the right foramen, and enters the right auricle of the heart, into which it evacuates all the blood from the abdominal viscera and lower extremities.

The vena cava inferior at its very commencement has been found morbidly enlarged, and filled with a coagulum; as in aneurism of the arteries.

VENÆ CAVÆ HEPATICÆ.

These veins ramify in the substance of the liver, and bring the blood into the vena cava inferior from the branches of the—

VENA PORTÆ:

A great vein which carries the blood from the abdominal viscera into the substance of the liver. The trunk of this vein, about the fissure of the liver, in which it is situated, is *divided* into the hepatic and abdominal portions. The *abdominal portion* is composed of the *splenic*, *meseraic*, and *internal hæmorrhoidal veins*. These three venous branches carry all the blood from the stomach, spleen, pancreas, omentum, mesentery, gall-bladder, and the small and large intestines, into the *sinus* of the vena portæ. The *hepatic portion* of the vena portæ enters the substance of the liver, divides into innumerable ramifications, which secrete the bile, and the superfluous blood passes into corresponding branches of the *venæ cavæ hepaticæ*.

ACTION OF VEINS.

Veins do not pulsate; the blood which they receive from the arteries flows through them very slowly, and is conveyed to the right auricle of the heart, by the contractility of their coats, the pressure of the blood from the arteries, called the *vis à tergo*, the contraction of the muscles, and respiration; and it is prevented from returning back in the vein by the valves, of which there are a great number.

DISEASED APPEARANCES OF VEINS.

These are, redness of the internal membrane, aneurism, obliteration, air in the veins, varix, and abscess.

ABSORBENT SYSTEM.

Absorbents are very thin and pellucid vessels, which carry the lymph from every part of the body; substances applied to the surface of the body, and the chyle from the intestines, into the thoracic duct.

Division. Into *lacteals* and *lymphatics*. They are called *lacteals* in the intestines and mesentery, and *lymphatics* in every other part.

Figure. Branching, becoming broader as they proceed towards their termination.

Valves. Numerous, giving them a knotted appearance.

Situation. It is supposed that they exist in every part of the body, although they have not been as yet detected in some; as the brain, &c.

Origin. The cellular membrane, the viscera, the excretory ducts of the viscera, the external surface and every part of the body.

Termination. In the thoracic duct, or subclavian vein. The ancient opinion of lymphatics terminating in neighbouring veins, is now justly exploded, and supported only by the *ipse-dixit* of a few.

Lymphatic or conglobate glands are situated every where in the course of the lymphatics.

Structure. They consist of tender, pellucid, strong tunics.

Use. The use of the *absorbents* is to carry back the lymph from different parts into the blood; to convey the chyle from the intestines to the thoracic duct, where it is mixed and diluted by the lymph; and to absorb substances from surfaces and parts on which they originate.

LACTEALS.

The lacteal absorbents, forming a part of the mesentery, are considered in the *Splanchnology*.

LYMPHATICS.

The lymphatic absorbents exist in every the minutest part of our body: this is proved by experiments, though their existence cannot be demonstrated to the eye. They are divided into those of the head and neck, upper and lower extremities, and those of the viscera.

LYMPHATICS OF THE HEAD AND NECK.

Absorbents are found on the scalp and about the viscera of the neck, which unite into a considerable *branch* that accompanies the jugular vein. Absorbents have not been detected in the human brain; yet there can be no doubt of there being such vessels. It is probable that they pass out of the cranium through the *canalis caroticus* and *foramen lacerum in basi cranii*, on each side, and join the above *jugular branch*, which passes through some glands as it proceeds into the chest to the angle of the subclavian and jugular vein.

LYMPHATICS OF THE UPPER EXTREMITIES.

The absorbents of the upper extremities are divided into superficial and deep-seated. The *superficial absorbents* ascend under the skin in every direction to the wrist, from whence a *branch* proceeds upon the posterior surface of the fore-arm to the head of the radius, over the internal condyle of the humerus, up to the axilla, receiving several branches as it pro-

ceeds. Another *branch* proceeds from the wrist along the anterior part of the fore-arm, and forms a *net-work*, with a *branch* coming over the ulna from the posterior part, and ascends on the inside of the humerus to the glands of the axilla.

The *deep-seated absorbents* accompany the larger blood-vessels, and pass through two glands about the middle of the humerus, and ascend to the glands of the axilla. The superficial and deep-seated absorbents having passed through the axillary glands, form *two trunks*, which unite into *one*, to be inserted with the jugular absorbents into the thoracic duct, at the angle formed by the union of the subclavian with the jugular vein.

LYMPHATICS OF THE INFERIOR EXTREMITIES.

These are also superficial and deep-seated. The *superficial ones* lie between the skin and muscles. Those of the toes and foot form a *branch*, which ascends upon the back of the foot over the tendon of the cruræus anticus, forms, with other branches, a *plexus* above the ankles, then proceeds along the tibia over the knee, sometimes passes through a gland, and proceeds up the inside of the thigh to the subinguinal glands.

The *deep-seated* absorbents follow the course of the arteries, and accompany the femoral artery; in which course they pass through some glands in the leg and above the knee, and then proceed to some deep-seated subinguinal glands.

The absorbents from about the external parts of the pubis, as the penis, perinæum, and from the external parts of the pelvis, in general proceed to the inguinal glands. The sub-inguinal and inguinal glands send forth several branches, which pass through the abdominal ring into the cavity of the abdomen.

LYMPHATICS OF THE ABDOMINAL AND THORACIC VISCERA.

The absorbents of the lower extremities accompany the external iliac artery, where they are joined by many branches from the *uterus*, *urinary bladder*, *spermatic cord*, and some branches accompanying the internal iliac artery: they then ascend to the sacrum, where they form a *plexus*, which proceeds over the psoas muscles, and meeting with the lacteals of the mesentery, form the *receptaculum chyli*, which, in adults, is about the size of a large pea, and is the commencement of the

THORACIC DUCT.

This is the trunk of the absorbents, it is of a serpentine form, about the size of a crow-quill: it commences from an oval reservoir or membranous bag called the *receptaculum chyli*, lying on the body of the first lumbar vertebra behind the right crus of the diaphragm, formed by the junction of the lymphatics of the lower extremities and the lacteals. From this sac it passes between the crura of the diaphragm, and beneath the right side of the aorta, and ascends between that vessel and the vena azygos; it then passes behind the œsophagus and curvature of the aorta to the left side, till behind the left carotid artery, and on that side of the œsophagus it ascends to the first or second dorsal vertebra; then, leaving the carotid, makes a circular turn and divides: uniting again almost immediately, it descends behind the internal jugular vein, to the left of which it enters the angle formed by the subclavian and jugular veins; at the entrance a semilunar valve covers the greatest part of its orifice. In this course it receives—

The *absorbents of the kidneys,* which are superficial and deep-seated, and unite as they proceed towards the thoracic duct.

The *absorbents of the spleen,* which are upon its peritoneal coat, and unite with those of the pancreas.

A *branch* from a plexus of vessels passing above and below the duodenum, and formed by the absorbents of the *stomach,* which come from the lesser and greater curvature, and are united about the pylorus with those of the pancreas and *liver,* which converge from the external surface and internal parts towards the porta of the liver, and also by several branches from the *gall-bladder.*

The absorbents of the *diaphragm, pleura, lungs, heart,* and *pericardium.*

DISEASED APPEARANCES OF ABSORBENTS.

Lymphatics morbidly distended with lymph—inflammation of the lymphatics—scrofulous thickening of the coats of the lymphatics—cancerous thickening of the coats of the lymphatics—lymphatics enlarged and filled with scrofulous or sebaceous matter.

PHYSIOLOGY OF ABSORPTION.

Absorption is the taking up of substances which are applied to the mouths of absorbing vessels ; thus the chyle is absorbed from the intestinal tube by the lacteals, the vapour of circumscribed cavities, and of the cells of the cellular membrane, by the lymphatics of those parts; and thus mercury and

other substances are taken into the system, when rubbed on the skin. Absorption is less active externally than internally, and is performed with greater celerity on those external parts the surface of which is thinly covered with epidermis, as the lips, glans penis, &c. From the numerous anastomoses of absorbents, metastases may be accounted for; liquors absorbed by these vessels in one organ, may be carried into another without passing through the circulation.

The principle by which this absorption takes place, is a power inherent in the mouths of absorbing vessels, a vis insita, dependent on the high degree of irritability of their internal membrane, by which the vessels contract and propel the fluid forwards. Hence the use of this function appears to be of the utmost importance, viz. to supply the blood with chyle; to remove the superfluous vapour of circumscribed cavities, otherwise dropsies, as hydrocephalus, hydrothorax, hydrocordis, ascites, hydrocele, &c. would constantly be taking place; to remove the superfluous vapour from the cells of the cellular membrane dispersed throughout every part of the body, that anasarca may not take place; to remove the hard and soft parts of the body; and to convey into the system medicines which are applied to the surface of the body.

SANGUIFICATION.

Sanguification appears to be nothing more than the mixing, by the action of the blood-vessels, of the chyle with the blood; for as it passes from the subclavian vein, it changes its colour, and, when it has reached the heart, cannot be distinguished from the mass of circulating blood.

NEUROLOGY;

OR,

DOCTRINE OF THE NERVES.

Nerves are long, whitish, pulpy cords, composed of bundles or fasciculi of fibres, which serve for sensation.

ORIGIN. The cerebrum, cerebellum, medulla oblongata and medulla spinalis. Those which arise from the cerebrum cerebellum, and medulla oblongata, are termed *cerebral nerves;* and those from the spinal marrow, *spinal nerves.* All the other nerves of the body arise from these.

TERMINATION. The organs of sense, viscera, vessels, muscles, bones, &c.

DIVISION. Into trunks, branches, ramuli, capillary fibres, papillæ, nervous plexuses, and ganglions, or knots.

NUMBER. Thirty-nine pair;—nine pair of cerebral nerves, and thirty pair of spinal. The *nine pair of cerebral nerves,* are, 1. The olfactory. 2. The optic. 3. Oculorum motorii. 4. The pathetic, or trochleatores. 5. The trigemini, or divisi. 6. The abducent. 7. The auditory and facial. 8. The par vagum, or great sympathetic nerves. 9. The lingual pair.

The *thirty pair of spinal nerves* are divided into eight pair of cervical, twelve pair of dorsal, five pair of lumbar, and five pair of sacral nerves.

All the cerebral and spinal nerves are covered at their origin by the pia mater, and at their egress from the skull and spine by the dura mater, which last constitutes the vagina of the nerve, in the form of a firm cellular texture; but when the nerve arrives at its place of destination, it appears in a soft pulpy state.

The *ganglions*, or knots of nerves, are whitish red bodies, of various size and figure, somewhat harder than a nerve found in the course of many of the nerves. They consist of medullary and fibrous substance: their use is not known.

Nerves receive a covering from the membranes of the ain, which constitutes their vagina, and are supplied with teries and veins from the neighbouring blood-vessels.

When nerves are woven together like a net, they form a *plexus*: these are common about the abdominal viscera.

USE. Nerves are the organs of sensation, constituting the rgans of the five external senses,—touch, sight, hearing, nelling, and taste; nor can the motion of muscles be performed without the nervous influence.

NERVES OF THE BRAIN.

Under this division, anatomists consider such as proceed immediately from the brain, arise in pairs, that is, one from each side of the brain, and are therefore commonly called fter their order, as first, second, third pair of nerves, &c. nd as they are all subservient to some specific purpose, they ve received appropriate appellations, as olfactory, optic, &c.

OLFACTORY NERVES.

The *first pair*, or *olfactory nerves*, arise from the corpora striata, in a triangular form; pass forwards, becoming flatter er the sphænoid and frontal bones, one to each side of the ista galli, where they are flattened and enlarged, and send wn a number of branches, which go through the cribriform

foramen of the ethmoid bone, to be distributed on the pituitary membrane of the nose.

USE. They form the organ of smelling on the pituitary membrane of the nose.

A want of energy in these nerves gives rise to *anosmia*, or want of smell, which is mostly symptomatic.

OPTIC NERVES.

The *second pair*, or *optic nerves*, arise from the thalami nervorum opticorum, turn round the crura cerebri, becoming thinner, decussate each other, or are united together, then pass through the foramina optica, and perforate the bulb of the eye, and in it form the *retina*.

The optic nerves being the organs of sight, most of their diseases produce blindness. A diseased appearance, consisting of a change of colour into a brown, and a pulpiness, have been sometimes noticed about the junction of these nerves.

NERVI OCULORUM MOTORII.

The *third pair*, or *oculorum motorii*, arise from the crura cerebri, near the pons Varolii, pass forwards towards the top of the petrous portion of the temporal bone, where they perforate the dura mater, and proceed to the orbital fissure, to be inserted into the muscles of the bulb of the eye, which they move. There is sometimes a branch given off from this nerve to join a branch of the fifth pair in the orbit, and form a ganglion, which is termed the LENTICULAR or OPHTHALMIC GANGLION, from whence small branches proceed to the choroid membrane of the eye, the iris, uvea, and tunica sclerotica.

NERVI PATHETICI.

The *fourth pair*, or the *pathetic nerves*, arise from the crura of the cerebellum laterally, pass forward, pierce the dura mater below the third pair, and proceed with them through the orbital fissure to be inserted into the trochlearis muscle of the eye.

NERVI TRIGEMINI.

The *fifth pair*, or *trigemini*, arise from the anterior part of the crura of the cerebellum, and are divided within the cavity of the cranium into three branches, viz. the ophthalmic or orbital, and the superior and inferior maxillary.

The ORBITAL nerve gives off a *branch*, near its origin, which unites with a branch of the sixth pair, to form the great intercostal nerve; it then divides into three branches:

1. The *frontal*, which goes through the superciliary foramen to the muscles and integuments of the forehead.
2. The *lachrymal*, which goes to the lachrymal gland.
3. The *nasal*, which goes forwards to the inner canthus of the eye, where it gives off a branch or two, then returns into the cranium, and passes through the cribriform plate of the ethmoid bone, and is distributed on the pituitary membrane.

The SUPERIOR MAXILLARY nerve goes through the foramen rotundum, and is divided into—

1. The *sphæno-palatine*, which goes through the sphæno-palatine foramen, sends twigs to the internal pterygoid muscle, then enters the cavity of the nostrils, and is lost on the Eustachian tube, soft palate, and pituitary sinus of the sphænoid bone.

2. The *posterior alveolar* branch, which descends through the foramen by the last grinder, and is distributed to the molares.

3. The *infra-orbital* nerve, which goes through the infra-orbital foramen, and is distributed on the muscles of the cheek, nose, lips, and communicates with the facial nerve.

4. The *palatine branch*, or *palato-maxillary*, which goes through the foramen palatinum posterius, and sends branches to the velum palati, and roof of the mouth.

The INFERIOR MAXILLARY goes out of the cranium, through the foramen ovale, giving branches to the muscles and glands in its course, and to the facial nerve, and divides as it passes over the pterygoid muscle, into—

1. The *internal lingual*, which is connected with the chorda tympani, and supplies the sublingual glands and contiguous muscles, but more especially the tongue.

2. The more proper *inferior maxillary*, which goes into the canalis mentalis of the lower jaw, gives a branch to each tooth, and comes out again to supply the lower lip and chin.

The distributions of the fifth pair of nerves on the face, are subject to a singular disease, the *tic doloureux*, which is occasionally relieved by dividing the nerves, and hitherto by no other means.

NERVI ABDUCENTES.

The *sixth pair*, or *abducent nerves*, arise from the posterior part of the pons Varolii, proceed forwards, perforate the dura mater, and send off some branches near the sella turcica, which unite with branches of the ophthalmic nerve of the fifth pair, to form the great intercostal nerve; they then accompany the third and fourth pair through the orbital fissure, and are distributed on the recti externi muscles of the bulb of the eye.

NERVI AUDITORII.

The *seventh pair*, or *auditory nerves*, as they are commonly called, originate on each side by two branches, the portio dura, and portio mollis.

The PORTIO DURA is, in fact, a nerve of the face, and is therefore, with more propriety, called the FACIAL NERVE: it arises from the fourth ventricle of the brain, passes through the *aquæductus Fallopii*, in the petrous portion of the temporal bone, where it gives off the *chorda tympani*, which joins the lingual of the fifth pair, proceeds through the stylo-mastoid foramen, perforates the parotid gland, and then divides into seven or eight branches, which constitute the PES ANSERINUS, supply the ear, parotid gland, and muscles of the face, and communicate with the branches of the fifth pair on the face.

The PORTIO MOLLIS, or auditory nerve, arises from the medulla oblongata, and the fourth ventricle, enters the internal auditory passage, and is distributed by innumerable branches on the membrane of the cochlea, vestibulum, forming the immediate organ of hearing.

PAR VAGUM.

The *eighth pair*, or *par vagum*, arise by several branches, partly from the medulla oblongata, and partly from the fourth ventricle, behind the pons Varolii. It is connected, at its origin, with the *accessory nerves of Willis*, which ascend through the great occipital foramen, from the fifth cervical nerve: these nerves proceed together through the foramen lacerum in basi cranii. The accessory nerves then separate from the par vagum, and vanish in the sterno-cleido-mastoideus, and cucullaris muscles: the par vagum

then gives off branches in the neck to the tongue, larynx, and thyroid gland, from which parts they acquire names, and then descends into the cavity of the thorax, where it gives off—

1. The RIGHT and LEFT RECURRENT: the former arises on the right side, near the subclavian artery, which it surrounds, and then returns upwards to the thyroid gland: the latter arises under the arch of the aorta, which it surrounds, and then ascends to the œsophagus. Both nerves are lost in the muscles of the larynx and pharynx.

2. *Several branches* which proceed to the superior part of the pericardium, to form, with other nerves, the *cardiac plexus*, which sends branches to the heart.

3. The par vagum then extends on the posterior surface of the lungs, on each side, and gives off some *branches*, which, with others from the cardiac plexus and recurrent nerves, form a RIGHT and LEFT PULMONIC PLEXUS, which supplies the lungs and trachea.

4. Both trunks of the par vagum then descend with the œsophagus, and give off many *ramifications*, which form the ŒSOPHAGEAL PLEXUS, from which the œsophagus and adjoining parts are supplied.

5. Having passed the diaphragm with the œsophagus, they form, about the cardia, two STOMACHIC PLEXUSES: the anterior is expanded over the anterior surface of the stomach, and its greater curvature; the posterior over the posterior surface and lesser curvature, and it transmits also branches to the liver, pancreas, and diaphragm.

6. The par vagum also sends some *branches* to unite with the great intercostal, and thus concurs in forming the *hepatic*, *splenic*, and *renal plexuses*.

NERVI LINGUALES.

The *ninth*, or *lingual pair* of nerves, arise from the medulla oblongata, between the corpora olivaria, and pyramidalia; pass out of the skull, through the foramina condyloidea anteriora, and communicate with the par vagum, and first pair of cervical nerves; they then proceed forwards, between the jugular vein and carotid artery, to be distributed on the muscles of the tongue and os hyoides.

Thus it appears that the olfactory and ophthalmic nerves, and the oculorum motorii, arise from the cerebrum; the trochleatores and trigemini, from the cerebellum; and the auditory, par vagum, and linguales, from the medulla oblongata.

NERVES OF THE MEDULLA SPINALIS.

Those nerves are called *spinal*, which pass out through the lateral or intervertebral foramina of the spine.

Each nerve arises by two twigs, which unite, and form a small ganglion, before the nerve leaves the vertebral canal. They all receive a covering from the dura and pia mater, which accompanies them to their ultimate terminations.

The spinal nerves are divided into *cervical*, *dorsal*, *lumbar*, and *sacral* nerves.

CERVICAL NERVES.

The *cervical* nerves are *eight* pairs, and are to be distinguished from the nerves which pass from the brain along the neck.

The *first* are called the OCCIPITAL; they arise from the beginning of the spinal marrow, pass out between the margin of the occipital foramen and atlas, form a ganglion on its

transverse process, and are distributed about the occiput and neck.

The *second* pair of cervical nerves send a branch to the accessory nerve of Willis, and proceed to the parotid gland, and external ear.

The *third* cervical pair supply the integuments of the scapula, cucullaris, and triangularis muscles, and send a branch to assist in forming the diaphragmatic nerve.

The *fourth pair* sends off two branches; one to unite with branches from the second and fifth cervical pairs, and this union forms the accessory nerve of Willis; the other to unite with a branch from the third and fifth cervical, which forms the diaphragmatic nerve.

The *fourth*, *fifth*, *sixth*, *seventh*, and *eighth* pairs all converge to form the *brachial plexus*, from which arise the accessory nerves of Willis, the diaphragmatic nerve, and the nerves of the upper extremities, which are therefore to be considered here.

ACCESSORY NERVE OF WILLIS.

This arises on both sides of the neck, from the union of branches from the second, fourth, and fifth pairs, proceeds upwards through the great occipital foramen to the medulla oblongata, where it joins the par vagum, and accompanies it out of the skull, through the foramen lacerum in basi cranii, and then leaves it to be distributed on the cucullaris and sterno-cleido-mastoideus muscles.

DIAPHRAGMATIC NERVE.

The diaphragmatic nerve, which is also called the *phrenic* nerve, is formed in the neck by the union of the branches from the third, fourth, and fifth cervical pairs, and by a branch

coming from the first pair of dorsal nerves, and another from the great intercostal. From the neck it passes between the clavicle and subclavian artery into the thorax, and descends along the pericardium to the upper surface of the diaphragm, where it divides into numberless branches, which are lost in its substance. The *right* phrenic runs opposite to the superior cava and right auricle; while the *left* curves over the pericardium, at the apex of the heart.

NERVES OF THE UPPER EXTREMITIES.

All the nerves of the upper extremities arise from the *brachial plexus*, situated in the neck, which is chiefly constituted by the union of the five lowermost cervical nerves, and a large branch of the first pair of the back. Several small branches are first given off to contiguous parts, and then—

1. The AXILLARY NERVE, which sometimes arises from the radial nerve. It runs backwards and outwards around the neck of the humerus, and ramifies in the muscles of the scapula.

2. The EXTERNAL CUTANEAL, which perforates the coraco-brachialis muscle, to the bend of the arm, where it accompanies the median vein as far as the thumb, and is lost in its integuments.

3. The INTERNAL CUTANEAL, which descends on the inside of the arm, where it bifurcates. From the bend of the arm, the anterior branch accompanies the basilic vein, to be inserted into the skin of the palm of the hand; the posterior branch runs down the internal part of the fore arm, to vanish in the skin of the little finger.

4. The MEDIAN NERVE, which accompanies the brachial artery to the cubit, then passes between the brachialis internus, pronator rotundus, and the perforatus, and perforans, un-

der the ligament of the wrist to the palm of the hand, where it sends off branches, in every direction, to the muscles of the hand, and then supplies the *digital nerves*, which go to the extremities of the thumb, and fore and middle fingers.

5. The ULNAR NERVE, which descends between the brachial artery and basilic vein, between the internal condyle of the humerus, and the olecranon, and divides in the fore-arm, into an *internal* and an *external* branch. The former passes over the ligament of the wrist and sesamoid bone, to the hand, where it divides into three branches, two of which go to the ring and little finger, and the third forms an arch towards the thumb, in the palm of the hand, and is lost in the contiguous muscles, The latter passes over the tendon of the extensor carpi ulnaris, and back of the hand, to supply also the two last fingers.

6. The SPIRAL, OF RADIAL NERVE, which sometimes gives off the axillary nerve. It passes backwards, about the os humeri, descends on the outside of the arm, between the brachialis externus and internus muscles, to the cubit; then proceeds between the supinator longus and brevis, to the superior extremity of the radius, giving off various branches to adjacent muscles. At this place it divides into two branches; one goes along the radius, between the supinator longus, and radialis internus, to the back of the hand, and terminates in the interosseous muscles, the thumb, and three first fingers; the other passes between the supinator brevis, and head of the radius, and is lost in the muscles of the fore-arm.

DORSAL NERVES.

The *dorsal nerves* are twelve pairs in number. The *first* pair gives off a branch to the brachial plexus. All the dorsal nerves are distributed to the muscles of the back, intercostals,

serrati, pectoral, abdominal muscles, and diaphragm. The five inferior pairs go to the cartilages of the ribs, and are called *costal.*

LUMBAR NERVES.

The five pair of *lumbar nerves* are bestowed about the loins and its muscles, the skin of the abdomen and loins, scrotum, ovaria, and diaphragm. The second, third, and fifth pair unite, and form the *obturator nerve,* which descends over the psoas muscle into the pelvis, and passes through the foramen thyroideum to the obturator muscle, triceps, pectineus, &c.

The third and fourth, with some branches of the second pair, form the CRURAL NERVE, which passes under Poupart's ligament with the femoral artery, sends off branches to the adjacent parts, and descends in the direction of the sartorius muscle, to the internal condyle of the femur, from whence it accompanies the saphena vein to the internal aukle, to be lost in the skin of the great toe.

The fifth pair are joined to the first pair of the sacral nerves.

SACRAL NERVES.

The posterior sacral nerves go through the foramina at the back of the sacrum, to supply the gluteal muscles and integu. ments.

There are five pair of *anterior sacral nerves* anteriorly, all of which arise from the *cauda equina,* or termination of the medulla spinalis; so called from the nerves resembling the tail of a horse. The four first pair give off branches to the pelvic viscera, and are afterwards united to the last lumbar, to form a large *plexus,* which gives off—

The ISCHIATIC NERVE, the largest in the body, which immediately at its origin sends off branches to the bladder, rec-

tum, and parts of generation; proceeds from the cavity of the pelvis, through the ischiatic notch, between the tuberosity of the ischium and great trochanter, to the ham, where it is called the POPLITEAL NERVE. In the ham it divides into two branches:—

1. The PERONEAL, which descends on the fibula, and distributes many branches to the muscles of the leg and back of the foot.

2. The TIBIAL, which penetrates the gastrocnemii muscles to the internal ankle, passes through a notch in the os calcis to the sole of the foot, where it divides into an *internal* and *external plantar* nerve, which supply the muscles and aponeurosis of the foot and the toes.

GREAT INTERCOSTAL NERVES.

The great intercostal, or sympathetic nerve, arises in the cavity of the cranium, from the union of a branch of the sixth with a recurrent twig of the second branch of the fifth pair. It passes out of the cranium through the carotid canal, and descends on the sides of the cervical, dorsal, and lumbar vertebræ and sacrum, in which course it is joined by filaments from all the spinal nerves, forming small ganglions at their junctions.

In the neck it forms only three *ganglions*, which are called *cervical*.

1. The *uppermost* is situated upon the second vertebra, behind the pharynx; it sends branches which concur in forming the pulmonic and cardiac plexuses; and several other twigs, which unite with the lingual nerve, the par vagum, and the two other ganglions.

2. The *middle ganglion*, which is situated on the fourth cervical vertebra.

2. The *lowermost ganglion*, which is the least, and placed on the last cervical vertebra. A branch goes off from it, and surrounds the subclavian artery and several others, which unite with other branches from the par vagum, and form the *cardiac plexus*.

The trunk of the great intercostal then descends behind the subclavian artery, by the sides of the transverse processes of the dorsal vertebræ, through the cavity of the chest, receiving two branches from each of the dorsal nerves coming from the spinal marrow, as it passes along, and forming as many small ganglions. It then quits the side of the vertebræ, accompanies the aorta, and having reached the sacrum, it produces several ganglions, with the spinal branches coming from this part; and, lastly, the great intercostal is reflected inwards, about the os coccygis, and joins its fellow of the opposite side. Having thus described the course of this nerve, so justly termed the great sympathetic, it still remains to enumerate the several abdominal plexuses which arise from it,—for the viscera of the abdomen are all supplied from the great intercostal.

The fifth dorsal ganglion of the intercostal sends off a nerve into the thorax; the third dorsal ganglion also sends off a nerve; a nerve proceeds from the seventh dorsal ganglion; one also goes from the eighth ganglion; and another nerve is given off from the ninth and tenth, or sometimes from the eleventh dorsal ganglion. These five branches, given off by the *dorsal ganglia*, descend in the thorax, in the course of the vertebræ, and pass through the diaphragm into the abdomen, where they all unite into one trunk on each side; and this nerve is called the *splanchnic*, or *little*, or anterior intercostal.

The splanchnic intercostal nerve proceeds a very little way from the diaphragm, before it produces a large ganglion on

the anterior part of the aorta: this ganglion is of a semilunar form, and termed the SEMILUNAR GANGLION; some small twigs pass a little from it, and form net-work, which is termed the SOLAR PLEXUS. The two semilunar ganglia send several branches to unite with, and form the other abdominal ganglia: thus—

1. The CŒLIAC PLEXUS. This surrounds the cœliac artery, and is formed by the union of several branches from the solar plexus, and semilunar ganglion.

2. The HEPATIC PLEXUS. This arises from branches given off from the cœliac plexus, uniting with those coming from the semilunar ganglion. The hepatic plexus supplies the vena portaæ, the gall-bladder, liver, duodenum, and omentum, with nerves.

3. The SPLENIC PLEXUS. Which arises from branches given off from the cœliac plexus, and right semilunar ganglion; it passes with the vessels into the spleen, and sends branches to the stomach and pancreas.

4. The SUPERIOR MESENTERIC PLEXUS. Formed by the union of several branches from the semilunar and solar ganglion, and the former plexuses. It sends nerves to the mesentery, mesocolon, and mesenteric glands.

5. The RENAL PLEXUS. Formed by branches of the semilunar ganglions, and the superior mesenteric plexus: the kidneys are supplied with nerves from this plexus.

6. The INFERIOR MESENTERIC PLEXUS. Situated near the inferior mesenteric artery.

7. The MESOCOLIC, OR POSTERIOR MESENTERIC PLEXUS. This arises from the union of several nerves sent over the aorta from the *superior mesenteric*, and *renal plexuses*, and supplies the mesentery and intestines.

8. The HYPOGASTRIC PLEXUS. Branches from the supe-

rior and inferior mesenteric plexus form this, which is situated at the fourth vertebra of the loins. The hypogastric plexus soon divides into two branches, in each of which is a ganglion that sends nerves to the urinary bladder, rectum, and contiguous parts.

9. The SPERMATIC PLEXUS. Which supplies the spermatic vessels, testes, ovaria, &c.

DISEASED APPEARANCES OF NERVES.

Although more liable than any other part of the body to disease, yet the nerves seldom present the anatomist with any morbid appearance, *post mortem.* Those which have been noticed are, a general wasting away, and a tumour of a nerve. The vagina of a nerve has been found highly inflamed, from a spicula of bone irritating it, and producing convulsions and tetanus.

PHYSIOLOGY OF THE FUNCTIONS OF THE NERVOUS SYSTEM.

Nerves are the organs of our senses. Bodies applied to certain parts of our system, produce changes in those parts, which changes are conveyed in an unknown manner to the brain, by means of the nerves only, and SENSATION is produced; so that sensation is a property peculiar to the nervous fibre, as irritability is to the muscular fibre; and hence all sentient parts are supplied with nerves, although they cannot be detected by the eye.

All impressions perceived by the organs of sense, by the percipient extremities of nerves, are transmitted to one point

in the cerebral substance, and it is here that the sensorium commune exists, considered by Des Cartes to be in the pineal gland; by La Peyronie, to be in the corpus callosum; and by Richerand, to be in the corpus annulare, as this is a confluence of the cerebrum and cerebellum.

The senses are distinguished into internal and external. The INTERNAL SENSES are ideas which the sensorium commune, or mind, forms to itself, and may be produced from the external senses, or they may be excited spontaneously: such are, *memory*, *imagination*, *conscience*, *the passions of the mind*, and *reasoning*, by the superior excellence of which, man differs so eminently from the brute.

The EXTERNAL SENSES are, *smelling*, *seeing*, *tasting*, *touching*, and *hearing*, which last is considered after the description of the ear.

SMELLING.

Smelling is a sensation by which we perceive the smell of substances.

This sensation is more or less acute, according to the extent of surface to which odours are applied. The habitual state of moisture of the membrane of this organ, is a condition necessary to the perfection of this sense.

The *organ* of smell is, the nervous papillæ of the olfactory or first pair of nerves, which are distributed on every part of the pituitary membrane of the nose.

Richerand thinks it probable that the olfactory nerves do not extend into the sinuses, and that these posterior cavities only increase the perfection of smelling, by longer retaining a greater mass of air, loaded with odorous particles, and that the true seat of smelling is the superior part of the nasal fossæ: as the pituitary membrane is there more moist, and

receives into its texture the numerous ramifications of the olfactory pair of nerves, which terminate in forming an expansion of its filaments, by a kind of parenchymatous structure, difficult to be distinguished from the texture of the membrane.

Air is the vehicle of odours, we are only sensible of their effects when we attract them by inspiration.

SEEING.

Seeing is a sensation by which we perceive bodies around us, and their visible qualities.

The *organ* of sight is the retina, an expansion of the optic or second pair of nerves.

The *object* of sight is the rays of light, which penetrate the bulb of the eye, and stimulate the retina.

Light is a subtile and solid material, which emanates from the sun, or any lucid body, with a very rapid motion, in right lines, which are called *rays of light*, and penetrate to the retina in the following manner: the rays of light fall on the pellucid and convex cornea of the eye, by whose density and convexity they are united into a focus, which passes the aqueous humour and pupil of the eye, to be more condensed by the crystalline lens. The rays of light thus concentrated, penetrate the vitreous humour, to stimulate the retina, upon which they impress the image of external objects, to be represented to the mind through the medium of the optic nerves.

The intensity of light on the retina, is moderated by the contraction of the iris, which is secondarily affected, being itself insensible to luminous rays. The pupil is, therefore, contracted in too strong a light, and dilated when we are in darkness, to admit light to produce the necessary impression on the retina.

TASTING.

Tasting is a sensation by which we distinguish the qualities of bitter, sweet, sour substances, &c.

The nervous papillæ of the ninth, or lingual pair of nerves, which are situated in the apex and margins of the tongue, are the chief *organs* of taste.

The parts subservient to taste are—

1. The *tongue*, which gives a convenient situation to the nervous papillæ, and by its extensive motion applies them to the substance to be tasted.

2. The *epidermis* of the tongue, which moderates any excessive stimulus.

3. The *saliva*, and *mucus* of the mouth, which assist the organ of taste, when it is necessary that the substance should be dissolved, in order to be tasted, and which also keep the nervous papillæ moist.

If there be an absolute deficiency of saliva, and the substance masticated be void of humidity, it will only affect the dried tongue by its property of touching, and not in the least by its savour; hence, in those diseases where the tongue is foul, the taste is either blunted or altered.

TOUCHING.

Touching is a sensation by which we distinguish the qualities of hardness, softness, heat, and cold, &c. of substances, and by which we perceive any substance that comes in contact with the skin, particularly at the points of the fingers.

The *organs* of touch are the nervous papillæ of the skin, which are extremely numerous and sensible at the points of the fingers, and on the lips, which seem endued with a peculiar sense of touch: the papillæ swell when irritated, and ele-

vate the cuticle, thereby increasing the degree of sensibility. The sense of touch is increased by education. Blind persons, it is said, have possessed the sense of feeling to such an eminent degree, as even to distinguish the variety of colours, and their different shades.

Too great a sensation is moderated by the epidermis, which also defends the papillæ from being dried by the air.

ADENOLOGY;

OR,

DOCTRINE OF THE GLANDS.

A gland is a small, round, vascular body, which serves for the secretion or alteration of a fluid.

Division. Into folliculose, globate, glomerate, and conglomerate; they are also divided from the liquid they secrete or change, into sebaceous, muciparous, lymphatic, lachrymal, salival, bilious, lacteal, &c.

A follicle, or *folliculose gland*, consists of an hollow, vascular membrane, having an excretory duct; as the muciparous and sebaceous glands.

A globate gland consists of a glomer of lymphatic vessels, connected together by cellular membrane, and has no cavity nor excretory duct; as the lymphatic glands of the lymphatic vessels.

A glomerate gland is formed of a glomer of sanguineous vessels; has no cavity, but is furnished with an excretory duct, as the lachrymal and mammary glands.

A CONGLOMERATE GLAND is a gland composed of many glomerate glands, whose excretory ducts unite, and form one large canal or duct. The pancreas and salival glands belong to this class.

The *excretory duct* of glands is a thin canal, which goes out of the gland, and excerns the secreted fluids, by the contractility of its coats.

The *nerves* and *vessels* of glands are numerous, and, in most instances, come from the neighbouring parts. Some particular glands are, however, supplied with vessels proper to them, as the visceral glands, the thyroid, prostate, &c.

Glands are connected with other parts by cellular membrane. They are larger in infants than in adults.

GLANDS OF THE SKIN.

The SUBCUTANEOUS GLANDS are sebaceous, and situated under the skin, which they perforate by their excretory ducts.

These glands are frequently found diseased. A collection of a white sebaceous substance in the excretory duct is among the most common diseased appearances. It arises from a diseased action of the gland separating an unhealthy sebaceous substance.

They are frequently found enlarged and inflamed after death, constituting the diseases called *phyma* and *furunculus*.

GLANDS IN THE CAVITY OF THE CRANIUM.

1. The GLANDS OF THE DURA MATER, called also, after their discoverer, PACCHIONIAN, are small fatty substances, situated in and near to the superior longitudinal sinus of the dura mater, in peculiar foveolæ of the os frontis and parietal bones.

The Pacchionian glands vary very much in their appear-

ance in the dead body. One, which is certainly a diseased appearance, is a general enlargement, which causes, in some cases, an absorption of the superincumbent bone.

2. The GLANDS OF THE CHOROID PLEXUS, which are globate, and situated in the choroid plexus of the lateral ventricles of the brain.

The glands of the choroid plexus are sometimes changed into a white substance, the size of a pin's head, and larger, which is hard, and apparently of the nature of scirrhus.

Whether the globular vesicles, called hydatids, are diseased appearances of these glands, is not ascertained.

3. The PITUITARY GLAND, situated in a duplicature of the dura mater, in the sella turcica of the sphænoid bone. The infundibulum of the brain terminates in this gland.

The pituitary gland occasionally is converted into a hard subcartilaginous structure; and, it is said, into bone.

It has been completely absorbed, in consequence of pressure from disease of the brain.

GLANDS OF THE EYES.

1. MEIBOMIUS'S GLANDS. These are small and numerous sebaceous glands, situated under the skin of the eyelids, near their margins. Their excretory ducts open on the margins of the tarsus, and are called *puncta ciliaria*.

These glands are sometimes found converted into white sebaceous spots; and this state generally accompanies other marks of scrofula in the habit.

2. The LACHRYMAL GLAND, which is glomerate, and situated above the external angle of the orbit, in a peculiar depression of the os frontis. This gland has six or eight excre-

tory canals, through which the tears are conveyed, and which open upon the internal surface of the upper eyelids.

The lachrymal gland is sometimes found without the orbit, near the external canthus.

3. The CARUNCULA LACHRYMALIS, a small and red prominence, obvious in the internal angle of the eye, between the tarsi of the eyelids. It consists of small sebaceous glands, which secrete a fæculent humour.

GLANDS OF THE NOSTRILS.

The pituitary membrane lining the nostrils, and its sinuses, is every where furnished with *muciparous glands*, which secrete the mucus of the nose.

Inflammation of these glands constitutes, in conjunction with a similar affection of the membrane itself, *catarrh*.

GLANDS OF THE EAR.

The CERUMINOUS GLANDS are situated under the skin of the meatus auditorius externus, and secrete the wax of the ears.

GLANDS OF THE MOUTH.

The glands of the mouth which secrete the saliva, are called *salival* ; they are,

1. The PAROTIDS. Two large conglomerate glands, situated one under each ear, between the mammillary process of the temporal bones, and angle of the lower jaw. The excretory canal of this gland opens in the mouth, and is called, from its discoverer, the *Stenonian* duct.

The mumps is a particular affection of this gland, of an inflammatory nature, and is called *cynanche parotidea*, or *parotis*.

2. The MAXILLARY. Which are conglomerate glands, situated under the angles of the lower jaw. The excretory ducts of these glands are also called, after their discoverer, *Warthonian*.

These glands are very frequently affected with scrofula.

3. The SUBLINGUAL GLANDS, situated under the tongue.

4. The GLANDS OF THE CHEEK, situated on the internal surface of the cheeks.

5. The LABIAL GLANDS, on the internal surface of the lips, under the common membrane of the mouth.

6. The MOLAR GLANDS, situated on each side of the mouth, between the masseter and buccinator muscles. Their excretory ducts open near the last dens molaris.

EXTERNAL GLANDS OF THE NECK.

1. The JUGULAR GLANDS, which are globate, and found under the skin of the neck about the external jugular veins: they are in general about twenty in number.

These glands are frequently enlarged and scrofulous.

2. The SUBMAXILLARY GLANDS, also globate and situated in the fat under the jaw.

3. The CERVICAL, found under the cutis in the fat about the neck.

4. The THYROID. A large gland lying upon the cricoid cartilage, trachea, and horns of the thyroid cartilage. It is uncertain whether it be globate or conglomerate. Its excretory duct has never been detected, and its use is unknown.

The thyroid gland is often the seat of *bronchocele*, which is a morbid enlargement, either from a deposition of adventitious matter, or distention from air.

GLANDS OF THE FAUCES.

The glands situated under the membrane which lines this cavity, are muciparous, and divided, from their situation, into *palatine*, *uvular*, *tonsil*, *lingual*, *laryngeal*, and *pharyngeal*.

The tonsil glands, which are also called the almonds of the ear, are subject to inflammation, forming the *cynanche tonsillaris*—suppuration—enlargement—scirrhus.

GLANDS OF THE BREASTS.

The MAMMARY, or *lacteal glands*, are situated under the fat of the breasts. Their excretory ducts are called *tubuli lactiferi*, and *tubuli galactoferi*; they proceed to the nipple, in which they open.

The tubuli galactoferi are often distended with milk, so as to induce inflammation of the breast.

Inflammation of the breast, either of the cellular substance or glandular part, is called *mastodynia*, or *mastitis*.

GLANDS OF THE THORAX.

1. The THYMUS, a large gland, peculiar to the fœtus, and which disappears soon after birth: it is situated in the anterior duplicature or space of the mediastinum, under the superior part of the sternum, and above the pericardium. An excretory duct has not been as yet detected, but lymphatics are seen going from this gland to the thoracic duct.

2. The BRONCHIAL, which are large blackish glands near

the end of the trachea, and beginning of the bronchiæ, and which secrete a blackish mucus.

The bronchial glands are not unfrequently found ossified.

3 The ŒSOPHAGEAL GLANDS, found under the internal membrane of the œsophagus, and which secrete the mucus f that canal.

3. The DORSAL GLANDS, situated upon the fourth or fifth vertebra of the back, between them and the posterior surface of the œsophagus. They have no excretory ducts.

GLANDS OF THE ABDOMEN.

1. The GASTRIC GLANDS, which are muciparous, and situated under the external membrane of the stomach.

It should be remembered, that these glands only secrete the mucus of the stomach, and not the gastric juice, which is separated by arteries.

2. The INTESTINAL GLANDS, which are also muciparous, and found under the internal membrane of the intestines, especially the large.

. The MESENTERIC GLANDS, situated here and there in the cellular membrane of the mesentery. The chyle from the intestines passes through these glands to the thoracic duct.

Mesenteritis, or true inflammation of the mesentery, is, in fact, inflammation of these glands; whereas inflammation of the laminæ of the peritoneum which form the mesentery, is *peritonitis mesenterica.*

Mesenteric obstruction arises from disease of these glands, and is a frequent cause of the *marasmus* of children: the chyle being prevented passing the glands in sufficient quantity to form good blood.

4. The HEPATIC GLANDS, also called *acini biliosi*, and *penicilli*, which form the substance of the liver, and separate the

bile into small ducts, which at length terminate in the *ductus hepaticus.* (See *Liver.*)

Diseases of the glandular part are not yet distinguished from the diseased appearances of the cellular connecting substance, and the other vessels of the liver.

5. The CYSTIC GLANDS, which are muciparous, and found under the internal membrane of the gall-bladder, especially about its neck.

6. The PANCREATIC GLANDS, which constitute the pancreas: a small duct arises from each gland, which unite to form the *ductus pancreaticus.* (See *Splanchnology.*)

7. The EPIPLOIC, or *omental glands,* which are globate, and situated in the omentum.

GLANDS OF THE LOINS.

1. The SUPRA-RENAL GLANDS, situated in the adipose membrane, one above each kidney. An excretory duct has never been detected, and their use is unknown.

2. The KIDNEYS. (See *Splanchnology.*)

3. The LUMBAR GLANDS, which are globate, and situated about the beginning of the thoracic duct.

4. The ILIAC GLANDS, found about the beginning of the iliac vessels.

5. The *sacral,* which are globate glands, and adhere to the os sacrum.

GLANDS OF THE ORGANS OF GENERATION OF MAN.

1. The ODORIFEROUS GLANDS of the glans penis, which are sebaceous, and situated around the *corona glandis.*

2. The MUCOUS GLANDS OF THE URETHRA, situated under the internal membrane of the urethra. The mouths of their excretory ducts are called *lacunæ.*

> When these glands secrete a bland yellow fluid, which they often do from relaxation, it forms a gleet, or *leucorrhœa;* and when an increased and morbid secretion takes place from venereal virus, it is called *gonorrhœa virulenta.*

3. COWPER'S GLANDS, so called from their discoverer, are three large muciparous glands, two of which are situated before the prostate gland under the acceleratores urinæ, and the third more forward before the bulb of the urethra.

4. The PROSTATE, a very large, heart-like, firm gland, situated between the neck of the urinary bladder and bulbous part of the urethra. It secretes a lacteal fluid, which is emitted into the urethra by ten or twelve ducts near the verumontanum, during coition.

> The prostate gland is very frequently found diseased by abscess, scrofula, scirrhus, calculi, enlargement of its ducts, and a diminution in size.

GLANDS OF THE FEMALE ORGANS OF GENERATION.

1. The ODORIFEROUS GLANDS OF THE LABIA MAJORA AND NYMPHÆ, which are sebaceous, and situated under the skin of those parts.

2. The ODORIFEROUS GLANDS OF THE CLITORIS, which are numerous, situated about the basis of the clitoris, and are of the same nature as the former.

3. The MUCOUS GLANDS OF THE URETHRA, situated under the internal membrane of the urethra.

4. The MUCOUS GLANDS OF THE VAGINA, situated under the internal membrane of the vagina.

These glands furnish the puriform fluid in leucorrhœa and gonorrhœa.

GLANDS OF THE EXTREMITIES.

The *glands of the groin*, or INGUINAL GLANDS, are globate, or lymphatic; they are situated in great numbers in the cellular membrane of the inguinal region, and receive the lymphatic vessels from the glans penis and lower extremities.

These are the glands which inflame and form bubo in the venereal disease from absorption and sympathy.

The SUBAXILLARY GLANDS are also globate, and are situated in the cellular membrane of the arm-pit; they are also numerous, and receive the lymphatic vessels from the breasts and superior extremities.

The axillary glands sometimes form bubo from absorption of venereal and putrid matter.

GLANDS OF THE JOINTS.

The small fat-like masses, situated within the moveable joints, are erroneously called SYNOVIAL GLANDS: their structure is not glandular; they are composed of adeps and an arrangement of the internal vascular membrane of the joint, which gives them a fimbriated appearance. By these little masses the synovia is separated from the blood for the easy motion of the joint.

PHYSIOLOGY OF SECRETION.

Secretion is a particular function in an animal body, by which a fluid is separated from the blood, different in its properties from the blood.

The *organs* which secrete the various humours, are the glands.

The *proximate* or *immediate cause* of secretion is a specific action of the arteries of the glands; for every secretion is formed from the extremities of arteries. The secretion of the bile is no exception to this law, for the vena portæ takes upon itself the function of an artery; thus the mucous glands secrete *mucus;* the salival glands, *saliva;* the penicilli of the liver, *bile;* the cryptæ of the kidneys, *urine,* &c.

The secreted fluids are the proper stimuli to the receptacles and ducts, through which the secretion is to pass to its place of destination; so that the secretions move along the excretory ducts by means of the contractility of the coats of the ducts and the assistance of neighbouring moving powers.

SPLANCHNOLOGY;

OR,

DOCTRINE OF THE VISCERA.

The human body is divided into *head, trunk,* and *extremities.*

The HEAD is divided into *face* and *hairy scalp.*

The *face* comprehends the *frons,* or forehead; *tempora,* or temples; *nasus,* or nose; *aures,* or ears; *oculi,* or eyes; *os,* or mouth; *buccæ,* or cheeks; and *mentum,* or chin.

The *hairy scalp* is subdivided into *vertex,* or crown of the head; *sinciput,* or fore-part; *occiput,* or hinder-part; and *latera,* or sides.

The TRUNK is divided into *neck, thorax, abdomen,* and *pelvis.*

The *neck* is distinguished into an anterior and posterior part. On the former is an eminence in males, formed by the thyroid cartilage, called the *pomum Adami;* because the forbidden fruit is said to have stuck there; the latter is termed the nape of the neck, or *nucha colli.*

The *thorax* is divided into an anterior, and posterior part, and two sides.

The anterior part of the thorax is termed the *sternum;* at its bottom is a hollow, the pit of the stomach, or *scrobiculus cordis;* and the breasts are situated on each side of the sternum.

The posterior part of the thorax is termed the *dorsum,* or back; and its sides, *latera thoracis.*

The *abdomen* is distinguished into REGIONS. The anterior part into three regions:

1. The *epigastric,* which lies over the stomach, and whose sides are termed the *hypochondriac regions.*

2. The *umbilical,* surrounding the navel, and whose sides are called the *epicolic regions.*

3. The *hypogastric,* which lies over the urinary bladder, and whose sides are called *groins.*

The *pubes* is the hairy part under the abdomen, between the groins. Under the pubes are the parts of generation—in men, the *scrotum* and *penis;* in women, the *labia,* and *rima vulvæ.*

The space between the genitals and anus is called the *perinæum.*

The EXTREMITIES are divided into superior and inferior.

The SUPERIOR EXTREMITY, into *top of the humerus, brachium, fore-arm,* and *hand.*

The *hand,* into *carpus, metacarpus,* and *fingers.*

Fingers, into *pollex, index, digitus medius, digitus annularis, digitus auricularis.*

The INFERIOR EXTREMITY is divided into *femur*, or thigh; *crus*, or leg; and *extremity of the foot*.

The *foot*, into *tarsus*, *metatarsus*, and *toes*.

The INTERNAL DIVISION of the body is into three cavities, viz. cavity of the cranium, thorax, and abdomen.

COMMON INTEGUMENTS.

These are so called because they are the common coverings, as it were, to the body; they consist of the *epidermis*, *rete mucosum*, *cutis*, and *membrana adiposa*.

EPIDERMIS.

Epithelium. Cuticula.

The epidermis, scarf-skin, or cuticle, is a thin, pellucid, insensible membrane, covering the whole external surface of the body. It is perforated by the hairs, inhaling and exhaling vessels. Its outer surface is dry and horny, and marked with many lines, in which perforations are evident. Its internal surface is moist and shaggy, and connected to the cutis by the *rete mucosum*, which lies between them and the vessels and hairs.

The epidermis not only covers the external surface of the body, but also many of the internal parts, as the nose, mouth, anus, vagina, urethra, &c. The thickness of the scarf-skin varies in different parts; it is very delicate over the lips, tongue, glans penis, vagina, and rectum; very thin at the finger-ends, over the face, &c.; and very thick on the soles of the feet, and palms of the hand.

The colour of the epidermis is white, which proves that it is a peculiar secretion, and not formed by a drying of the rete mucosum, which in Ethiopians is black.

The use of this common integument is to cover the very sensible cutaneous papillæ.

The epidermis is often seen peeling off in small scales: when this is from disease, it is called *furfura.*

RETE MUCOSUM.

Mucus Malpighianus. Rete Malpighianum. Corpus mucosum. Corpus reticulare.

A mucous substance, said to be disposed in a net-like form, between the epidermis and cutis.

The difference of colour in mankind depends on this substance: in Europeans it is white; in Ethiopians, black; &c.

There is great variety in the thickness and transparency of the rete mucosum; in the lips, mouth, over the glans penis, nymphæ, vagina, &c. it is transparent and very delicate. It is thickest in the scrotum.

CUTIS.

Dermis. Cutis vera.

The true skin is an elastic, sensible, extremely porous, and thick membrane, situated between the rete mucosum and adipose membrane, covering the whole body.

It is composed of a fibrous, vascular, and nervous structure. Its external surface is covered by the rete mucosum, and immediately over it is the cuticle; it is here that a vast number of *nervous fibrils,* called *papillæ,* are every where projecting from its surface to constitute the organ of touch: these are of various forms, and are most exquisitely sensible on the lips, finger-ends, &c. The use of the skin is to cover the whole

body, and afford a situation for the organs of touch, exhalation, and inhalation. (See *Physiology of Absorption.*)

PHYSIOLOGY OF PERSPIRATION. Perspiration is a species of secretion by which the blood is freed of a quantity of aqueous fluid by the exhalant arteries of the skin.

It is divided into *insensible* and *sensible perspiration:* the former is continually going on, by which means the surface of the body is kept smooth and moist; it may be detected by placing any part of the skin near a looking-glass, which will become soiled. The latter, commonly termed *sweat*, is observed occasionally.

UNGUES.

The nails are horny laminæ, situated in the extremities of the fingers and toes, supposed to be a continuation of the cuticle.

USE. To defend the nervous papillæ from contusion.

PILI.

The hairs are thin, elastic, dry filaments, growing out from the skin.

They arise from bulbs, situated in the cellular membrane under the skin: each bulb has two capsules containing an oily fluid between them, which is thought to give colour to the hair.

COLOUR and SITUATION, various.

NAMES. The hairs are termed *capilli* on the head; *supercilia*, or eyebrows, above the eyes; *cilia*, or eyelashes, on the margin of the eyelids; *vibrissæ*, in the nostrils; *pili*

auriculares, in the meatus auditorius; *mystax*, on the upper lip; *barba*, on the lower jaw, &c. &c.

MEMBRANA CELLULOSA.

Tela cellulosa. Membrana adiposa. Reticular membrane.

The cellular membrane is composed of laminæ and a fibrous texture, so disposed as to form cells and a web-like structure. It is found in almost every part of the body, connecting them together, and is well exemplified by the butchers blowing up their veal, and by macerating any soft part. The cellular membrane is extremely vascular, especially, that which lies immediately under the skin, that about the kidneys, mesentery, &c.

The vessels of cellular membrane occasionally separate oil from the blood into the cellular structure, when it becomes *adipose* membrane. This does not take place generally; many parts are without fat: there is no adeps about the penis, tunica conjunctiva, lungs, &c.

USE. The use of the cellular membrane is very considerable; it connects parts together; it constitutes the bed for the origin of the absorbents; it allows of friction by its elasticity, without deforming the part; and it forms the substance of almost all the membranes.

DISEASES. The cellular membrane is subject to a variety of diseases, such as *anasarca—ecchymosis—emphysema—scirrhus*, &c.

HEAD.

The parts which form the head are divided into external and internal.

The *external parts* are, the common integuments, hair, a tendinous expansion, three pair of muscles, pericranium, and cranium itself.

The *internal parts* are, the dura mater, membrana arachnoidea, pia mater, cerebrum, cerebellum, medulla oblongata, nine pair of nerves, four arteries, and twenty-two venous sinuses.

DURA MATER.

Dura meninx.

A strong, thick, fibrous insensible membrane, covering the external surface of the brain, situated immediately under the cranium, to which it adheres very firmly.

It is composed of two strong membranous layers, or *laminæ*. The external lamina lines the internal surface of the cranium, supplying the place of periosteum, for the internal table of the cranium is nourished by its vessels. The internal lamina is closely connected to the external by cellular structure; in many places, however, they are separated so as to form a space, or sinus, in which the blood passes as through veins, to be returned towards the heart. The internal lamina also forms several processes, the chief of which are the following:

1. The FALX, or *falciform process*, or *septum cerebri*. This originates, by a very firm attachment, from the middle of the sphænoid bone and crista galli, within the cranium, and rises upwards like a bow, adhering to that part of the external lamina of the dura mater, immediately covering the middle of the frontal bone, the sagittal suture, and occipital bone, until it arives at the meeting of the internal crucial spine of the occipital bone, where it unites to the tentorium. In this course the falx lies between the hemispheres of the brain, its acute edge being in contact with the *corpus callosum*. The superior part of the falx contains the longitudinal sinus.

2. The TENTORIUM, or *septum transversum*. This production of the internal lamina of the dura mater arises from the clinoid processes of the sphænoid bone, and passes horizontally backwards, attached to the horizontal ramus of the crucial spine of the occipital bone. It separates the cerebrum from the cerebellum. In the outer edge of this process pass the lateral sinuses of the dura mater.

3. The SEPTUM CEREBELLI is a production passing below the tentorium, as if it were a continuation of the falx, and lying between the lobes of the cerebellum. There are several smaller processes which need not be mentioned.

The veins or sinuses of the dura mater are—

1. The LONGITUDINAL SINUS. It commences at the origin of the falx, and passes within it, of a triangular form, upwards, and immediately under the sagittal suture of the cranium, to the occipital tubercle, where it bifurcates into the lateral sinuses.

Within this sinus are a number of tendinous fibres, or *trabeculæ*, which cross in various directions from one side to another: they are the *chordæ Willisii*.

The *internal Pacchionian glands* are also occasionally noticed in this sinus: they are small glandiform bodies, sometimes very numerous, rising from between the trabeculæ.

2. The LATERAL SINUSES. These are continued, one along each transverse or horizontal branch of the crucial spine of the os occipitis downwards to the *foramen lacerum in basi cranii*, where it passes out of the cranium, and commences internal jugular vein.

3. The TORCULAR HEROPHILI. This is a small vein, or sinus, in that part of the processes formed by the meeting of the tentorium, falx, and septum cerebelli; it proceeds directly backwards to the bifurcation of the longitudinal sinus.

Besides these sinuses, many other small ones may be noticed.

The *arteries* of the dura mater are beautifully disposed in an arborescent form; they are branches of the arteria spinosa, the meningia anterior and posterior.

Some anatomists assert it has nerves, whilst others deny it.

A number of small fatty particles are found near the longitudinal sinus on the internal surface, about the middle, called *external Pacchionian glands*, or glands of the dura mater.

Use. The use of this membrane is to nourish the internal table of the skull; to envelope the brain, and form processes which prevent one part from pressing upon another, and afford a situation for the blood to collect and pass out of the cranium.

Diseased appearances.—The diseased appearances of this membrane are, inflammation—adventitious membrane—coagulum between it and the cranium—gangrene—spongy tumours—scrofulous tumours—ossification—coagulum, or, as it improperly called, polypus in the sinus—obliteration of the sinus—abscesses of the sinus—the dura mater of a yellow colour.

MEMBRANA ARACHNOIDEA.

Membrana arachnoïdes. Tunica arachnoïdes.

A very delicate and transparent membrane, situated between the dura and pia mater, and surrounding the cerebrum, cerebellum, medulla oblongata and spinalis. It resembles a spider's web only about the basis of the cranium, where it is very vascular: in other parts it is membranous and diaphanous, similar to the pleura and peritoneum. It not only covers the parts above-mentioned, but it enters the cavities of the brain, which it lines, and forms the membrane covering the thalami nervorum opticorum, corpora striata, pedes hippocampi, and

third and fourth ventricle.—The use of this membrane is unknown.

Diseased appearances.—The arachnoid membrane of the brain is found adhering to the dura mater—covered with pus—distended with coagulable lymph and serum—opake and thickened—highly inflamed.

PIA MATER.

Pia meninx.

The pia mater is the third covering of the brain, cerebellum, medulla oblongata and spinalis. It is a highly vascular, delicate membrane, embracing those parts closely, penetrating between their convolutions, and sending a great number of vessels to the cortical substance of the cerebrum and cerebellum.

The *tomentum cerebri* consists of the fine vessels that are sent from this membrane into the brain, which, when pulled out by artificial means, gives the internal surface of the pia mater a floccose appearance.

Processes are sent from the pia mater, between the convolutions of the brain. Where one or two convolutions meet, there is a larger space formed; the pia mater falls, as it were, down into these spaces; and the arachnoid membrane going directly over these excavations, a space is formed: these are termed the *intergyral* spaces of the pia mater.

The veins of the pia mater evacuate their blood into the sinuses of the dura mater.

The arachnoid membrane is said, by some anatomists, to be the external lamina of the pia mater.

Use. The use of this membrane is to distribute the blood to various parts, by affording a convenient situation for the cerebral arteries to ramify on.

DISEASED APPEARANCES. The diseased appearances of this membrane are, inflammation—thickening of the pia mater—pus below it—blood extravasated into it—turgescency of vessels—abscess between it and the brain.

CEREBRUM.

Encephalon. Sensorium commune.

The cerebrum, or brain, is a large viscus, somewhat of an oval figure, situated in the cavity of the cranium. That which is called *brain*, in common language, consists of the *cerebrum*, *cerebellum*, and *medulla oblongata*.

The brain is composed of three substances, the medullary, cortical, and black substance. Some anatomists have enumerated a fourth.

1. The SUBSTANTIA MEDULLARIS, of a delicate white colour: it composes the greater part of the whole brain.

2. The SUBSTANTIA CORTICALIS, called also *cineritia*, which encircles the whole brain, and is found in many of the internal parts: the portion which covers the medullary part, is highly vascular, receiving the vessels from the pia mater.

3. The SUBSTANTIA NIGRA is observed by making a transverse section through the crura cerebri, in the middle of which it is situated.

Upon viewing the superior surface of the cerebrum, it exhibits an uniformly convex oval, with a large fissure dividing it into two HEMISPHERES. The hemispheres are united both above and below, and there are cavities formed by their union called ventricles; those portions of the brain which unite the hemispheres, are called COMMISSURES.

The under-surface of the brain is more irregular, and though it does not appear to be composed of two hemis-

pheres, yet by a deep division, anteriorly and posteriorly, such a formation can be seen: it presents six distinct LOBES, which correspond to the six depressions, or *fossæ*, in the basis of the skull; so that the two anterior lobes lie on the frontal bone; the two middle, in the depressions made by the sphænoidal bone; and the two posterior lobes pass over the cerebellum to occupy the superior occipital depressions.

When the pia mater is removed, the brain has somewhat the appearance of an irregular convoluted mass heaped together: there are spaces between the *convolutions*, which allow the processes of the pia mater to pass some way down; these are termed INTERGYRAL SPACES of the brain.

There is one convolution which goes considerably deeper than the rest, causing thereby a much deeper fissure; this is seen when a horizontal section of the brain is made below the corpus callosum. It was first noticed by Sylvius, and has ever since been termed *fissura magna Sylvii.*

Upon the under-surface of the brain, between the middle lobes, two processes are sent downwards and backwards, like legs; these are termed the CRURA CEREBRI; they are soon encompassed by the crura cerebelli, to form the PONS VAROLII. There are also two round white bodies seen before these, like two peas, called the CORPORA CANDIDANTIA WILLISII, or CORPORA ALBICANTIA.

A *cineritious substance* is seen between the corpora albicantia, called *pons Tarinii;* it is the union of the sides of these bodies.

When the two hemispheres of the brain are separated a little from one another, a white substance presents itself; this is the COMMISSURA SUPERIOR; it is also termed the *corpus callosum* and *commissura magna cerebri;* and the elevated line running along its middle is the RAPHE. The commissura superior is covered by a portion of the hemispheres of the

brain, which laps, as it were, over it on each side: these portions are termed the LABIA CEREBRI.

All the parts that have been hitherto enumerated may be seen without cutting the cerebrum, except the three substances of the brain.

When the hemispheres of the cerebrum are cut away in a direct line with the surface of the commissura superior, a large surface of the medullary substance is brought into view; this is the CENTRUM OVALE: the commissura superior cerebri, its raphe and striæ, and the cortical substance of the brain, may now be examined minutely.

There are four cavities within the remaining portion of the cerebrum, called VENTRICLES; two of these are situated laterally, and are called *lateral ventricles:* at their upper part they are separated from each other by a very delicate partition, in which is another *cavity*, but inferiorly they are at a greater distance from each other, so as to allow of a considerable portion of brain, and a cavity, to be situated between them; and this cavity is the *third* ventricle.

An incision must now be made, on either side of the raphe of the commissura superior cerebri, *into* one of the lateral ventricles, and its upper and outer parietes removed so as to completely expose the cavity. The LATERAL VENTRICLE, so called from its situation, is now brought into view: its figure is triangular, having three sinuses or horns; hence it is also called the *tricorn cavity.* The following are to be noticed in each lateral ventricle*:

1. A very delicate and pellucid membrane separating one cavity from the other, called SEPTUM LUCIDUM. There is, occasionally, a small cavity between the laminæ composing this septum, called the FIFTH VENTRICLE by Professor Soemmering.

2. A convex brown-coloured body, in the anterior sinus, called CORPUS STRIATUM; it is of a pyriform shape, its round end turned towards the face, and its taper end, or *crus*, backwards.

3. A portion of a white convex body, called THALAMUS NERVI OPTICI, situated behind the former, and separated from it by an opake line, in which there is a blood-vessel: the line of separation is called GEMINUM CENTRUM SEMICIRCULARE, and *tænia semicircularis*.

The inner and upper surfaces of the thalami nervorum opticorum, are so closely connected as to present one continued surface, called the commissura mollis.

A part only of the thalami nervorum opticorum is seen in this ventricle; the fornix which separates the lateral ventricles from the third ventricle, goes over their middle, so that the greater part of each thalamus is seen in the third ventricle.

4. A very vascular substance lying between these parts and the bottom of the septum lucidum, termed PLEXUS CHOROIDES. This plexus comes into the lateral ventricle at its superior and anterior cornu; and the hole through which it comes is the *foramen Monroianum.*

> Many have denied that this foramen is open when no force has been used to separate it. In collections of water in the cavity, it is always open, and very often when there is no water and no force used.

The choroid plexus passes over the portion of the thalamus of the optic nerve in this ventricle, into the inferior cornu.

5. The CORPUS FIMBRIATUM, a flat tape-like substance, which goes downwards from the bottom of the septum lucidum into the posterior and inferior horns of this cavity.

6. The UNGUIS, or *hippocampus minor*, a convex body like the nail of the little finger, situated in the posterior horn of the ventricle, and arising from the corpus fimbriatum.

7. The PES HIPPOCAMPI, called also *cornu ammonis* and *hippocampus major*, a long convex substance occupying the whole of the inferior cornu, and arising from the corpus fimbriatum.

8. A number of columns, more evident in some brains than in others, passing round the superior and posterior parietes of the lateral ventricle, called COLUMNA ANONYMA.

The lateral ventricles are covered with a fine membrane, formed by a reflection of the pia mater, or tunica arachnoides, which secretes a very subtile fluid to lubricate the cavities and prevent parts from growing together.

These are all the circumstances to be noticed in the lateral ventricles. The fornix and third ventricle are next to be considered.

Keeping in view the commissura superior cerebri, and the process going directly downwards, called the septum lucidum, the FORNIX will not be difficult to understand. It is, in fact, the bottom of the septum lucidum, which arises by the inside of each corpus striatum, and passes upwards and backwards, like an arch, and then divides posteriorly; and all this in less than the space of an inch. It arises, by two pillars, about a quarter of an inch in length, and the thickness of a crow-quill, one from each side below the corpus striatum. These two pillars are called the *anterior crura of the fornix:* one lies over the choroid plexus, and forms the superior part of the foramen of Monro. These crura are connected by a medullary substance. Having passed over the choroid plexus, the crura unite, and continue united for a very little way; they then separate, and proceed backwards and outwards, by the name of the *posterior crura of the fornix*, and are soon flattened, when they become the *corpora fimbriata*, which pass round into the posterior and inferior horns of the lateral ventricles.

The space between the posterior crura of the fornix is triangular, and marked with a number of depressed lines, not always conspicuous; it is termed the PSALTERIUM, or *lyra*, from its supposed resemblance to David's harp. These circumstances are seen by dividing the two anterior crura of the fornix, and turning it backwards with the septum lucidum and commissura superior cerebri.

If the fornix be carefully turned backwards, without disturbing the choroid plexuses, a very beautiful net-work of vessels will be seen running from one plexus to the other. This lamina, or net-work of vessels, lies over the third ventricle, in contact with the fornix and psalterium, and is called *velum interpositum:* in it are two veins, the venæ magnæ Galeni, which unite just before the tentorium; and the common vein returns its blood into the torcular of Herophilus.

When the choroid plexuses are removed, and the velum interpositum, a space, or cavity, is perceived between two large rounded bodies, which space is the THIRD VENTRICLE. The sides are formed by the thalami nervorum opticorum: a part of them only was seen in the lateral ventricles, but the whole is now brought perfectly into view. There are mostly one or two elevations on the thalami; one sometimes in the portion within the lateral ventricles, and one under the corpus fimbriatum; these are termed the *collicles* of the thalami nervorum opticorum. In the third ventricle are to be noticed:

1. The COMMISSURA ANTERIOR CEREBRI, or anterior commissure. This is a band like a nerve, the thickness of a crow-quill, going across the anterior part of the third ventricle, and uniting, as it were, one side of the cerebrum to the other: it lies horizontally immediately below the anterior crura of the fornix; and if the brain be carefully dissected away, by

which the striated appearance of the corpus striatum will be exposed, it can be traced penetrating an inch and a half on each side.

2. The third ventricle runs forwards under this commissure, becoming smaller, until it terminates in a slender, red substance, which is sometimes solid and sometimes hollow: this funnel-shaped portion is the ITER AD INFUNDIBULUM; it ends in the pituitary gland, situated in the sella turcica.

3. The bottom of the third ventricle is formed by a portion of the medullary substance of the brain, going across from one side to the other, in the same way as the commissura superior does; it is therefore termed the COMMISSURA INFERIOR CEREBRI.

4. There is an elevated line on the side of each thalamus nervi optici in the third ventricle, which runs backwards; these meet posteriorly, and have a small, heart-shaped, pulpy substance attached to them, which is the PINEAL GLAND; and the lines are termed the *peduncles*, or *crura of the pineal gland*. It requires that the plexus of vessels about this part be carefully dissected away, to shew the gland, which will then be seen lying over the corpora quadrigemina to be described. It is the number of vessels about this gland that gives the lines on the psalterium which covers the gland.

5. Before the gland, and below its crura, is a nervous band opposed to that in the anterior part of the ventricle, called COMMISSURA POSTERIOR CEREBRI. It cannot be traced penetrating the brain like the anterior.

6. Immediately under this commissure is an opening, opposed to the iter ad infundibulum: this penetrates through the medulla oblongata, and is termed the ITER A TERTIO AD QUARTUM VENTRICULUM, or *aqueduct* of Sylvius.

Behind the posterior commissure are four rounded eminences, called CORPORA QUADRIGEMINA; two are situated superiorly, and two inferiorly: they were formerly called *nates* and *testes*.

The third ventricle is lined by a delicate membrane, a reflection of the pia mater, or *membrana arachnoides*, which secretes the subtile vapour by which it is lubricated.

The lateral ventricles of the brain, which are separated from each other by the septum lucidum, it is asserted by some writers, communicate with one another. The third ventricle having been considered, and the situation of the fornix, this *circuitous* communication may be explained. In the anterior part of the lateral ventricles there is the foramen of Monro, which is sometimes completely shut; and when this is the case, there can be no communication whatever between the lateral ventricles: but it is occasionally open, and then a probe may be passed under the anterior crus of the fornix into the third ventricle; and if a probe be passed through the foramen of the opposite ventricle, the probes will meet in the third ventricle. The communication, therefore, between the lateral ventricles is by the intervention of the third ventricle.

The whole of the cerebrum may now be removed by dividing two processes of the crura cerebri, in the middle of which the substantia nigra will be seen.

Three pair of nerves only arise from the cerebrum:

1. The *olfactory*. These arise from the corpora striata, are somewhat triangular at their beginning; they proceed forwards under the anterior lobes of the cerebrum, and become flat and pulpy over the ethmoid bone, where they send off nerves to the nose.

2. The *optic nerves*. These originate from the thalami nervorum opticorum, by broad beginnings, which proceed around the superior part of the crura cerebri, to join one ano-

ther: from this junction two round nerves go off through the optic foramen to the eye.

3. The *motores oculorum*. These arise from the crura cerebri, at their lower end, and pass forwards to penetrate the dura mater just above the petrous ridge of the temporal bone.

DISEASED APPEARANCES OF THE CEREBRUM.—These are, a morbid softness—a morbid firmness—a general change of colour—inflammation—a part of a pulpy consistence—abscess—ulceration—a morbid hardness of a part—scrofulous tumours—extravasation, or blood—vesicles, or hydatids—fungus—absorption of the brain.

In the *lateral ventricles*. Inflammation, or the membrane lining them—hydrocephalus internus, or water in these ventricles—an alteration of form from vesicles or other bodies protruding.

Corpora striata. Totally destroyed by disease—a number of brown specks in their substance.

Geminum centrum semicirculare. A morbid opacity.

Thalami nervorum opticorum. Thalami united in the third ventricle—a morbid commissure between them.

Choroid plexus. Inflammation—turgescency of vessels—varix—vesicles—hydatids?—small glandiform substances in the plexus of a subcartilaginous consistence—worms.

Septum lucidum. A morbid opacity—water in the cavity between its laminæ.

Third ventricle. Water collected—the shape altered by the coalescence of the thalami nervorum opticorum.

Pineal gland. Converted into a gritty substance—converted into an earthy substance—scirrhus—a small yellow body growing to it—a general enlargement.

Plexus of vessels surrounding the pineal gland. Anasarca—surrounded with coagulable lymph—surrounded by pus.

CEREBELLUM.

The cerebellum, or little brain, is of a round figure, and situated under the tentorium of the dura mater in the inferior occipital depressions. It is divided into two *lobes* by a process of the dura mater, and sends four processes, or *crura*, forwards, which, with the crura of the cerebrum, appear to constitute the medulla oblongata. The cerebellum is composed, like the brain, of a cortical substance, and a medullary. It is closely covered by the pia mater, which sends processes between its convolutions, that appear more regular than the convolutions of the cerebrum. They first divide the external surface of the cerebellum into laminæ, and each lamina is again subdivided, like the leaf of the male fern, so that when the cerebellum is cut transversely, this arrangement of the cortical substance has the appearance of a tree and its branches; and this is termed the ARBOR VITÆ.

There is a considerable fissure in each lobe of the cerebellum, proceeding directly backwards from the crura cerebelli, at which end it is the widest: it may be termed *fissura magna cerebelli.*

The two lobes of the cerebellum are separated anteriorly, by a long triangular space, the FOURTH VENTRICLE, which has a communication with the third, by means of a long canal, the *iter à tertio ad quartum ventriculum,* in the medulla oblongata.

The fourth ventricle is formed anteriorly by the medulla oblongata, posteriorly and laterally by the cerebellum: hence it is common to both. In it are to be observed—

1. A thin medullary portion connecting the medulla oblongata to the cerebellum, and lying immediately between the

crura, superiorly and above the opening of the iter into the fourth ventricle; this is called the VALVULA MAGNA CEREBRI, or VELUM VIEUSSENII; at the sides of which are two medullary lines called COLUMNÆ VALVULÆ VIEUSSENII, or *processus ad testes.*

2. A plexus of vessels, and apparently small glands, called the PLEXUS OF HALLER.

3. A depressed line extending down the medulla oblongata in the cavity, which is termed the CALAMUS SCRIPTORIUS.

4. Two or three delicate *white lines,* like nerves, which are the origins of one branch of the portio mollis, or auditory nerve.

The VERMIFORM PROCESSES are situated before and behind the crura cerebelli, and are merely a portion of the cerebellum, more protuberant than the rest, whose convolutions are bundled round like a number of small worms.

DISEASED APPEARANCES OF THE CEREBELLUM.—Most of the diseased appearances enumerated under the head *cerebrum* have also been noticed in the *cerebellum,* viz. inflammation —morbid softness—morbid firmness—pulpiness of a part—abscess—hardness of a part—scrofulous tumour—extravasation of blood—hydatids—and also bone in the cerebellum—gangrene.

Fourth ventricle. Water in the ventricle. This is a very rare occurrence; or perhaps the fluid escapes before the cavity can be examined—œdema of the membrane lining it.

MEDULLA OBLONGATA.

A white, firm, medullary substance, situated beneath the cerebrum, and before the cerebellum, and lying upon the cuneiform process of the occipital bone. It is broad and round-

ed above, and narrower below, where it is continued into the medulla spinalis. From its appearance it favours the idea of its being formed by the crura cerebri in its middle, encompassed by the crura cerebelli, becoming flattened as they pass over the former.

If there be any part of the brain in which the fibres, or atoms, all concentrate, it is in the medulla oblongata. Upon its anterior surface are to be observed—

1. The PONS VAROLII, called also *corpus annulare*, which forms the upper and anterior part: it is convex, and covered with many striæ. The basilary artery runs over it.

2. The CORPORA PYRAMIDALIA. Two somewhat pyramidal eminences proceeding from the pons Varolii towards the medulla spinalis.

3. The CORPORA OLIVARIA. Two more oval eminences, one on each side the corpora pyramidalia, from which they are divided by a *sulcus*.

Through the middle of the medulla oblongata, just before the corpora quadrigemina, the *iter à tertio ad quartum ventriculum* is to be noticed.

Three pairs of nerves have been described as originating from the cerebrum; and six more remain to be enumerated, which arise from the cerebellum and medulla oblongata.

1. The *fourth pair*, which are very delicate and long, and are to be seen arising from the valvula magna cerebri.

2. The fifth pair, or *trigemini*, are very large, and proceed forwards from the anterior part of the crura cerebelli.

3. The sixth pair, or *abducentes*, are less than the former, and arise from the lower end of the pons Varolii.

4. The *seventh pair* originate about the fourth ventricle.

5. The eighth, or *par vagum*, proceed from the corpora olivaria by many small branches.

6. The *ninth pair* arise from the sulcus between the corpora olivaria and pyramidalia.

Arteries. The arteries of the cerebrum, cerebellum, and medulla oblongata, are branches of the carotids and vertebral arteries, which unite in the cranium, and form the *circulus arteriosus Willisii*, the basilary artery, the anterior cerebri, and posterior cerebri.

Veins. The veins proceed to the sinuses of the dura mater.

Nerves. The brain has no nerves, but sends off nine pairs.

Use. The use of the cerebrum, cerebellum, and medulla oblongata, is to constitute the sensorium commune, the organ of all the senses.

Diseased appearances of the medulla oblongata. The right inferior eminence of the corpora quadrigemina has been converted into a brownish pulpy substance, which diseased appearance extended a little way internally.

MEDULLA SPINALIS.

The spinal marrow is a continuation of the medulla oblongata, beginning from the great occipital foramen, and passing down the vertebral canal, through the cervical, dorsal, and lumbar vertebræ, where it terminates in a vast number of long nerves, which, from their resemblance to a horse's tail, are called the cauda equina.

It is composed, like the brain, cerebellum, and medulla oblongata, of nervous matter, which is distinguished into medullary and cortical substance; the former is external, and the latter internal.

Throughout its whole course, the spinal marrow is covered by the pia mater, tunica arachnoides, and dura mater; and

there is a ligamentous band in the interstices of the origin of the nerves, from the first cervical to the twelfth dorsal vertebra, called the *ligamentum serratum*, or *denticulatum.*

Thirty pairs of nerves are given off from the spinal marrow in its course along the spine, which are termed spinal nerves.

Of the Action of the Cerebrum, Cerebellum, Medulla Oblongata, and Medulla Spinalis.

The most important functions of an animal body are those of the brain; by its action, all the varied sensations and ideas are formed. In order to explain these accurately, it is necessary to mention a few experiments which have been made upon animals.

Upon dividing, compressing, or tying a nerve, the muscles to which the nerve goes, become paralytic. If the nerve thus divided, compressed, or tied, had any particular sensation, that sensation no longer exists; but upon untying, or removing the compression, its peculiar sense returns.

If the cerebrum, cerebellum, or medulla oblongata, be irritated, dreadful convulsions take place all over the body.

If any part of the brain be compressed, that part of the body is deprived of motion which has nerves from the compressed part.

From these phenomena, it is evident that the cause of every sensation and motion in an animal body arises from the brain and spinal marrow, and that from these parts it is conveyed to every sentient part through the medium of the nerves. Hence it follows, that the nerves are the organs by which the

various sensations are produced. The manner, however, in which the nerves exercise sense and motion; how the will is conveyed from the brain to the different parts; and how, from the different parts, sensations are conveyed to the brain, remains involved in obscurity; several hypotheses have been deduced to explain it, but none appear to be satisfactory. The brain and heart seem connected together, by a direct dependence, and the energy of the brain seems generally in proportion to the quantity of blood received; thus, in deep meditation, a great quantity of blood is sent to the head; on the contrary, a partial abstraction of blood from the brain produces syncopê; a total abstraction, death, &c. (See also the *Physiology of the Nerves.*)

OCULUS.

The eye is the organ of vision, and is situated in the orbits on each side the nose.

The parts which form the eye are divided into external and internal.

The external parts are,

1. The SUPERCILIA, or eyebrows: a layer of hair which begins at the root of the nose, and forms an arch over the eye. Its use is to shade the eye from too strong a light, and defend it from the sweat flowing down the forehead: by means of its muscle it also is corrugated, to express certain passions of the mind.

2. The PALPEBRÆ, or EYELIDS, which are two semilunar productions; covered internally by the conjunctive membrane, and Meibomius's glands, and formed externally by common

integuments and a cartilage: they are extremely moveable, especially the upper. The *glandulæ Meibomianæ* secrete a sebaceous matter, that facilitates the motions of the eyelids, and prevents their accretion during sleep. The cartilage between the conjunctive membrane and the common integuments of the eyelid is semilunar, and termed the *tarsus*. The edges of the eyelids have a number of short hairs arising from them and turned outwards, called *cilia*, or eye-lashes. The use of the eyelids is to cover the eyes during sleep; to defend them from dust and other substances, and too strong rays of light; and to lubricate the conjunctiva by frequently moving its secretion over the surface of the eye.

3. The PUNCTA LACHRYMALIA, two small orifices, one of which is seen at the end of each eyelid near the nose. From these openings, a canal goes downwards and inwards; and meeting about half an inch from their origin, they form a sac, called *saccus lachrymalis*, which is continued downwards through the ductus ad nasum into the nose. The tears are absorbed by the *puncta lachrymalia*, and conveyed into the nose through the sac and canal.

4. The LACHRYMAL GLAND, which is situated in the superior part of the orbit, in a peculiar depression: it is hard, globate, of an oval form, and has a number of excretory ducts which convey the fluid called tears, secreted by this gland, on the surface of the eye.

5. The CARUNCULA LACHRYMALIS, a small red tubercle in the internal canthus of each eye. It has a number of hairs, and secretes a smegma: it is also of use to direct the tears into the puncta lachrymalia.

6. The *plica lunaris*, or *valvula semilunaris*, a membranous duplicature of the tunica conjunctiva, situated between the caruncula lachrymalis and the ball of the eye. In some

birds and quadrupeds it is very large, forming the membrana nictitans.

7. The TUNICA CONJUNCTIVA, or adnata, a transparent vascular membrane, reflected from the edge of one eyelid over the internal part of the eyelid across the bulb, to which it adheres very firmly, and then over the internal part of the other eyelid to its edge. It is more loosely connected with the eyelids than the eye; and where it passes the cornea transparens, it adheres so firmly that it cannot be separated. Its use is to lubricate the eye by the moisture secreted from its transparent arteries.

The internal parts of the eye are termed the bulb; they constitute the eye, properly so called, and are—

1. The SCLEROTIC MEMBRANE. A very firm, hard, white, horny tunic, into which the muscles of the eye are inserted. The anterior part of this coat is glassy and transparent, and projects somewhat; it is called *cornea transparens*, to distinguish it from the other part, which is also termed *cornea opaca*. The optic nerve is inserted into the posterior part of the sclerotic membrane, which appears to be an expansion of its external tunic, continued from the dura mater.

2. Immediately under the sclerotic membrane is a very vascular, soft, and rough membrane, called the MEMBRANA or TUNICA CHOROIDEA. It adheres to the sclerotic from the optic nerve, all around to the edge of the transparent cornea by vessels; but when it arrives here, instead of being continued around the concavity of the cornea transparens, it passes straight downwards and inwards, forming the coloured part of the eye, which is sometimes black, blue, &c. This black or blue part is called the *iris*, which possesses a contractile power, by some supposed to arise from muscular fibres, so as to enlarge or contract the opening in its middle

which is the PUPIL. The edge of the choroid membrane that adheres to the ambit of the cornea transparens, is covered with a white line, to which the name of CILIARY CIRCLE, or LIGAMENT, is given. Some anatomists have supposed the choroid membrane was formed of two laminæ. The posterior surface of the iris is termed the UVEA.

The pupil of a fœtus of six months is covered by a vascular membrane, called MEMBRANA PUPILLARIS. It is continued across from the sides of the iris.

3. The posterior surface of the tunica choroides is covered with a black mucus known by the name of the *pigment* of the choroid membrane and uvea.

4. Upon the inside of the choroid membrane, corresponding to the ciliary circle on the outside, are a number of *white striæ*, which are called CILIARY PROCESSES. The *ciliary circle* and *striæ*, are termed the *corpus ciliare.*

5. There is a whitish, pulpy, vascular membrane, covering the pigment of the choroides, which is the immediate organ of vision, and called the RETINA. It passes forward from the optic nerve, and terminates in the ciliary processes.

The membranes which have been described, are distended with the vitreous humour, crystalline lens, and aqueous humour.

1. The VITREOUS HUMOUR, *substance* or *body*, is a soft, round, and very transparent substance, filling the whole hollow surface of the retina. It has a cavity in its anterior surface, and is surrounded with a delicate membrane, called the *hyaloid membrane*, which sends a number of laminæ, internally forming cells; and these cells are distended with a transparent fluid. The hyaloid membrane sends off an external lamina, which accompanies and attaches itself to the retina: this is termed the zonula ciliaris, from its circular form: be-

tween this ciliary zone and part where the hyaloid membrane adheres to the capsule of the crystalline lens, a passage is formed, called the *canal of Petit.*

> In order to exhibit the capsule of this humour, suffer an eye to get putrid, then carefully let out the vitreous humour by an opening through the other membranes. Place it on a card, so that the lens be uppermost; then, with a curved needle, puncture that part of the capsule which lies on the card. The fluid will gradually ooze out; then with a blowpipe, passed between the card and capsule, throw in air, which will immediately distend it. By passing the needle up to the capsule of the lens, and puncturing it, you may distend also the capsule of the crystalline lens.

2. The CRYSTALLINE LENS lies in the depression in the anterior part of the vitreous humour. It is a solid, transparent, lentiform body, like ice, and is enclosed in a capsule, called the capsule of the crystalline lens.

3. The AQUEOUS HUMOUR is very fluid and transparent, and fills the space between the crystalline lens and the cornea transparens, or chambers of the eye.

The space between the anterior surface of the crystalline lens and posterior surface of the transparent cornea, has the iris hanging like a curtain in its middle, dividing it into two spaces: these spaces are distinguished by the name of ANTERIOR and POSTERIOR CHAMBERS.

VESSELS. The arteries of the eye are the ophthalmic, central artery of the optic nerve, and the ciliary arteries: these convey their superfluous blood into small *veins*, which at length form the ophthalmic vein, a branch of the external jugular.

NERVES. The *optic nerve* is entirely lost in the retina. The eye has also the ophthalmic nerve of the fifth pair,

and another branch of the third pair, which form a *ganglion* that supplies the bulb.

The MUSCLES of the eye-ball are described in *Myology*.

USE. The use of the eye is to receive, refract, and unite the rays of light into a focus, and paint the objects on the *retina*. See *Vision*.

DISEASED APPEARANCES.—*Eyebrows*. Eyebrows wanting, called *madarosis*.

Eyelashes. A double set, called *distichiasis*.

Eyelids. A growing together, called *anchyblepharum*—adhesion to the globe of the eye, called *symblepharum*—inflammation, or *blepharophthalmia* — *œdema* — *emphysema* — *atheroma*—*sarcoma*—scirrhus—cancer—*hordeolum*, or stye—a pellucid vesicle, or hydatid—warts—a turning outwards of the eyelid, or *ectropium*—a turning inwards, or *entropium*—a thickening of the margin, or *tylosis*.

Lachrymal passages. Obstruction of the ducts—dropsy of the saccus lachrymalis—fistula lachrymalis—tumour on the outside of the sac, or *anchylops*.

Caruncula lachrymalis. An enlargement, or excrescence, called *encanthus*—wanting, or *rhyas*.

Conjunctive membrane. Inflammation, or *ophthalmia*—vesicles, or *phlyctenæ*—a hard tubercle adhering to it, or *papula*.

Cornea transparens. A morbid thickness and opacity, or *staphyloma*—abscess, or *onyx*—too great a convexity, causing shortness of sight, or *myops*—too flat, causing *presbyops*, or long sight.

Bulb of the eye. Cancer—a protrusion, or *ophthalmoptosis*.

Iris. No pupil, or *synezesis*.

Aqueous humour. Pus instead of water, or *hypopium*—a white humour, or *hypogala*.

Crystalline lens. Cataract, several species.

Vitreous humour. A turbidness, or *glaucoma*.

Retina. Inflammation.

OPERATIONS PERFORMED ON THE EYE. Removal of excrescences—operation for fistula lachrymalis—syringing the lachrymal passages—operation for cataract—extraction and couching—removal of a cancerous eye.

AURIS.

The ear is the organ of hearing. It is distinguished into the external and internal ear.

The *external ear* is formed of an oval cartilage, covered with common integuments; it is concave before, and convex behind, and has several eminences and depressions, viz.

1. The external ridge is called the *helix*; it curls inwards. 2. The *antihelix*, a ridge situated more internally than the helix. 3. The *concha*, or cavity, bounded by the antihelix and tragus. 4. The *tragus*, a cartilaginous eminence, covered with long hairs. 5. The *antitragus*, a small depression opposite to the tragus, at the bottom of the antihelix. 6. The *lobule* of the ear, which hangs downwards, and is bored for rings. 7. The *cavitas innominata*, situated between the helix and the antihelix. 8. The *scapha*, or *fossa navicularis*, situated between the anterior bifurcation of the antihelix.

The bony meatus auditorius of the ear is lined by a cartilage and common integuments, between which are the glands that secrete the wax. This canal, the *meatus auditorius externus*, is terminated by a membrane of the tympanum.

The external ear has several muscles and ligaments, which have been described.

The *internal ear* lies concealed within the petrous portion of the temporal bone; it is divided into the tympanum, mastoid cells, and labyrinth.

The TYMPANUM is an irregularly round cavity, covered by a muscle, called the membrana tympani, like a drum by its parchment. It contains four delicate bones, the *malleus, incus, stapes,* and *os orbiculare,* and some muscles belonging to them; the *chorda tympani,* and the membrana tympani. It is every where, even the bones, covered with a very vascular membrane, and has several openings, which, with the mastoid cells, are described in the *Osteology.*

The MASTOID CELLS are considered with the temporal bone in the *Osteology.*

The LABYRINTH is composed of the cochlea, vestibulum, and semicircular canals; these have also been noticed in the *Osteology.* There remain, however, to be described the soft parts which are found within them, and which form the organ of hearing: these are—

1. The MEMBRANOUS SEMICIRCULAR CANALS, which are situated within the bony semicircular canals, and loosely connected to their periosteum by a fine cellular membrane, a quantity of fluid being interposed, which circulates through the labyrinth. Each of these membranaceous semicircular canals proceeds from the vestibule, and at its commencement swells into an oval AMPULLA; these oval ampullæ originate from a membranaceous sacculus within the vestibulum, which is termed the ALVEUS COMMUNIS. This sacculus, the ampullæ, and membranaceous canals, therefore, occupy the vestibulum and osseous semicircular canals; and it is by means of the alveus communis that the membranous canals all communicate with one another, they being, as it a were, tubes going from the sacculus. They are distended by very limpid fluid, called the water of the labyrinth. The arteries

of the labyrinth arise by one or two twigs, chiefly from the vertebral artery. The small veins terminate in the end of the lateral sinus.

2. The auditory nerve is expanded upon the sides of the alveus communis and ampullæ, in a beautiful manner, like a fan or beard, resembling very much the mucous expansion of the optic nerve in the form of the retina. There is one more evident expansion of the nerve adhering to the spinous process of the vestibule, which is termed the BARBULA.

3. The ZONA MOLLIS of the cochlea, composed of two substances: the one is of a consistence between cartilage and membrane, somewhat of a coriacious texture; the other is perfectly membranous, and almost of a mucous consistence. The former adheres very firmly to the spiral lamina of the cochlea, which it accompanies throughout; and the latter, which appears to be formed of a duplicature of the periosteum, is continued from the coriacious part to the side of the cochlea, so that it completes the septum dividing the cochlea into two scalæ.

4. The auditory nerve divides at the internal meatus; one branch, or portion, goes to supply the vestibule and semicircular canals; the other part proceeds to the cochlea, and terminates by a vast number of fibres, which proceed through bony canaliculi of the modiolus, and come out on the zona mollis, forming a beautiful NERVOUS PULP.

PHYSIOLOGY OF HEARING.

Hearing is a sensation by which we perceive the sound of any sonorous body.

Sound is a tremulous motion of the air excited by striking any sonorous body. Sound is conveyed to an enormous distance in the atmosphere, in straight lines, which are called

sonorous rays. Soft bodies diminish or stifle sound; elastic ones increase it.

The *organ* of hearing is the portio mollis of the seventh pair of nerves, whose pulp is beautifully distributed upon the *ampullæ* of the membranous semicircular canals, the *barbula*, and the *zona mollis* of the cochlea.

Hearing is *performed* in the following manner: the rays of sound emanating from a sonorous body arrive at the ear, which, by its elasticity and peculiar formation, concentrates them, that they may pass along the external auditory foramen to the membrana tympani, which they cause to vibrate. The trembling tympanum communicates its vibrations to the malleus, which is in contact with it: the malleus conveys them to the incus, the incus to the os orbiculare, and the os orbiculare to the stapes.

The basis of the stapes jets within the vestibulum, in that part where, as in a centre, it looks towards the common channel of the membranous semicircular canals, and the orifice of the scala vestibuli; therefore the sonorous vibrations of the stapes are communicated to the water of the labyrinth, and the undulations, sent out from this part as from a centre to a circumference, strike first the alveus communis, and are then propagated throughout the liquor of the labyrinth which surrounds the membranous semicircular canals. These undulations strike the membranous semicircular canals on their whole surface, and the canals agitate the fluid they contain as well as that in the alveus communis; and these agitations now affect the nervous expansions in the alveus communis and membranous semicircular canals. One scala of the cochlea opens into the vestibulum, whilst the other begins from the fenestra ovalis: both scalæ are filled with the water of the labyrinth, and communicate with each

other at the apex of the cochlea; so that the sonorous vibrations are communicated also to the scalæ of the cochlea. In the middle between the scalæ of the cochlea, is the zona mollis, on which the nerve is also spread; hence the undulations are communicated to the nerves of the cochlea. In all these actions of the auditory nerve, namely, in that of the ampullæ of the semicircular canals, the alveus communis, and the spiral zone of the cochlea, hearing consists. The auditory nerve conveys these vibrations to the sensorium, where the mind is informed of the presence of sound, and judges of its difference. Gravity and acuteness of sound depend upon the number of vibrations given at the same time.

NOSE.

The nose is a prominence of the face, between the eyes and mouth.

It is divided into the external nose, properly so called, and an internal one. The former is distinguished into root, back, apex, and alæ: the latter into two nostrils, five cartilages, the frontal, ethmoidal, and maxillary sinuses.

1. The *root* is the superior part, contiguous to the forehead.

2. The *back*, or *bridge*, is the middle prominence, which goes downwards.

3. The *alæ*, or *pinnæ*, are the lateral and moveable parts.

4. The *apex*, or *tip*, is the inferior round part.

5. The cartilages of the nose are, one in the middle, which, with the vomer, completes the *septum narium*, and two on each side of the septum, which form the round tip, and opening into the nostrils.

6. The *frontal sinuses*: these communicate with the superior part of the nostrils.

7. The *sphenoidal* sinus, which opens into the posterior nostrils.

8. The *maxillary* sinuses, which open into the anterior nostrils at their sides.

9. Besides these parts, the nostrils have the *turbinated portions* of the ethmoid bone, and the inferior spongy bones, hanging within them.

10. The *opening* of the ductus ad nasum.

All these parts are covered with a very vascular PITUITARY MEMBRANE, called the SCHNEIDERIAN, from its discoverer, upon which the excretory ducts of the mucous glands open, and the olfactory nerves are beautifully distributed, so that the pituitary membrane not only covers the nostrils, but the sinuses communicating with them.

The nostrils terminate anteriorly in the face, and posteriorly in the fauces.

ARTERIES. The arteries of the internal soft parts are branches of the internal maxillary and internal carotids.

VEINS. The veins terminate in the orbital, temporal veins, which convey their blood to the internal jugular.

NERVES. Besides the olfactory nerves, the nose is supplied by the ophthalmic nerve, and superior maxillary.

USE. The nose is the organ of smelling; and it assists in respiration and speech.

The *physiology of smelling* is delivered under the functions of the nerves. See page 200.

DISEASED APPEARANCES. Inflammation of the mucous membrane, called *catarrhus*—ulceration, called *ozena*—morbid thickening—polypus—obstruction in the ductus ad nasum—an adventitious opening through the lachrymal bone—abscess of the antrum.

Operations performed on the nose. Syringing the ductus ad nasum—removing polypi—passing a hollow tube through the nostril into the œsophagus—perforating the antrum of Highmore—plugging up the nostrils in cases of hæmorrhage.

MOUTH.

The cavity of the mouth is covered by the cheeks and lips.

The *cheeks* are composed of common integuments, and various muscles going downwards from under the eye, over the superior maxillary, to the inferior maxillary bone.

The *lips* are composed of common integuments and muscles, and are highly vascular, which gives them that beautiful redness in health. Where the lips meet together, it is called the *angles*, or *commissure* of the lips.

Opposite to the incisores of the upper and under jaw, the doubling of the membrane of the mouth forms a frænum.

Arteries. The arteries of the lips are the coronary and angular arteries. Those of the cheeks are branches of the inferior orbital, alveolar, and facial arteries.

Veins. The veins empty themselves into the external jugular.

Nerves. The nerves are the *infra-orbital*, the *labial* nerve, a branch of the inferior maxillary, and the *facial*.

These nerves are sometimes the seat of the *tic doloureux*.

The cavity of the mouth is bounded superiorly by the hard and soft palate, inferiorly by the tongue, anteriorly and laterally by the teeth, and posteriorly it is open, communicating with the fauces: so that the gums, the palate, the velum pendulum palati, and the membrane covering these, are to be considered here.

1. The GUMS, a red, vascular, spongy substance, of a p culiar nature, encompassing the necks of the teeth, and lyin on each side the alveolar processes.

The edges of the gums have the power of secreting th tartar sometimes found upon the teeth.

When the gums bleed, are more spongy than ordinary, and ulcerate along their margin, they cause a fetor of the breath, and the disease is called *stomacace*.

The gums are often the seat of abscess, called *epulis*, or gumboil.

They occasionally shoot out a very vascular productio or *fungus*, difficult to cure.

2. The PALATE. The roof of the mouth is called the palat ; the anterior portion is much harder than the posterior, bei partly formed of bone, and hence distinguished into hard and soft palate. The hard palate is that portion of the roof which is formed by the palate bones, and palatine portions of the superior maxillary bones : it is covered with periosteum and the common membrane of the mouth, which is formed into *rugæ*. The soft palate, or VELUM PENDULUM PALATI, extends backwards from the hard palate, forming two arches : it is composed of the internal membrane of the mouth, a number of glands and muscles. From the middle of the velum pendulum palatinum there hangs down, over the tongue, a conical body, like a nipple, seen when the mouth is opened, which is the UVULA. From the sides of the uvula, towards the sides of the tongue, the soft palate forms two arches : the anterior of these is fixed to the sides of the tongue, but the posterior extends backwards to be inserted into the pharynx. Between these two arches, on each side, at their bottom, is an oblong gland, called the tonsil ; it has several excretory ducts opening upon its surface.

The hard palate is seldom found diseased; but the soft palate, uvula, and tonsils, are quite the reverse. Inflammation—ulceration—relaxation—enlarged tonsils—tonsils filled with a sebaceous substance—tonsils perforated—complete loss of the soft palate, are amongst the most frequent diseased appearances.

3. The *membrane* covering the mouth, is a reflection of the skin and epidermis; it is very spongy and cellular, having a number of small glands under it, and their excretory ducts opening upon its surface.

It is subject to inflammation, which, about the tonsils and soft palate, is called *cynanche tonsillaris*, and gangrene in those parts called *cynanche maligna.*

The salivary glands, whose excretory ducts pour the saliva into this cavity, are considered in *Adenology*.

The mouth is the organ of mastication and deglutition. It also affords a passage to the air in breathing, and assists in forming the sounds for speaking.

PHYSIOLOGY OF MASTICATION.

Mastication is the comminution of the food between the teeth, effected by the jaws, the tongue, cheeks, and lips. The powers which move these parts are their various muscles, by which the lower jaw is pulled from the upper, and again brought to it, whilst the tongue perpetually puts the food between the teeth, and the cheeks and lips impede it, when masticated, from falling out of the mouth. By this process the food is divided, lacerated, and, as it were, ground, and mixed with the saliva, mucus of the mouth, and the atmospherical air, and thus rendered fit to be swallowed and digested; so that mastication is, in fact, an incipient digestion.

TONGUE.

A muscular body, moveable in every direction, and situated in the inferior part of the mouth.

It is divided into a base, body, back, an inferior surface, and two sides.

The *base* is that part which lies on the os hyoides.

The *body* is the middle and larger part, which ends in the more moveable part.

The superior surface is called the *back:* on it are to be noticed the opening of several glands.

The *inferior surface* is connected to the parts below by the membrane of the mouth, which forms a bridle, or FRÆNULUM behind the middle incisores.

The tongue is formed of a number of muscular fibres, which are considered in *Myology,* covered by the common integuments.

The external surface is every where furnished with NERVOUS PAPILLÆ, some of which are pyramidal, others conoid, and some fungiform; they are divided into three classes, the *maximæ, mediæ,* and *minimæ,* and are most numerous on the sides and apex, and upon the middle of the back.

At the root of the tongue a hole is found, called *foramen cæcum,* it penetrates only a small way into the substance of the tongue, and receives the mouths of excretory ducts. A line extends along the middle of the tongue, which divides it into two surfaces.

ARTERIES. This organ is plentifully supplied with arteries, which come off from the carotid, and are termed ranine, or lingual.

VEINS. The smaller veins empty themselves into the great lingual vein, which proceeds to the external jugular.

NERVES. The nerves of the tongue are also numerous, arising from the fifth, eighth, and ninth pairs.

USE. The use of this viscus is to constitute the organ of taste, and assist in chewing, swallowing, sucking, and tasting.

The *physiology of tasting* is delivered under the functions of the *nerves*. See page 202.

DISEASES OF THE TONGUE. Inflammation, called *glossitis* —abscess, when it appears under the tongue, it is called *ranula*—gangrene—ulceration; small white ulcers are called *aphthæ;* besides common ulcers, there is a species of ulceration along the sides, of a chronic nature—cancer—frænum too short; when the person is said to be tongue-tied—small vesicles on the sides of the tongue, or hydatids.

OPERATION. The clipping the frænum when too short.

NECK.

The parts which form the neck are divided into external and internal.

The *external parts* are the common integuments, the muscles of the neck, eight pair of cervical nerves, two carotid arteries, two vertebral arteries, two external jugular veins, two internal jugular veins, the jugular glands, the thyroid gland, the eighth pair of nerves of the cerebrum, and the great intercostal.

The *internal parts* are the fauces, pharynx, œsophagus, larynx, and the trachea.

FAUCES.

The cavity behind the soft palate and tongue, which ends in the pharynx.

It is bounded posteriorly by the bodies of all the cervical vertebræ, superiorly by the cuneiform process of the os occipitis,

and middle of the sphænoid bone, inferiorly by the pharynx, and anteriorly it looks into the mouth.

The posterior nostrils open into the fauces behind the velum pendulum palati.

There are also, at the sides of the fauces, the openings of the Eustachian tubes.

The whole of this cavity is lined with a very vascular and mucous membrane, continued from the mouth and nostrils, on which are the opening of many mucous glands.

ARTERIES. The arteries of this cavity come from the internal maxillary, and neighbouring branches.

VEINS. The veins evacuate their blood into the external jugular.

NERVES. The nerves are branches of the fifth and eighth pairs.

USE. The use of the fauces is for deglutition, respiration, speech, and hearing.

DISEASES OF THE FAUCES. Inflammation, or *cynanche tonsillaris*—ulceration; which may be either simple, venereal, or aphthæ—polypus hanging from the nostrils—obstruction of the Eustachian tubes—anasarca, or *angina œdematosa.*

OPERATIONS. Removal of the nasal polypus when in the fauces—syringing the Eustachian tubes.

PHARYNX.

The pharynx is a muscular sac, like a funnel, situated behind the larynx, adhering to the fauces, and terminating in the œsophagus.

CONNEXION. It is connected by means of muscles, with the cranium, vertebræ, and os hyoides.

Use. Its use is to receive the masticated food, and convey it into the œsophagus.

ŒSOPHAGUS.

The œsophagus, or gullet, is a membranous and muscular tube, situated between the pharynx and stomach, and descending behind the trachea, down the neck, and along the posterior space of the mediastinum into the abdomen.

It is composed of three tunics, or coats—

1. A *common tunic*, which is a condensed cellular membrane.

2. A *muscular one*, which consists of very dilatable muscular rings.

3. A *villous coat*, situated on the inside: between this and the former tunic are a number of muciparous glands, which secrete the mucus of the œsophagus.

Arteries. Branches of the aorta.

Veins, empty themselves into the vena azygos, and the superior intercostal.

Nerves, from the eighth pair and great intercostal.

Use.—The œsophagus conveys the food into the stomach.

Diseases. Inflammation, or *œsophagitis*—coagulated lymph thrown out on the internal surface—ulceration—contraction—scirrhus—cancer—converted into cartilage—fungus—pouched.

Operations. Œsophagotomy, or cutting into the œsophagus—introduction of the probang—the introduction of a flexible hollow tube, to convey any stimulating substance into the stomach, to recover drowned persons—caustic bougies, to remedy stricture.

PHYSIOLOGY OF DEGLUTITION.

Deglutition is the conveying of the masticated food from the cavity of the mouth into the fauces, and from the fauces

through the œsophagus into the stomach. This is performed by the jaws shutting, so as to prevent the food from falling out of the mouth; the tongue is then applied to the palate, by which the food, lying upon the back of the tongue, is pressed into the cavity of the fauces, where it is received by the dilated pharynx. The mucus, secreted by the tonsils, facilitates its passage. The pharynx then is irritated to contract, by which the food is expelled into the œsophagus, by the contraction of whose muscular fibres it is conveyed through the cardia into the stomach.

The pharynx is dilated by its dilatory muscles, and by the root of the tongue, os hyoides, and larynx, being drawn forwards and backwards by their proper muscles.

The food is prevented, during the act of swallowing, from passing into the posterior opening of the nostrils, the Eustachian tube, and larynx, by the velum pendulum palati, and uvula being pressed against the former, and the epiglottis being bent backwards over the glottis.

When a fluid is to be drank, the head inclines backwards, the same actions take place, and the fluid passes on each side of the epiglottis.

Solids are swallowed with much more facility than fluids: the latter, from their divisibility, require the organs to be more closely applied, and to compress the body, to be swallowed with greater exactness.

During deglutition, the food is covered with the mucus of the fauces and œsophagus.

LARYNX.

A hollow body, composed of cartilages, muscles, and ligaments, situated at the root of the tongue, in the fore-part of the neck.

It is attached above to the os hyoides by muscles and ligaments, and posteriorly to the basis of the tongue by membranes, and to the pharynx by various muscles.

The cartilages which form the larynx are the following :—

1. The THYROID, or *scutiform*, which forms the anterior and superior part, and by far the greater part of the larynx. It appears to consist of two cartilages, joined together anteriorly and forming a projection in the male neck, called the POMUM ADAMI, but receding from each other in the posterior part. At the upper end of each posteriorly is a little projection ; these are termed the *cornua* of the thyroid cartilage ; they are joined to the cornua of the os hyoides by ligament.

There are also two projections situated at its inferior part : these are called the inferior cornua, and are fixed to the cricoid cartilage.

2. Two ARYTENOID CARTILAGES, which are found behind the former, placed perpendicularly upon the cricoid, and forming a space between them, called the GLOTTIS, or *rima glottidis*, which is the opening into the larynx.

3. The CRICOID CARTILAGE, which is the basis of the others : it is narrow before, and broad behind ; and is immediately above the larynx.

4. The EPIGLOTTIS, an oval cartilage, at the root of the tongue, which covers the glottis when the food passes into the pharynx.

There are four *ligaments* of the glottis:—a ligamentous cord passes from each arytænoid cartilage forward, to be fixed to the anterior angle of the thyroid cartilage ; under these two ligaments there are two others of a larger size, they have the same origin and insertion as the former. On each side, between the superior and inferior ligament, is a fissure, which Galen has termed *ventricles of the larynx*.

The larynx is every where covered with a very sensible, vascular, and mucous *membrane*, a continuation of the membrane of the mouth.

The larynx is variously contracted and dilated by *muscles*, which are considered in *Myology*.

ARTERIES. The arteries of the larynx are given off from the external carotid and subclavian. The *veins* evacuate their blood into the external jugulars.

NERVES. It has nerves from the eighth pair, or *par vagum*.

GLANDS. The thyroid gland covers the thyroid cartilage. There are also the mucous glands of the larynx, which, with the thyroid gland, are considered in the *Adenology*.

USE. The use of the larynx is to form the voice and its various modifications, and to afford a passage to the air into, and out of, the lungs.

DISEASES. Inflammation of the pituitary membrane, or *laryngitis*—ulceration—enlargement of the epiglottis—ossification of the thyroid and cricoid cartilages.

OPERATION. The introduction of a flexible hollow tube to throw air into the lungs, for the recovery of drowned persons.

PHYSIOLOGY OF THE VOICE.

The voice is caused by the sound of the air propelled through the glottis; so that the organ of the voice is the larynx and its muscles.

The shrillness and roughness of the voice depends on the diameter of the glottis, its elasticity, mobility, and lubricity, and the force with which the air is expelled: thus, when the diameter is increased, the voice is more bass, and *vice versa*.

The two arytenoid, and the thyroid cartilages only, take an active part in the production of the voice, but the true organ

of voice is the aperture of the glottis; for, if the trachea, or larynx, be laid open below this aperture, no voice can be produced. In women and youths the glottis is more narrow by one-third than in man: hence the shrill, acute voice of the former, and grave voice of the latter.

Speech is the modification of the voice in the cavity of the mouth and nostrils.

Singing is the harmonic modulation of the voice.

Ventriloquism consists in the motion of the uvula, epiglottis, and fauces, by which the sounds are modulated without the lips, teeth, or palate. The mouth being nearly shut, and the voice resounding between the larynx and the cavity of the nose, the sound is returned, as if emitted by some one at a distance.

TRACHEA.

A tube which descends from the larynx in the anterior part of the neck, before the œsophagus, into the thorax, where it divides into two branches, called bronchia.

It is composed of cartilages, muscles, and membranes:

1. The CARTILAGES are round, but not complete rings, for they are fleshy posteriorly, where they lie over the œsophagus.

2. The MUSCLES of the trachea pass between these rings, and are called MESOCHONDRIAC. They are of two kinds:

α. *Musculi mesochondriaci longitudinales.* These are composed of muscular fibres, which go directly downwards from one cartilage to the next, throughout the minutest ramifications of the bronchia.

β. *Musculi mesochondriaci transversales.* A number of muscular fibres, which go across from one end of the cartilage to the opposite.

Spasmodic asthma very frequently, the author believes, proceeds from a spasmodic affection of these muscles.

3. The internal surface of this tube is lined with an exquisitely sensible and vascular mucous *membrane*, continued from the larynx.

The external coats are a cellular, and a ligamentous coat.

The BRONCHIA, entering the substance of the lungs, divide into innumerable little branches, which terminate in the *vesiculæ pulmonales*, or air-cells.

The GLANDS are described in *Adenology*.

BLOOD-VESSELS. The arteries and veins of the trachea are common with the larynx.

It has nerves from the recurrent branch of the eighth pair.

USE. The use of the trachea is to admit the ingress and egress of the air into the lungs.

DISEASES. Inflammation of the mucous membrane, or *cynanche trachealis*, which is of two kinds:

1. A high state of inflammation, known by seeing an immense number of red vessels, which are not found in a healthy state.

2. A specific inflammation, known by the formation of an adventitious membrane, formed of coagulated lymph, and sometimes without any apparent increase of red vessels.

Ulceration—diseased state of the softer parts, from scirrhus, and cancer of the œsophagus—polypus—scirrhus—ossification.

OPERATION. Tracheotomy, more frequently called bronchotomy, to admit of respiration.

THORAX.

The thorax, or chest, is that part of the body which is situated between the neck and belly, and to whose sides the upper extremity is attached.

The thorax is in figure pyramidal; broad and convex below, where it is separated by the diaphragm from the abdomen; and obtuse above, where it is terminated by the pleura, cellular structure, muscles, and vessels; hollow behind, owing to the convexity of the ribs as they approach the spine; convex laterally; somewhat flattened in front.

The cavity of the thorax is divided internally into five cavities:—

1. Into a right and left cavity of the thorax.
2. Into the cavity of the pericardium.
3. Into the anterior space of the mediastinum.
4. Into the posterior space of the mediastinum.

The parts which constitute the chest, are divided into external and internal—

The external parts are the common integuments, the breasts, various muscles, and bones.

The internal parts, or *viscera*, of the thorax are, the pleura, the lungs, the thymus gland, the œsophagus, ductus thoracicus, arch of the aorta, branches of the venæ cavæ, the vena azygos, par vagum, and great intercostal nerves.

Diseases. Besides the affections of the thoracic viscera, this part is subject to *empyema*, or a collection of pus in the lateral cavity—*hydrothorax*, or water in the chest—a collection of pus in the anterior space of the mediastinum.

Operations.—*Paracentesis thoracis*, for empyema and hydro-thorax—trepanning the sternum, to give an exit to the pus collected in the anterior space of the mediastinum—taking up the intercostal artery.

MAMMÆ.

The breasts are two soft hemispheres, adhering to the anterior and lateral parts of the chest, over the pectoral muscle. In the male, the breasts are termed *mamilæ;* in women, *mammæ;* and in brutes, *ubera.*

STRUCTURE. The human breast is composed of much soft fat, which gives it the rotundity, and is of a glandular fabric, plentifully supplied with blood-vessels, nerves, &c. which secrete the milk, and convey it by its excretory ducts to

The PAPILLA, or nipple, a very irritable prominent body, in the centre of each breast, in which the excretory ducts of the glands of the breast, called *galactopherous* and *lactiferous ducts*, open.

The nipple is surrounded by a brown circle, called the AREOLA, or *halo.*

ARTERIES. The arteries of the breasts are branches of the internal and external mammaries, many of which anastomose with the epigastric artery. The veins bear the same name, and accompany the arteries, emptying their blood into the subclavian and axillary vein.

NERVES. The nerves are very numerous, and arise from the superior intercostals, which are given off from the dorsal nerves.

GLANDS. The breasts are plentifully supplied with lymphatics, which proceed to the subaxillary glands.

USE. The use of these organs is to secrete and contain the milk for new-born infants.

DISEASES. Inflammation, or *mastitis*, or *mastodynia*—scirrhus—cancer—induration of the glandular fabric.

OPERATIONS. Opening of mammary abscess—removal of cancerous breast.

PLEURA.

A transparent smooth membrane, which lines the internal surface of each lateral cavity of the thorax, and covers its viscera. Its external surface is attached by vessels and cellular membrane to the ribs, intercostal muscles, sternum, bodies of the dorsal vertebræ and diaphragm; so that it may be compared to two bags: the right lies close to the internal surface of the ribs, down to the diaphragm, passes over it, giving it a tunic; and having reached the heart-bag, near the middle of the inferior part of the chest, it adheres to it, and goes up to the sternum, to the very top of the chest, where the bronchia enter, and the lungs begin; and in this part the pleura is reflected over them:—the left bag lines the left cavity in the same way. The pleuræ of both cavities at the sides of the bodies of the vertebræ go directly forwards to the sternum, without coming into contact with one another, a vast quantity of cellular structure being interposed, and thus divide the thorax into a right and left cavity. This partition of the chest is termed *mediastinum*, in which are two spaces: the anterior space is directly behind the sternum; the posterior immediately before the bodies of the dorsal vertebræ.

Arteries. The pleura has arteries from the intercostals and internal mammaries, which, in a healthy state, are not visible; they return their blood by the intercostal and internal mammary veins.

Nerves. The nerves of this membrane are few, and arise from the superficial branches of the cardiac plexus.

Use. The use of the pleura is to form the mediastinum, to divide the thorax into two cavities to render the surface moist by the vapour it exhales, and to give a membrane to the lungs and pericardium.

DISEASES. Inflammation, called *pleuritis*—adhesion to the lungs—converted into cartilage—ossified—small white bodies in the pleura, like scrofulous glands.

OPERATIONS. Perforating the pleura for empyema and hydrothorax.

MEDIASTINUM.

The membranous partition formed of a duplicature of the pleura, which divides the chest into two cavities.

In the mediastinum, that is, between the two pleuræ of which it is formed, are—in the anterior part, the pericardium, the thymus gland in children—in the posterior part, the œsophagus, the bronchia, the large vessels of the heart, the par vagum, great intercostals, and thoracic duct.

LUNGS.

Two viscera, situated in the cavities of the thorax, by which we breathe.

DIVISION. Into right and left lung: the right has three *lobes*, the left only two.

The substance of the lungs is bronchial, vesicular, vascular, nervous, glandular, and parenchymatous.

1. The BRONCHIA are continuations of the trachea, and are formed exactly of the same materials, viz. cartilage, and intercartilaginous muscles.

2. The vesicles of the lungs are called the PULMONARY or AIR VESICLES; they form by far the greater bulk of the lungs, and are placed at the very extremities of the ramifications of the bronchia, being apparently formed of the internal membrane lining the bronchia. It is on the internal surface of

these vesicles that the pulmonary artery forms a beautiful plexus of delicate vessels.

3. The VESSELS of the lungs are—the pulmonary artery, whose ramifications are very numerous, forming a net of vessels on the internal surface of the air-vesicles—the pulmonary veins, which return the blood from the pulmonary arteries—the bronchial artery, which nourishes the lungs, and returns its blood through corresponding veins into the vena azygos—the absorbents of the lungs, which are deep seated and superficial.

4. The NERVES of the lungs are derived from the par vagum and great intercostal, and form an anterior and posterior pulmonic plexus.

5. The GLANDS about the bronchia are very numerous, and termed bronchial. Lymphatic glands are also found more internally.

6. The PARENCHYMA of the lungs, or cellular membrane, connects the vessels, bronchia, and vesicles, and is very elastic.

CONNEXION. The lungs are connected with the heart by means of the pulmonary artery and veins, and with the trachea by means of the bronchia; the other part is loose in the cavity of the chest, having a coat from the pleura, called *pleura pulmonalis*, which invests their tunica propria, but does not dip down between the lobules.

USE. The use of the lungs is for respiration and sanguification.

DISEASES. Inflammation, called *pulmonitis*—abscess, called *vomica*—tuberculated—scirrhus—air-cells enlarged—converted into a substance like liver—earthy matter in the lungs—ossification—hydatids—pleura pulmonalis inflamed; covered

with a coat of coagulated lymph—thickened—cartilaginous—ossified—adhering to the pleura costalis.

PHYSIOLOGY OF RESPIRATION.

Respiration consists of INSPIRATION, or the ingress of the air into the lungs, and EXPIRATION, or the egress of the air from the lungs.

During sleep, respiration is performed without our knowledge, and therefore termed *spontaneous*; but when it can be augmented or diminished according to our will, it is termed *voluntary*. The blood of the right side of the heart is blackish and heavy: that which the pulmonary veins bring back to the left side of the heart, is, on the contrary, of a red vermillion colour, lighter and two degrees warmer. In its passage through the lungs it is deprived of hydrogen and carbon, and in becoming arterial, is loaded with oxygen and caloric. In natural respiration the thorax dilates about fifteen times in the course of a minute, and in an adult man, from thirty to forty cubic inches of atmospherical air enter the lungs, composed of seventy-three parts nitrogen, twenty-seven parts oxygen, and 1-100 or 2-100 of carbonic acid; after the atmospheric air has remained some moments, it is expired, and its composition is found to be altered; 73-100 of nitrogen exists, but the oxygen has suffered great diminution, its proportion is only 14-100: carbonic acid constitutes the remaining 13-100, and sometimes one or two parts of hydrogen, besides a quantity of aqueous vapour.

The *exciting cause* of respiration is the air rushing into the lungs, and irritating its nerves, which irritation is, by consent of parts, communicated to the diaphragm and intercostal muscles, and compels them to contract. The contraction of

the intercostal muscles and diaphragm, and the pressure of the elastic air, therefore dilate the chest. The air being deprived of its stimulus, the intercostal muscles and diaphragm become relaxed, the cartilages of the ribs and abdominal muscles, before expanded, return to their former state, and thus the air is expelled from the lungs. The small branches of the pulmonary artery form a beautiful *net-work of vessels* on the internal membrane of the air-vesicles. During expiration, the air-vessels collapsed; consequently the blood-vessels become tortuous, and the blood is prevented passing; but in inspiration, the air-vesicles being dilated, the tortuous vessels are elongated, and a free passage afforded to the blood. The very delicate coats of these vessels are rendered so thin as to suffer a CHEMICAL ACTION to take place between the air in the vesicles and the blood in the vessels. This constitutes the primary use of respiration, viz. the blood absorbing the oxygen from the atmospheric air, as was before mentioned; by which the nervous energy is increased, and, it is generally believed, heat generated;—but this subject is yet undetermined.

PERICARDIUM.

A membranous sac surrounding the heart.

CONNEXION. It adheres to the diaphragm, pleura, sternum, cartilages of the ribs, œsophagus, aorta descendens, and the veins and great arteries going to and from the heart.

ARTERIES. Branches of the internal mammary and mediastinal.

VEINS, empty themselves into the internal mammary.

NERVES. From the superficial cardiacs.

USE. To contain the heart, and to separate a fluid which

may lubricate and preserve it from concretion with the pericardium.

DISEASED APPEARANCES. Inflammation—a coat of coagulated lymph on the internal membrane—adhesions to the heart—dropsy of the pericardium, or *hydro-cordis*—scrofulous tumours adhering to the pericardium—pericardium wanting.

ADULT HEART.

The heart is a hollow muscular viscus, situated in the cavity of the pericardium, by whose contractile power the blood is sent to every part of the body.

It is distinguished, in the dead body, whilst in the pericardium, into an anterior and posterior surface and margins; a base from which the large arteries emerge, and an apex.

In the living body, the base of the heart is towards the dorsal vertebræ; its apex towards the sixth rib of the left side; so that its situation is oblique, not transverse; the right ventricle being anterior, the left posterior, and the inferior surface lying upon the diaphragm.

DIVISION. The heart is distinguished into two auricles, which lie upon its base surrounding the larger arteries; two ventricles, or cavities, in the internal part; and the arteries and veins going from and terminating in it.

The auricles have been distinguished into the *auricula* or proper auricle, and *sinus venosus.*

The RIGHT AURICLE is a large muscular sac, in which the superior and inferior vena cava terminate: it has a little process, or *cul de sac,* like an *auricula,* or little ear, from which it took its name, and an opening at its bottom into the right ventricle.

In the right auricle are the following:

1. The *tuberculum Loweri.* A mere projection in the auricle, between the two venæ cavæ.

2. The *valve of Eustachius.* A production of the inner membrane of the inferior vena cava, at its termination in the auricle. It is not always present, but in most instances is as complete a valve as any other.

3. The fleshy bundles crossing the auricle, like the teeth of a comb, called *musculi pectinati.* Between these fasciculi the auricle is transparent and membranous.

4. The *valve of the great coronary vein,* which opens into this auricle.

5. Around the opening of the auricle into the right ventricle, and rather within the auricle, is a *tendinous circle.*

6. A *flat, membranous, oval depression,* more remarkable in some than in other hearts: which points out the former situation of the foramen ovale. It is termed the *fossa ovalis,* and its sides are called *columnæ foraminis ovalis; isthmus Vieussenii;* and *annulus fossæ ovalis.*

7. The *foramina Thebesii;* which are seldom seen. They are the minute openings, probably arteries opening into the right auricle.

The RIGHT VENTRICLE is a large cavity within the heart, and below the auricle. The right auricle opens into it, and a large artery, the pulmonary artery, emerges from it. In this cavity are to be noticed—

1. The muscular pillars or columns, called *carneæ columnæ,* which cross one another in every direction, and have deep grooves between them.

The coagulating lymph of the blood, improperly called *polypi,* insinuates itself very frequently, *in articulo mortis,* between the *carneæ columnæ,* and thus adheres very firmly to the parietes of the ventricle. The same thing occurs in the right auricle and left ventricle.

2. The *cordæ tendineæ*, which connect some of the carneæ columnæ with the valves, and insert others into the parietes of the heart.

3. The *tricuspid*, or *triglochin* valves, which arise from the tendinous circle, around the opening of the auricle, into the ventricle, and form three points, which are fastened by the cordæ tendineæ to the parietes of the right ventricle.

4. The reticulated appearance of the carneæ columnæ, and the smooth surface leading to the artery.

5. Three semilunar valves placed just within the pulmonary artery. In the middle of each valve is a hard knot, called *corpus sesamoideum Aurantii.*

The LEFT AURICLE is not so capacious as the right; it has no communication with it in a natural state; yet the *foramen ovale*, which is always open in the fœtus, sometimes remains throughout life, or is forced open. The four pulmonary veins open into this cavity. It presents the fasciculated appearance, or musculi pectinati, though not so strongly as the right auricle. The opening of this auricle into the ventricle is less than that of the right auricle, but it is surrounded by a tendinous circle in the same way.

The foramen ovale, or opening between the auricles of the fœtus, which permits the blood to pass from the right auricle into the left, in consequence of its not having a passage through the lungs, before birth, is sometimes forced open in the adult. This happens generally to those who have asthma or phthisis pulmonalis, or some disease of the lungs affecting respiration, so as to prevent the free circulation of the blood through the lungs from the right ventricle to the left auricle. The blood, therefore, accumulating in the right auricle, distends it more than commonly, and the pressure causes an absorption of the tender membrane which closed the foramen ovale. In this manner the foramen ovale is formed in adults, but it not unfrequently remains open from birth: hence the blood continues to be cir-

culated when the respiration is suspended, as in diving, holding the breath, &c.; and hence the circulation of the blood is regular, notwithstanding the respiration is obstructed in asthma, and the substance of the lungs corrupted, become scirrhous, or almost wholly ulcerated; which is the case in phthisis pulmonalis.

The LEFT VENTRICLE is less than the right; its fleshy walls, or parietes, are much stronger; and it has, like the right, an opening from the auricle, and an artery arising from it. In this ventricle we observe—

1. The valve arising from the circle of the auricular opening, which terminates in two fasciculi of tendons, and hence is called, from its resemblance to a bishop's mitre, *valvulæ mitrales.* The two points are connected to the carneæ columnæ.

2. The carneæ columnæ are here remarkably strong and rounded, and the cordæ tendineæ very firm.

3. The smooth surface towards the arterial opening.

4. The semilunar valves, just within the artery, or aorta, with the corpora sesamoidea in their middle.

5. The sinuses of Vasalva at the outside of the valves; they exist in the pulmonary artery, but are smaller.

From this description of the heart, it appears that the auricles are separated from each other, and also the ventricles. The partition between the auricles is thin and partly membranous, but that between the ventricles is about half an inch in thickness, and composed of strong fleshy fibres. The former is termed *septum auricularum,* the latter *septum ventriculorum.*

STRUCTURE. With regard to the structure of the heart, it is entirely muscular and well supplied with vessels; its cavities are lined by a smooth and very irritable membrane, continued from the internal coat of the arteries and veins, and its

external surface is covered by a reflexion of the internal tunic of the pericardium.

The muscular fibres constituting the heart, may be distinguished into three layers:

1. The *outermost*, which extends from the basis of the heart towards its apex, surrounding the whole heart.

2. The *middle layer*, which lies below the former, and passes in a transverse direction. It is by means of this layer that both ventricles appear to be formed.

3. The *internal layer*, which runs very irregularly, its fibres interlacing one another.

Vessels. The heart is nourished with blood by two *arteries*, branches of the aorta, called *coronaries*, which return their blood by the *coronary vein*, into the right auricle. They also ramify on the roots of the large arteries, forming the vasa vasorum.

Nerves. It has nerves from the cardiac plexus formed of branches from the par vagum and great intercostal; but these nerves are not under the influence of the mind, the heart being a muscle of involuntary motion.

Absorbents. The heart has absorbents, which accompany the direction of the arteries.

Use. The use of this viscus is to constitute the primary organ of the blood's motion.

Diseases. Inflammation—abscess—gangrene—pus, and coagulated lymph in the cavities—aneurism of the ventricle—hydatids in the ventricle—rupture—malformation—unusually large—an immense accumulation of fat about the heart—ossification—a deposition of earthy particles in the muscular structure—inflammation of the external membrane—a coat of coagulated lymph on it; sometimes like a honey-comb—ossification—hydatids adhering to it—pus upon the surface

—adhesions to the pericardium—a morbid thickening—valves ossified—earth deposited in them—thickened—burst—valves between the auricles and ventricles thickened—ossified—earthy—the internal membrane of the heart of a florid colour—gangrenous—the coronary arteries ossified—converted into a cartilaginous substance.

Almost every disease of the heart causes an irregularity in its action; therefore an intermittent pulse mostly accompanies diseases of this viscus: but as the heart often beats irregularly in consequence of the blood not being duly returned to it, as in asthma and hydrothorax; and as it often contracts irregularly from sympathy, and as the pulse may beat irregularly in consequence of disease between the heart and the wrist; an intermitting pulse cannot be considered as a pathognomonic symptom of a disease of this organ.

CIRCULATION OF THE BLOOD.

The blood is continually in motion, passing from the auricles of the heart into the ventricles; from the ventricles into all the arteries of the body, and from the arteries into the veins, which return it again to the auricles.

The blood is brought from every part of the body to the heart by the two venæ cavæ, (the superior bringing it from the head, upper extremities, and thorax, and the inferior from the abdomen and inferior extremities,) which terminate in the right auricle. The right auricle, when distended with blood, contracts, and empties itself into the right ventricle; the right ventricle then contracts, and propels the blood into the pulmonary artery, the opening between the ventricle and auricle being shut by the tricuspid valves. The pulmonary artery conveys the blood, by its numerous ramifications, into the small branches of the air-cells of the lungs, where it un-

dergoes a change, and passes into the veins, which bring it by four trunks into the left auricle of the heart. It is prevented returning from the pulmonary artery into the right ventricle, by the three semilunar valves which are placed at its origin. The blood having thus passed through the lungs, and become of a florid colour, distends the left auricle, which is then stimulated to contract, and pours the blood into the left ventricle. The left ventricle next contracts, and propels the blood through the aorta, to be conveyed by its branches to every part of the body. The mitral valves, which are placed at the auricular opening into the left ventricle, prevent the blood from returning, when the ventricle contracts, into the auricle; and, should the blood be prevented by any impediment passing immediately along the aorta, the three semilunar valves placed at its origin prevent its regurgitating into the ventricle. From the numerous arteries of the aorta the blood is conveyed into the veins, where it loses its florid colour, becomes darker, and is conveyed by the two venæ cavæ, the superior and inferior, into the right auricle.

Since the blood loses its florid hue as it passes from the arteries into the veins, and again acquires it only in the lungs, it follows that the blood of the right auricle and ventricle, and also the pulmonary artery, is of a *dark venal colour;* and that of the pulmonary veins, left auricle and ventricle, and aortal system, of a *florid hue.*

The above circumstance naturally induces the following observation: that when blood is expectorated of a florid hue, it comes from a ruptured *vein;* and when dark and grumous, from the pulmonary *artery.* As the bronchial artery ramifies through the parenchyma of the lungs, when it ruptures, an ecchymosis of the lung is the consequence.

The action of the heart consists in the alternate contraction and dilatation of its auricles and ventricles. After the contraction of the ventricles, the arteries contract, this action of arteries is called *pulsation*, the veins receive the blood from the arteries, and return it to the auricles: the valves of the veins and *vis à tergo* prevent the blood regurgitating. The dilatation of the heart is termed *diastole*, and the contraction *systole*.

The excessive sensibility of the membrane which lines the auricles and ventricles, disposes them to contraction, which is effected by the irritation of the stimulus of the blood, and by that of the distention of its cavities.

ABDOMEN.

A cavity situated between the thorax and pelvis; divided into several regions, as has already been mentioned. The EXTERNAL PARTS are the common integuments, five pair of abdominal muscles, and the peritoneum. The INTERNAL PARTS, OF VISCERA, are: the omentum, stomach, small and large intestines, liver, gall-bladder, mesentery, lacteal vessels, spleen, pancreas, kidneys, supra-renal glands, part of the aorta descendens, and vena cava ascendens.

MORBID APPEARANCES. The diseased appearances of the viscera will be enumerated under their respective heads. The cavity of the abdomen is subject to *ascites abdominalis*, and a complete adhesion between all its viscera, so as totally to obliterate the cavity.

Parts of the viscera have protruded through the umbilicus, inguinal ring, diaphragm, &c. forming various species of *herniæ*.

Operations. *Paracentesis abdominis*, to remove the fluid in dropsy, and the operation for strangulated, umbilical, inguinal, and femoral herniæ.

PERITONEUM.

A smooth delicate membrane lining the internal surface of the abdomen, and covering all its viscera.

Connexion. It is connected, by means of cellular membrane, with the diaphragm, abdominal muscles, vertebræ of the loins, bones of the pelvis, urinary bladder, uterus, intestinum rectum, and all the viscera of the abdomen.

Vessels. The arteries and veins come from the adjoining parts.

Use. To contain and strengthen the abdominal viscera, and to exhale a vapour to lubricate them.

Morbid appearances. An accumulation of the fluid thrown out to lubricate the viscera, constitutes *ascites abdominalis*.—*Coagulable lymph* is often separated into the abdomen in large quantities by the vessels of the peritoneum—pus also has been observed. Inflammation of the peritoneum is termed *peritonitis*. The other diseased appearances are: adhesion, thickening, dark spots on the peritoneum; a white, soft, granulated matter adhering to the peritoneum; cancerous tumours, hydatids, air in the cavities of the peritoneum, or *tympanitis*.

Operations. *Paracentesis abdominis*, to remove the fluid in dropsy; and *gastroraphia*, or sewing of the abdomen.

OMENTUM.

The omentum, or epiploon, is an adipose membrane, a production of the peritoneum, attached to the stomach, and lying on the anterior surface of the intestines.

Division. It is divided into *large* and *small* omentum. The *former* hangs pendulous from the great curvature of the stomach. The small omentum fills up the space between the small curvature of the stomach and liver.

Immediately behind the biliary ducts there is an opening in the omentum, which will admit the finger, called the *foramen of Winslow.*

Arteries. The omentum is supplied with arteries by the cœliac artery.

Veins. The veins empty themselves into the vena portæ.

Use. To lubricate the intestines, and to preserve them from concretion.

Diseased appearances. Inflammation, which is called *omentitis,* or *epiploïtis*—bony and earthy matter in the omentum—scirrhous enlargement like a bunch of grapes—contracted omentum—adhesions with various parts. When the omentum passes through the parietes of the abdomen, the rupture is termed an *epiplocele.*

Operation. The removal of a gangrenous portion, either from strangulated hernia or rupture of the abdomen.

STOMACH.

A membranous receptacle, situated in the epigastric region, which receives the *ingesta* from the œsophagus.

Division. It is divided, when empty, into an anterior and a posterior surface; a great and little curvature; the *cardia,* or superior opening; and the *pylorus,* or inferior opening.

Connexion. It is connected with the œsophagus, duodenum, omentum, and pancreas.

Structure. It is composed of three membranes, or coats, viz. a peritoneal, muscular, and villous coat. Some anatomists enumerate a fourth, viz. a nervous coat.

ARTERIES. The arteries of the stomach are branches of the cœliac—the *coronaria*, which goes to the small curvature—the *gastrica sinistra*, which is distributed to the great, and arises from the splenic artery—*gastrica dextra*, which passes to the great curvature—and the *pylorica*, supplying the pylorus; all of which unite with each other, and form a net-work of blood-vessels.

VEINS. The gastric veins empty themselves into the vena portæ, corresponding with the trunks of the arteries.

NERVES. The nerves of the stomach are branches of the par vagum.

ABSORBENTS. Those of the small curvature terminate in the thoracic duct, where the cœliac artery is given off, and those passing along the great curvature join with the absorbents of the spleen.

GLANDS. These are muciparous, under the internal tunic.

USE. To receive the *ingesta* from the œsophagus, and to retain, mix, digest, and expel it into the duodenum.

DISEASED APPEARANCES. Inflammation, which is termed *gastritis*—ulceration—scirrhus—cancer—partly dissolved by gastric juice—tumour filled with a suetty substance in the stomach—calculi in the stomach—hernia of the stomach, termed *gastrocele*—abscess between the peritoneum of the parietes and stomach, bursting in the latter—coagulated lymph thrown out in the stomach—pouch formed in the stomach—a morbid contraction of the whole stomach—worms in the stomach.

DIGESTION.

Digestion, or *chymification*, is that change the food undergoes in the stomach, by which it is converted into chyme,

The circumstances necessary to effect a healthy digestion of food are—

1. A certain degree of *heat* of the stomach.

2. A free mixture of *saliva* with the food in the mouth.

3. A certain quantity of healthy *gastric juice.*

4. The natural *peristaltic motion* of the stomach.

5. The *pressure* of the contraction and relaxation of the abdominal muscles and diaphragm.

From these circumstances, the particles of the food are softened, dissolved, diluted, and intimately mixed into a soft pap, called chyme, which passes through the pylorus of the stomach into the duodenum, where the nutritious part is separated from it and absorbed by the lacteals. See *Chylification.*

INTESTINES.

The membranous tube, six times longer than the body, in the cavity of the abdomen, variously contorted from the pylorus of the stomach to the anus.

Division. The intestines are divided into small and large intestines. The small are,

1. The duodenum, which begins at the pylorus of the stomach, and is reflected over the spine under the peritoneum. It is about twelve fingers-breadth in length, and has an oblique perforation near its middle, which is the common opening of the pancreatic duct and ductus communis choledochus.

2. The jejunum and ileum compose the remainder of the small intestines.

The small intestines always hang from the mesentery, the greater part of them into the cavity of the pelvis. There is no material alteration of structure in any part of them: the ter-

mination of the one and beginning of the other is imaginary. The jejunum constitutes the first half from the duodenum, the other half is ileum. The small intestines have internally a number of annular folds, which augment the surface for the situation of the lacteal and other vessels; these are called *valvulæ conniventes*, and are peculiar to the small intestines; they are most numerous in the duodenum, and least so in the ileum.

The *large* intestines are distinguished into,

1. The CÆCUM, which lies upon the right hip over the iliacus internus muscle, to which it is attached by cellular membrane: it is a large *cul de sac:* the small intestine opens obliquely into it, in such a manner as to form a valve to impede the return of the fæces; and nearly opposite to this valve there arises from the cæcum a small vermiform canal, imperforated at its extremity, called the *appendicula cæci vermiformis*. The valve is called *valvula coli*, and *valula Tulpii*.

2. The ascending portion of the large intestine is the COLON; it proceeds towards the liver by the name of the *ascending portion of the colon*, and having reached the liver, forms a *transverse arch* across to the other side. The colon then descends, forming what is termed its *sigmoid flexure*, into the pelvis, where the gut is termed.

3. The RECTUM, which terminates in the anus.

The large intestines are lobulated; have sometimes little fat portions adhering to them, called *appendiculæ epiploïcæ*, and also three longitudinal *bands* upon their external surface.

STRUCTURE. The intestines are composed of three membranes, or coats; one peritoneal, a muscular one, and the third which is villous.

CONNEXION. They are connected with the mesentery, kidneys, os coccygis, and urinary bladder, and, in women, with the vagina.

Arteries. The arteries of the intestines are branches of the superior and inferior mesenteric, duodenal, and internal hæmorrhoidal.

Veins. The veins run into the meseraic, which go to the vena portæ.

Nerves. The intestinal nerves are productions of the eighth pair and intercostals.

Lacteal vessels. These arise from the small intestines, and run into the mesenteric glands.

Glands. Muciparous, under the villous coat, called *glandulæ Brunneri.*

Use. To receive the chyme, and retain it for a time; to mix it with the enteric juice and bile; to separate and propel the chyle into the lacteal vessels; and to eliminate the fæces.

Diseased appearances. Inflammation, which is called *enteritis*—ulceration—mortification—abscesses—intus-susception—stricture—scirrhus—cancer—a morbid thickening of the coats of the intestines—a morbid transparency of the intestine—the inner membrane of the large intestine formed into white and yellow tubercles—the folds of the inner membrane of the great intestine enlarged and loaded with blood—small processes of the inner membrane a little above the anus—hæmorrhoids—pouches in the small intestines—worms; ascaris vermicularis, ascaris lumbricoides, trichuris, tænia osculis superficialibus, and tænia osculis lateralibus—thickening of the valvulæ conniventes—calculi in the intestines—lacteals morbidly distended with chyle—small tubercles hanging from the intestines into the cavity of the abdomen—adhesions of all the intestines into one mass.

Operations. Operation for strangulated intestinal hernia and wounds of the intestine.

CHYLIFICATION.

This is the change of the chyme in the small intestines into chyle. The chyme in the duodenum is mixed with the pancreatic juice, the bile, and enteric juice; from which mixture, effected by the continual peristaltic motion of the intestines, a milk-like fluid is separated, termed chyle, which is absorbed by the pendulous openings of the lacteals, and conveyed through the mesentery into the thoracic duct, to be sent into and mixed with the blood, to form new blood: after the bile has effected this purpose, its oily, bitter and colouring principle adheres to the excrementitious mass, and gives it stimulant properties.

Chylification is performed quicker than chymification, and both are effected within three hours. The progress of alimentary matter in its passage through the small intestines, is much retarded by the winding of the canal; which allows the chylous part to be entirely separated.

The excrementitious particles of the food, called the fæces, facilitated in its progress by a great quantity of mucus, secreted by the inner membrane of the intestines, are propelled into the cæcum, through the colon, where they acquire a peculiar smell, into the rectum, to be expelled.

EXPULSION OF THE FÆCES.

The irritation of the fæces in the rectum induces it to contract, the diaphragm descends, and the muscles of the abdomen push the abdominal viscera towards the pelvis, compressing the intestines; the sphincter relaxes, and the fæces are protruded through the aperture of the anus, by the pressure of the abdominal muscles, and the anus closed again by the

contraction of its sphincter and levator muscles. The fœtid smell of the fæces depends on the commencing putrefactive fermentation, a great evolution of sulphurated hydrogen takes place, &c.

MESENTERY.

The mesentery is a membranous production, formed of two laminæ of peritoneum; between which are a quantity of cellular or adipose membrane, numerous glands, lacteals, lymphatics, arteries, veins, and nerves.

DIVISION. It is distinguished into, *mesentery*, which adheres to the three superior lumbar vertebræ, and has the small intestines hanging to it; *mesocolon*, which supports the colon; and *mesorectum*, a portion in the pelvis, inclosing the rectum.

ARTERIES. The mesenteric arteries are branches of the aorta; they pass within the duplicature of the mesentery to the intestines.

VEINS. The veins accompany the smaller ramifications, but convey their blood into the vena portæ.

NERVES. The nerves of the mesentery are from the par vagum and great intercostals; they form a number of plexuses, which send off twigs to the intestines.

GLANDS. The glands are very numerous: the lacteals proceed from the intestines into these glands, and from them to the thoracic duct.

USE. The use of the mesentery is to sustain the intestines and afford them a peritoneal coat, and to give a passage to the mesenteric vessels, lacteals, and nerves.

DISEASES. Inflammation of its laminæ, called *peritonitis mesenterii*—thickening of the laminæ of the mesentery—in-

flammation of the mesenteric glands called *mesenteritis*—abscess—scirrhus—scrofulous enlargement—cancer—earthy deposit in the glands—ossification—*emphysema*, or in the mesentery—anasarca of the mesentery—aneurism of the mesenteric artery—hydatids adhering to the mesentery—a puckering or contraction of the mesentery.

LIVER.

The liver is the largest of all the abdominal viscera; it is of a deep red colour, and situated in the right hypochondriac region, and somewhat in the epigastric, hanging by its ligaments from the diaphragm.

The liver is convex above and concave below; it is extremely broad superiorly, but gradually becomes thinner inferiorly, and ends in a thin margin. Its surfaces are smooth, being covered by the peritoneum, which forms its several ligaments, viz. two which are attached to the diaphragm, and are termed *lateral*; in the middle of its lower and anterior margin is a *round ligament* adhering to the navel, through which the umbilical vein, &c. of the fœtus passes: between the round ligament and the diaphragm is another, called the *suspensory ligament*, which adheres to the peritoneum of the anterior part of the abdomen.

Division. Into three *lobes*, one of which is very large, the other smaller, and a third, which is very small, and called after its describer, *Spigelian*, or *lobulus Spigelii*. There are also two other lobes described by some anatomists, viz. the *lobulus caudatus*, which is only a projection at the root of the lobulus Spigelii; and the *lobulus anonymus*, of a square shape, placed between the passage of the round ligament, and the gall-bladder.

FISSURES. The *fossa umbilicalis*, between the right and left lobes; the *sinus portarum*, or *sulcus transversus*, where the vessels of the liver enter. The *fossa ductûs venosi*, situated between the left lobe and lobulus Spigelii, and the fossa for the inferior cava between the great lobe and lobulus Spigelii.

SUBSTANCE. The liver is a gland composed of arteries, veins, nerves, lymphatics, and excretory ducts, united together by a particular substance: there is also an appendage on the concave surface of the liver, called the gall-bladder.

The *artery* of the liver is the hepatic, which nourishes it: the blood it conveys, does not appear to contribute any thing towards the formation of bile. It is returned into the venæ cavæ hepaticæ.

The *vena portæ* is a large vein which conveys the blood from the spleen, mesentery, and stomach, into the liver. As it enters the liver, it receives a strong tunic, which is termed the capsule of Glyson: it then divides into innumerable branches, which, at their very minute ends, form an immense number of vessels, arranged like the hairs of a pencil brush, and hence called PENICILLI. These penicilli constitute the glandular fabric and bulk of the liver. From each penicillus arises a small duct which runs to a larger; this again unites with others, till at length they form vessels of a considerable size, which ultimately end in one duct. The smaller ducts are termed *pori biliarii*, and its trunk *ductus hepaticus*. The small branches of the vena portæ open also into corresponding veins, which gradually become larger, and return the blood into the vena cava at the superior part of the liver: these are called *venæ cavæ hepaticæ*.

From this description of the substance of the liver, the physiology of its functions may be explained. The liver is destined to separate bile from the blood. The blood is brought

for this purpose by three large venal trunks from the stomach omentum, spleen, large and small intestines, which three trunks become one; the vena portæ, which conveys blood to its penicillated ends, which penicilli, or glands, separate bile from it; and the bile passes into the beginnings of the pori biliarii, and along them into the ductus hepaticus. The blood which is not wanted for this purpose, and that from which bile has been separated, then passes into the venæ cavæ hepaticæ; so that the vena portæ takes on the action and function of an artery, and, like an artery, its branches gradually become smaller.

The *nerves* of the liver are very numerous, arise from the hepatic plexus, and go into the substance of the liver with the hepatic artery.

The *absorbents* of the liver are superficial and deep-seated; the former are always seen very beautifully arborescent on the peritoneal coat; they pass through the diaphragm, and over the gall-bladder to the thoracic duct.

Diseased appearances. Inflammation of the peritoneal coat—general adhesions—partial conversion into cartilage—ossification—abscess between the peritoneum of the liver and integuments—inflammation of the liver, called *hepatitis*—abscess—mortification—tubercles of several kinds—morbid flaccidity—morbid firmness—general contraction—hydatids—cysts containing calcareous matter—worms in the pori biliarii.

GALL-BLADDER.

An oblong membranous receptacle, situated under the liver, to which it adheres very firmly in the right hypochondrium.

Division. It is divided into bottom, body, and neck, which terminates in the ductus cysticus.

The *ductus cysticus* arises from the gall-bladder, proceeds towards the duodenum, and unites with the *ductus hepaticus*, to form the *ductus communis choledochus*, which perforates the duodenum, and conveys the bile into the intestines.

Structure. The gall-bladder is composed of three membranes, a common, fibrous or muscular, and villous.

Arteries. The arteries of the gall-bladder, are branches of the hepatic.

Veins. These empty themselves into the vena portæ.

Absorbents. The absorbents of the gall-bladder are very numerous, and run into glands near the duodenum. Those of the under surface of the liver pass over the gall-bladder.

Nerves, from the eighth pair and intercostals.

Glands, muciparous, and are placed under the internal coat.

Use. To retain the gall, which regurgitates from the hepatic duct, there to become thicker, more bitter, and acrid, and to expel it, when wanted, into the duodenum.

Diseased appearances. Inflammation — adhesions — scirrhus—ossification—morbidly transparent—morbidly thickened—gall-stones—hydatids—stricture of the ducts—pouch in the gall-bladder.

SPLEEN.

A spongy, somewhat oblong viscus, of a blueish red colour, situated in the left hypochondrium, near the fundus of the stomach, under the ribs.

Connexion. It adheres to the omentum, diaphragm, pancreas, and colon.

ARTERY. The splenic artery is a branch of the cœliac.

VEINS. The veins of the spleen empty themselves into the vena portæ.

ABSORBENTS. The lymphatics of the spleen are deep seated and superficial, but are rarely seen.

NERVES, from the par vagum and great intercostal.

USE, unknown.

PANCREAS.

A glandular body, of a long figure, compared to a dog's tongue, situated in the epigastric region, under the stomach.

STRUCTURE. It is composed of innumerable small glands the excretory ducts of which unite and form the pancreatic duct.

Its external membrane is from the mesocolon.

ARTERIES, from the neighbouring parts and splenic artery.

VEINS, evacuate themselves into the splenic.

The *pancreatic duct* perforates the duodenum with the ductus communis choledochus, and conveys its secretion into the intestines.

USE. To secrete a humour similar to saliva, and carry it into the duodenum.

DISEASED APPEARANCES. Inflammation—morbid softness—morbid hardness—abscess—calculi of the pancreas—worms—pancreas wanting.

LACTEAL VESSELS.

The absorbent vessels of the mesentery, which convey the chyle, a milk-like fluid, from the intestines into the thoracic duct.

They *originate* from the surface of the duodenum, jejunum, and ileum, and *terminate* in the thoracic duct, or trunk of the absorbents, which runs near the aorta on the spine, and empties its contents into the jugular vein.

As they run through the mesentery, they pass through a number of glands, in which the chyle is altered, and then proceed to their trunk.

USE. To carry the chyle from the intestines into the blood.

DISEASED APPEARANCES. Lacteals distended with inspissated chyle—rupture of the lacteals.

KIDNEYS.

Two somewhat oval viscera, situated behind the sac of the peritoneum, near the bodies of the superior lumbar vertebræ, which secrete the urine.

DIVISION. Into three kinds of substances: a *cortical*, which is external and very vascular; a *papillous*, which ends in several *papillæ* or nipples in the pelvis; a *tubular*, which goes from the cortical to the papillous substance: each papilla is surrounded by a membranous tube, termed *infundibulum*, or *calix*: these unite and form a hollow part called the *pelvis* of the kidney, lined by a smooth membrane; this cavity gives off the ureter.

INTEGUMENTS. Adipose membrane, and a membrana propria.

ARTERIES. The renal arteries, or emulgents, are branches of the aorta descendens; they ramify very beautifully in the substance of the kidney, and terminate in CRYPTÆ, or convolutions of the artery upon itself.

VEINS. The veins empty themselves into the cava inferior.

NERVES. The nerves of the kidneys are branches of the eighth pair and intercostal.

The excretory ducts of the kidneys are called the URETERS; they are the tubes which convey the urine from the kidneys into the bladder, and originate from the pelvis of the kidney, which is sometimes called also the pelvis of the ureter.

USE. To secrete urine, and convey it to the bladder.

DISEASED APPEARANCES. Inflammation—abscess—gangrene—morbid softness—scirrhus—hydatids—converted into an earthy matter—calculi in the pelvis of the ureter—ossification—total destruction of the kidney by enlargement of the pelvis of its ureter—ulcerated surface of the pelvis of the kidney—kidney converted into cysts, or hydatids.

EXCRETION OF THE URINE.

The urine is separated from the blood by the extremities of the renal arteries, or *cryptæ*, which open in the substance of the kidney into the *tubuli uriniferi*, from whence it is received into the pelvis of the ureter, and passes along the ureter into the urinary bladder *guttatim*, where it usually remains a few hours, in consequence of the sphincter of the bladder being contracted. It is prevented returning into the ureters by their entrance being oblique and valvular. Although the urine may be accumulated in the bladder, so as to press on the inferior parts of the ureters, yet the force is not sufficient to prevent the further distention: for the column of fluid descending through the ureters, is higher than that contained in the bladder.

During the retention of the urine in the bladder, it becomes thicker, and of a higher colour, from the absorption of its more fluid parts. The urine remains a longer or shorter time in the bladder, in proportion to its capacity, irritability, and extensibility; influenced also by the varied stimulant

properties, that the urine may contain. The urine having remained a few hours in the bladder, excites a desire to void it, by which stimulus the sphincter becomes relaxed, the muscular structure of the bladder contracts, and by the assistance of the abdominal muscles, and the acceleratores urinæ, the urine is propelled along the urethra.

SUPRA-RENAL GLANDS.

Renal capsules. Renal glands.

Two triangular flat bodies, situated one above each kidney.

They are covered by a proper membrane, and anteriorly by the peritoneum. In a healthy state, they have a small cavity, in which there is a brownish fluid. They are plentifully supplied with arteries from the diaphragm, aorta, and renal arteries; from which circumstance, one would suppose they were to answer some purpose in the animal economy, although unknown. Their veins pass into the cava and renal vein, and their absorbents and nerves are in common with those of the kidneys. No excretory duct has yet been detected, nor is their use known.

Diseased appearances. The supra-renal glands are frequently found containing a black aqueous fluid—inflamed—enlarged—filled with scrofulous abscesses—converted into a spongy substance, whose cells are distended with an aqueous fluid, containing small calculi of various forms and colour.

PELVIS.

The pelvis is a cavity below the abdomen, and under the pubes, containing the urinary bladder, rectum, and organs of generation.

VESICA URINARIA.

The urinary bladder is a membranous sac in the pelvis without the peritoneum, which in part gives it a coat, or tunic. It is situated, in men, between the pubes and rectum; in women, between the pubes and uterus, being fixed at its anterior and inferior part, to the arch of the pubes, by its neck, and the urethra.

Division. Anatomists divide the urinary bladder into a *fundus*, which is loose in the abdomen, and, when the bladder is distended, reaches the navel, and even the stomach; a *neck*, before which the prostate gland is placed in men; and a *body*, or that part composing the chief bulk of the bladder, distinguished by an anterior and posterior part and sides.

The anterior half of this dilatable base is connected inferiorly, in man, to the rectum, and in women, to the uterus; its middle part to the bones of the pelvis, by means of cellular membrane and muscular fibres; and its superior part is attached loosely to the muscles of the abdomen. There is also a round ligament, which proceeds from the middle of the fundus of the bladder, between the peritoneum and linea alba, to the umbilicus, which is called the *urachus*.

Structure. It is composed of three membranes, like the intestines, one peritoneal, a muscular coat, and a villous.

ARTERIES. Its arteries are branches of the hypogastric and hæmorrhoidal.

VEINS. The veins empty themselves into the hypogastric.

NERVES. The nerves of the bladder are branches from the intercostal and sacral nerves.

Its internal surface is lubricated by mucus separated from muciparous glands under its internal coat.

USE. The use of the bladder is to receive, retain, and expel the urine brought into it by the ureters, which perforate its inferior part, near the neck of the bladder.

DISEASED APPEARANCES. Inflammation—scirrhus—cancer—gangrene—ulceration—fungous and cancerous excrescences—polypus—puckering of the internal membrane—muscular fibres, concentrated into bundles—morbid contraction—pouches of the bladder—calculi of various kinds in the bladder—enlarged openings of the ureters—hydatids in the bladder—ascarides in the bladder.

OPERATIONS. Lithotomy—puncturing the bladder in suppression of urine—passing the catheter into the bladder—vesicæ lotura.

THE MALE ORGANS OF GENERATION.

These are, the penis, testicles, and vesiculæ seminales.

PENIS.

The penis, called also *membrum virile*, or yard, is that cylindrical part which hangs down under the mons Veneris, before the scrotum.

DIVISION. It is divided into root, body, and head, called *glans*.

The hairy prominence which covers the pubes, is called MONS VENERIS.

SUBSTANCE. The penis consists of common integuments, two corpora cavernosa, the corpus spongiosum urethræ, and the urethra.

1. The CORPORA CAVERNOSA, which form the chief bulk of the penis, are composed of a cellular and very elastic substance, and arise by two crura, one from each ascending ramus of the ischium. At their origin, they are firmly attached to the bone by a dense cellular membrane; they then converge towards the pubis, where they are also firmly connected to the symphysis by a dense cellular membrane. About this place, they meet their elastic ligamentous substance together, and, in consequence of several perforations in this *ligamentum pectinatum*, adhere; and there is a free communication between the cells of one corpus cavernosum and those of the other: thus adhering together, they form the greater part of the penis, and end abruptly behind the *corona glandis*. The corpora cavernosa, being each somewhat round, and lying together in the penis, a considerable excavation is left above and below; in the former the great vein of the penis passes, and in the latter the corpus spongiosum urethræ.

2. The CORPUS SPONGIOSUM begins before the prostate gland, and surrounds the urethra. At its beginning, it forms the bulbous part of the urethra, and then proceeds forwards in the space between the two corpora cavernosa on the under surface, and is expanded at the extremity of the penis into a very vascular substance, called GLANS PENIS, naturally covered by a fold of the skin, called the *prepuce*, which, at the under-part of the glans, is fixed to it by a *frænum*.

3. The URETHRA is a membranous canal, which proceeds from the bladder, through the prostate gland and the corpus spongiosum urethræ; and at the end of the glans penis its internal membrane is reflected over the glans, forming the meatus, or opening in the glans. The urethra is endowed with a high degree of sensibility and contractility.

In the urethra are to be observed,

1. The *verumontanum*, or *caput gallinaginis*, a cutaneous eminence in the urethra, about an inch before the neck of the bladder.

2. The openings of the ejaculatory ducts around the caput gallinaginis.

3. The opening of the ducts of the prostate and Cowper's glands.

4. The *lacunæ* or openings of the ducts of the mucous glands of the urethra.

GLANDS. Muciparous — odoriferous — Cowper's glands — and the prostate. (See *Adenology*.)

ARTERIES. The penis is supplied with blood by the pudical artery, which is continued to the symphysis of the pubis, where it pierces the cavernous substance: it divides into several branches, one going to the bulb of the urethra, another along the dorsum of the penis, and two branches enter the cells of the corpora cavernosa.

VEINS. The blood of the penis is returned by a large vein, called the *vena magna ipsius penis*, which conveys it to the hypogastric vein.

ABSORBENTS. The lymphatics of this organ are deep-seated and superficial. The *superficial* arise from the prepuce in three divisions: one on the right side of the frænum, another on the left, and a third directly on the middle of the superior side. Those from the under side make a semicircular

turn from the under to the upper side of the penis, whilst that on the superior side of the prepuce, runs on the middle of the back of the penis, exactly in the direction of the symphysis pubis. At a little distance from the pubis the three divisions unite into one common trunk, which almost immediately separates again into two; one, going to the right groin, accompanies the veins going to the inguinal vein, and terminates near it, in those inguinal glands which are nearest the symphysis pubis. The other trunk goes to the left groin, and terminates exactly in the same manner as the former. The *deep-seated* lymphatics accompany the arteries, and pass with them on the inside of the tuberosities of the ischia, or under the angle of the pubis.

Nerves. Branches of the sacral and ischiatic. Those distributed on the integuments and body of the penis, are for common sensation; those which go to the *glans penis* are for the peculiar sense of that part.

Use. The use of the penis is for erection, coition, effusion of semen, and of urine.

Diseased appearances. Inflammation — ulceration, which, when caused by the venereal virus, is called a *chancre*—abscess — gangrene—phymosis—paraphymosis—elephantiasis—varix—anasarca—cancer—warts, or excrescences, from venereal or other causes—original mal-formation.

Urethra. Gonorrhœa — leucorrhœa — enlarged lacunæ — stricture, which is either a general contraction for a greater or less space; or a constriction, like as if a piece of packthread were tied round the urethra; or a fine pellicle, or a caruncle—an artificial urethra—fistula—no meatus urinarius—urethra converted into bone.

Operations. Amputation — circumcision — dividing the prepuce in phymosis and paraphymosis—opening concreted

lips of the meatus urinarius—passing a bougie—catheterism—application of caustic bougies—removing excrescences.

TESTES.

The testicles are two oval bodies, situated originally within the cavity of the abdomen, from which they descend before birth, or soon after, into a bag, called the scrotum, placed under the root of the penis.

SUBSTANCE. The adult testicle is composed of arteries, veins, and a peculiar set of vessels, which arise from the minute termination of the arteries. This peculiar set of vessels are—

1. The *vasa recta*, which are found in the substance of the testicle, arising from the minute ramifications of the spermatic arteries. At the top of the testicle, the straight vessels, which are the commencement of the excretory ducts, just as the biliary pores are of the ductus hepaticus, inosculate with one another, and form,

2. The *rete vasculosum testis*. This plexus of vessels sends off, at the superior part of the testicle,

3. The *vasa efferentia*; which are ten, or more, in number. They pass from the body of the testicle, form conical bundles, termed *coni vasculosi*; these soon uniting into one trunk, called *vas deferens*, form, by an immense number of convolutions, a somewhat hard substance, called the epididymis.

EPIDIDYMIS. This is somewhat pyramidal, having a thin convex head, and a flat, thin, extremity; it is formed merely of a convolution of the vas deferens, or excretory duct of the testicle.

VAS DEFERENS. This long, but small duct, is formed of a cartilaginous substance; its cavity is not sufficiently large

to admit a small pin. It passes upwards from the end of the epididymis, in a zig-zag manner, by the side of the pubes, where it is no longer convoluted, but proceeds straight into the cavity of the pelvis to the vesiculæ seminales.

COVERINGS. The testicle has a strong, white, dense tunic, intimately connected to it; this is called the *tunica albuginea testis*. It completely encompasses the body of the testicle, and is extended over the epididymis.

The next tunic of the testicle is called *tunica vaginalis*. Anatomists consider it as a production of the peritoneum; but this opinion does not appear to be well founded. It is a delicate membranous bag, connected externally, by cellular structure, to the dartos; and the testicle, with its tunica propria, or albuginea, adheres firmly to its outside, pushing itself, as it were, into it, in the same way as the heart into the pericardium, the lungs into the pleura, &c.; so that, when the tunica vaginalis is opened, the testicle is seen within it.

The *dartos* has already been described in *Myology*.

These coverings of the testicle are surrounded by a very elastic cellular membrane and common integuments, to which the name of *scrotum* is given.

ARTERIES. The spermatic arteries, formerly termed *vasa præparantia*, arise on each side from the aorta, near the emulgents, and sometimes from the emulgent, especially on the right side. The reason of the origin of these arteries being so remote from the testicles, will appear from considering the situation of those organs originally. When the spermatic artery reaches the abdominal ring, it is surrounded by the vas deferens, the spermatic veins, and a quantity of cellular membrane; all these together are called the *spermatic cord*, which passes through the ring.

VEINS. The blood of the spermatic arteries is returned by a number of small venal branches from the testicles, which enlarge as they pass up the cord. Having passed through the abdominal ring, they form a plexus around the spermatic artery, to which the term *corpus pampiniforme* is given.

ABSORBENTS. The lymphatics are distinguished into those of the integuments, those of the body of each testicle, those of the rete testis, and those of the epididymis; all of which proceed along the cord.

NERVES. The renal plexus of nerves sends off several branches to the testicles, as do also the mesenteric plexus, and the great intercostal, all of which accompany the spermatic artery. The scrotum is supplied by branches from the third and fourth lumbar nerves.

DESCENT OF THE TESTICLE. The testicles are always originally situated within the cavity of the abdomen. About the seventh month they generally leave that cavity, and pass through the abdominal ring into the scrotum. There is, however, great variety in the time of their descent, and cases are recorded, wherein they did not appear during the whole course of the person's life. When in the cavity of the abdomen, each testicle is connected to the scrotum by a ligamentous substance, and there is a small pyramidal body at its beginning, close to the testicle, which, from its appearing to direct the course of the testicle, is called *gubernaculum testis*.

DISEASED APPEARANCES. Inflammation, which is termed *orchitis*, or *hernia humoralis*—suppuration—gangrene—scirrhus—scrofulous enlargement—pulpy—cancer—converted into cartilage—ossified—small and wasted—*hydrocele*—*hæmatocele*—*pneumatocele*—cavity of the tunica vaginalis obliterated—filled with hydatids—the epididymis ending in a cu-

de sac—scrofulous thickening—scrofulous tumour—stricture—the spermatic veins varicose, called *varicocele*—the spermatic cord hardened—anasarcous—containing large cysts of water—cancer of the scrotum, peculiar to chimney-sweepers.

SECRETION AND EXCRETION OF THE SEMEN.

The semen is secreted by the minute branches of the spermatic arteries, that deposit it into corresponding seminal vessels, called *vasa recta*, which compose the greater part of the body of the testicle. The semen is the proper stimulus to these vessels, which are therefore stimulated to contract, and, by a very slow motion, convey it into the *vasa efferentia*, which terminate in the epididymis. The vas deferens carries it through the inguinal ring into the pelvis, to be deposited in the vesiculæ seminales, where it excites a desire to emit it.

The cells of the corpora cavernosa penis, the corpus spongiosum, and glans penis, are distended with blood by the venereal stimulus; hence the penis swells, and is inclined for coition; during which action, at the time of the *œstrum venereum*, the vesiculæ seminales contract, and the semen is thrown, with an immense force, through the ejaculatory ducts, opening into the urethra, where it is mixed with the secretion from the prostate gland, which is expelled at the same moment, and passes with it along the urethra, to be propelled by the contraction of the ejaculatory muscles into the cavity of the uterus.

VESICULÆ SEMINALES.

Two whitish membranous receptacles, situated on the back part of the bladder, close to its neck, which receive and contain the semen from the vasa deferentia.

SUBSTANCE. Membranous, and resembling in their structure an intestine variously contorted, and covered with a fibrous substance. Each vesicula seminalis sends forth a duct, which passes through the prostate gland, and are called the *ejaculatory ducts ;* they are some lines long, and enter the cavity of the urethra by a peculiar orifice at the top of the verumontanum.

VESSELS and NERVES. From the neighbouring parts.

ABSORBENT VESSELS. These arise from the vesiculæ seminales, and run to the lymphatic glands about the loins.

USE. To contain, retain, inspissate, and expel the semen into the urethra.

DISEASED APPEARANCES. Morbid adhesions to neighbouring parts---wholly converted into a scrofulous substance---ejaculatory ducts obliterated---one wanting---scirrhus---cancer---morbid enlargement of the cells---containing a diseased fluid.

THE ORGANS OF GENERATION IN WOMEN.

The parts which serve for generation in women are divided into external and internal.

The *external parts* are—

1. The MONS VENERIS. The prominent portion of integuments immediately over the ossa pubis. It is formed by a

quantity of fat under the skin; and, after pubity, is covered with a short hair.

2. The LABIA MAJORA. These are the two external lips, of a soft consistence, and formed of very vascular common integuments. They begin from the symphysis of the pubis, are covered externally with hair, but their internal surface is smooth, and lubricated with the smegma of the odoriferous glands. The opening between the labia is termed *fossa magna*, and at the inferior part, it is call *fossa navicularis*.

3. The CLITORIS. A small substance, placed just below the origin of, and within, the labia majora. It resembles a penis in miniature, and, like it, is formed of two spongy substances, which arise, by two crura, from the ascending ramus of the ischium. The clitoris is also, like the penis of man, covered with a foreskin. During coition, it is the principal seat of pleasure, and is distended and erected by the venereal stimulus.

4. The LABIA MINORA, OR NYMPHÆ. These are the two inner folds, placed at the commencement of the vagina; they begin from the foreskin of the clitoris, enlarging as they pass downwards, and terminate in the under part of the beginning of the vagina. Their structure is highly vascular and sensible, and they have a number of sebaceous glands to lubricate them. Their use appears to be, to assist in creating the venereal pleasure, and to direct the urine flowing against them out of the urethra, in such a manner as to prevent it wetting the thighs.

5. The MEATUS URINARIUS. Which is a small triangular opening, situated immediately under the clitoris, behind the nymphæ, and beset with mucous glands.

6. The HYMEN. This is seldom met with but in children, in whom it is mostly a semilunar membrane, situated at the

entrance of the vagina, behind the meatus urinarius. When once lacerated, it forms several fleshy excrescences, which are called *carunculæ myrtiformes.*

Diseased appearances. The *labia majora* are subject to inflammation — abscess—gangrene—adhesion with each other---warts---necrosis, or dry gangrene. The *clitoris*, to enlargement---and its prepuce to excrescences. The *nymphæ* are often found elongated---scirrhus---carcinomatous. The *meatus urinarius* is frequently found inflamed---fimbriated---ulcerated. The *hymen*, imperforate.

Operations. Separating the labia majora---extirpating the enlarged clitoris, or nymphæ---perforating the hymen---the mode of introducing the catheter.

The *internal parts* of generation are:—the vagina, uterus, Fallopian tubes, ovaria, broad and round ligaments of the uterus, and the urethra.

VAGINA.

An elastic membranous canal, leading from the nymphæ upwards, under the arch of the pubis, between the bladder and rectum, and terminating at the neck of the uterus, which it embraces.

Structure. It is composed of three membranes:

1. An epidermis, which enters from without.

2. A white, thick, elastic membrane, which, in the virgin vagina, forms an immense number of transverse rugæ, or folds.

3. A cellular coat, which is external, and connects it to neighbouring parts, and on which an immense number of arteries are distributed.

Besides these coats, the vagina has also, especially at its anterior part, a number of muscular fibres, which surround it

like a sphincter. In the vagina the following are to be noticed:

1. A number of *lacunæ*, which excrete the mucus of the vagina.

2. In virgins, the *hymen*, and, where this has been once ruptured, the *carunculæ myrtiformes*, or remains of the hymen.

3. The *meatus urinarius*, immediately under the symphysis pubis, behind the clitoris.

4. The vaginal portion of the uterus, or *os uteri*.

ARTERIES. The arteries of the vagina are very numerous; they arise from the pudical, forming a net-work around the vagina. The blood is returned into the hæmorrhoidal vein.

> When women *menstruate during pregnancy*, the catamenia are furnished by the vessels about the superior part of the vagina.

ABSORBENTS. The absorbents of the vagina are very numerous; they tend towards the iliac glands, into which they convey their contents.

USE. The vagina embraces the penis in coition, and, by its muscular fibres at its origin, and its elastic membranous substance, accommodates itself to the size of that organ. The catamenia pass from the uterus through the vagina; as does also the fœtus in labour.

DISEASED APPEARANCES. Inflammation, or *eleutritis*—abscess---gangrene---adhesions of its sides---common ulceration, scrofulous and cancerous---scirrhous tumours—morbid narrowness—very short—leucorrhœa—gonorrhœa—*elytrocele*—*prolapsus*—morbid widening from pessaries, polypus, &c.

OPERATIONS. Application of pessaries—puncturing the urinary bladder through the vagina—dividing morbid adhe-

tions —removing enlarged carunculæ myrtiformes—perforating the hymen—removal of polypi.

UTERUS.

The uterus, or womb, is a spongy hollow receptacle, somewhat like a flattened pear, situated in the pelvis, between the urinary bladder and the rectum.

Anatomists divide the uterus into the vaginal portion, the neck, the body, the fundus, and its appendages.

The *vaginal portion* is called the *os uteri*, and, from its resemblance to the mouth of a tench fish, *os tincæ*; midwives usually term it *os internum*, giving the name of *os externum* to the orifice of the vagina. In virgins it is much less than in those who have borne children; it consists of two labia, and an opening between, which leads to the cavity of the uterus. In the internal surface of the os uteri are situated a number of folds, and occasionally several small vesicles, and a quantity of transparent gelatinous mucus.

The *neck of the uterus* is also hollow, and contains several plicæ or folds. In some uteri it is longer than in others; its cavity leads to that of

The *body* of the uterus. Children and virgins have the uterus more flattened than others; it is somewhat of a triangular shape, having its appendages going from each superior angle, whilst the body gradually diminishes towards the os uteri. The cavity in the body of the uterus is also of a triangular shape: it commences at the os uteri, is nearly of the same diameter all along the neck of the uterus, and enlarges in the body. At each superior angle, the cavity of the uterus receives that of the Fallopian tube. The uterus is

lined by a smooth vascular membrane, whose vessels secrete the menstrual blood.

STRUCTURE. The portion of the uterus which hangs into the cavity of the pelvis, is covered by peritoneum, whilst the vaginal portion receives a tunic from the epidermis, continued from the vagina. The body of the uterus is composed of *peculiar* fibres, blood-vessels, absorbents, and nerves. These fibres do not appear, in an unimpregnated uterus, to be of the same nature as those of the impregnated uterus.

VESSELS. The *arteries* of the uterus are the spermatic and uterine, which are branches of the internal iliac. The *veins* accompanying the arteries, return the blood into the external hæmorrhoidal, internal iliac, and spermatic veins. The *nerves* of the uterus are branches of the sacral and great sciatic nerve; it also has branches from the mesocolic plexus. The *absorbents* are rarely seen; yet they are numerous, and proceed to the iliac glands.

APPENDAGES OF THE UTERUS. Under this term are comprehended the round and broad ligaments, the Fallopian tubes, and the ovaries.

1. *Round ligaments.* These are two vascular ligaments about the size of a goose-quill, which arise one from each side of the uterus, near its fundus, and somewhat on its anterior surface, and proceed obliquely outwards and downwards to the ring of the external oblique muscle, which they pass through, and are lost in the fat about the labia majora.

Relaxation of these ligaments allows the uterus to descend into the vagina; and, in many instances, this relaxation is so great as to suffer the uterus to be wholly without the os externum.

2. The *Fallopian tubes.* These are also termed uterine

tubes: they go one from each superior angle of the uterus directly across the pelvis, for the space of four inches, covered by the peritoneum, and terminate by a fringed body, the *fimbriæ*, which float in the cavity of the pelvis. The substance of the Fallopian tube is of a muscular nature, by which means it has a peristaltic motion. In the middle of the fimbriæ is the opening of the tube; so that if air were blown into the cavity of the vagina, it would pass into the cavity of the uterus, then along the Fallopian tubes into the cavity of the abdomen.

3. The *broad ligaments*, which consist of a duplicature of the peritoneum passing over the tubes and ovaria, and going in form of a broad expansion to the sides of the pelvis; so that the peritoneum of the upper and under surfaces of the uterus meeting at the sides, goes across the pelvis to its side, forming what is called the broad ligaments: in this passage it envelopes the tubes, ovaria, and blood-vessels.

4. The *ovaria*. Two oblong and rather flattened bodies, hanging in the duplicature of the peritoneum, at the sides of the uterus, about two inches from it, and behind the broad ligaments. Under the peritoneal coat of the ovarium is its proper substance, which is subcartilaginous. An adult virgin ovarium contains a number of highly vascular vesicles, filled with a transparent fluid; these are *ovula*, and were first accurately described by De Graaf. Besides these vesicles, there are occasionally two or more blackish spots; these are called *corpora lutea;* they were supposed to be a certain criterion of the woman's having borne a child; but this is erroneous, for corpora lutea exist in virgins.

Use. The uterus and its appendages are for the purposes of generation, and the perfection of the young.

Diseased appearances. *Uterus.* Inflammation, called *metritis* and *hysteritis* — scirrhus — cancer — gangrene—tubercles—morbidly distended, with coagulated lymph of a laminated structure; with a fluid, called *hydrops uteri*—polypus—inversion—retroversion—stricture of the cavity—converted into bony and earthy matter—a mass of bone in the cavity of the uterus—calculi of the uterus—ascarides in the uterus—hydatids—ruptures of the uterus—two uteri—no uterus.

Ovaria. Inflammation of the peritoneal coat, called *peritonitis ovarii;* of the substance of the ovarium; of its vesicles, or *ovula*—scirrhus—abscess—gangrene—the tunic of the vesicles converted into a black membrane—coagulated blood in the vesicles—an increase of fluid in the vesicles, called *hydrops ovarii*—the ovaria converted into a fatty substance, with hair and teeth—a fœtus in the ovarium—a morbid shrinking of the ovaria—an ovarium wanting—corpora lutea, which may be distinguished into the *true* and *spurious:* the former are yellow portions in the ovaria, harder than the surrounding parts, and which are formed by the collapsing of the cavity from which an impregnated ovum has escaped into the Fallopian tube. The *spurious corpora lutea* are very similar to the former, and are found in virgins, but never before the age of puberty; they arise either from a mature ovum having ruptured, which it is presumed now and then happens to lascivious women, or from some diseased action of the vessels of the ovum: these are frequently found in the ovaria of the women of the town.

Fallopian tubes. Inflammation of the tube and its fimbriæ—adhesions to neighbouring parts—hydatids adhering—dropsy—ending in a *cul de sac*, the fimbriæ being wanting—a fœtus in the Fallopian tube—scirrhous tumours growing to the tube—a tube wanting.

PHYSIOLOGY OF MENSTRUATION.

By a law of nature, women menstruate, in this climate, from about the age of fifteen to forty-five. Menstruation is the efflux of a sanguineous fluid from secreting vessels opening into the cavity of the uterus. During pregnancy, and suckling, the *catamenia*, or *menses*, for so the discharge is called, stop, except in some few instances, where it is supplied by the vessels of the vagina.

Menstrual blood, if women be healthy, differs from other blood in its not coagulating, which some have supposed may be caused by its slow exit, and its mixture with the secretions of the uterus and vagina. It differs, also, in quantity, the period of its first appearance, its duration, and the symptoms which precede and accompany it, according to the age, temperament, habit of body, climate, season of the year, mode of living, and other circumstances.

Women are said to be most susceptible of the action of the vivifying principle of the *semen virile* during the period of menstruation.

PHYSIOLOGY OF CONCEPTION.

The congress between man and woman is called coition.

During coition the nymphæ and clitoris are tumid with blood, and the fimbriæ of the Fallopian tubes, by a power inherent in them, are stretched out, and applied over the surface of an ovum in the ovarium.

The pleasure which women experience during coition is very great, and a quantity of mucus is suddenly emitted from the glands of the vagina, during the venereal orgasm,

which, in former times, was erroneously supposed to be the semen of the female; but now it is the opinion of physiologists that women have no semen, as anatomy cannot detect any organ destined to secrete it. During the venereal orgasm, the uterus is supposed to attract the semen by a sort of aspiration, and contract to retain it.

In order that a woman *may conceive*, it is requisite—

1. That she shall have *menstruated*.

2. That the ovum in the ovarium shall have arrived at a state of *maturity*.

3. That the fimbriæ of the Fallopian tube shall be *stretched over* the mature ovum, so as to let the cavity of the Fallopian tube come immediately over it.

Under these circumstances, if healthy male semen be emitted into the uterus, its vivifying part, which is extremely subtile, and called the *aura seminis*, flies through the cavity of the uterus along the Fallopian tube to the mature ovum, and imparts to it a principle by which it begins to circulate its fluids, and is animated. The ovum, thus vivified, enlarges and ruptures the slender peritoneal covering of the ovarium, in which it was enclosed. At the time of its rupturing, the fimbriæ of the Fallopian tube embrace it, and it is rolled, by the peristaltic motion of the latter, into the cavity of the uterus, there to be perfected, and at the expiration of nine months to be sent into the world, when it takes on new actions, which are continued independent of the mother.

GRAVID UTERUS.

After a woman has conceived, the *ovum* soon becomes covered with flocculent branches; it then increases in size, and sooner or later, the *flocculæ* attach themselves to a part of the uterus; forming the placenta. As the ovum increases in size, the uterus enlarges; but, for the first three months, it retains nearly its triangular form, and very little change takes place in the os tincæ. The uterus now, by gradations, becomes round as it increases, and, about the end of the fourth month, quickening takes place, when the uterus ascends through the pelvis, and may be felt above the pubes, extending nearly half way between the pubes and umbilicus; the neck of the uterus extends, the os tincæ expands, but is closed by a viscid gelatinous fluid; about the seventh month, the fundus uteri reaches the umbilicus; at the eighth, half way between it and the scrobiculus cordis; and at the ninth, to the scrobiculus cordis. At this period, the cervix uteri becomes distended, the os tincæ elongated: and the uterus itself assumes a pyriform shape, occupies all the umbilical and hypogastric regions, and contains the uterine placenta, the umbilical cord, the membranous ovum of the fœtus, the liquor amnii, and the fœtus.

UTERINE PLACENTA.

A spongy mass, like a cake, generally adhering to the fundus of the gravid uterus, composed of a net-work of very numerous vessels.

SUBSTANCE. Cellular, like a sponge, and filled with vessels.

ARTERIES. The arteries of the placenta are small, a branches of the two umbilical: they ramify over the placen and plunge into its substance, returning the blood from t foetus, to be taken up by the veins of the uterus.

VEINS. The umbilical vein ramifies very largely a beautifully over the placenta, and terminates in an imme number of smaller branches, which compose the greater of its substance: these small branches receive the blood fr the uterine arteries.

ABSORBENTS have been lately discovered.

USE. To receive and prepare the blood from the uterus f the foetus, and give off vessels to the umbilical cord.

FUNICULUS UMBILICALIS.

The umbilical cord is of an intestinal form, of the thicknes of one's finger, mostly about half a yard in length: it run from the navel of the foetus to the centre of the placenta.

STRUCTURE. It is composed of a cutaneous vagina, o sheath, a cellular substance, filled with a peculiar gelatinou fluid, one umbilical vein, and two umbilical arteries.

USE. The umbilical vein of the foetus conveys the blo from the placenta to the foetus, and the two umbilical ar ries return it from the foetus to the placenta.

MEMBRANOUS OVUM OF THE FŒTUS.

The foetus is enclosed in a membranous ovum, or ba within the cavity of the uterus.

The *ovum* consists of three membranes: an outer, or fila mentous, called *decidua*; a middle one, which in the embry

is shaggy, called the *chorion*; and an inner one, termed the *amnion*.

USE. To include the liquor amnii, to prevent its flowing into the uterus, and, at the commencement of parturition, to assist in dilating the os uteri.

LIQUOR AMNII.

The liquor of the amnion is a lymphatic liquid, inclosed in the cavity of the ovum surrounding the fœtus, secreted by the exhaling arteries of the membranes of the ovum.

QUANTITY. About the time of parturition, two or three pounds.

PROPERTY. Gelatinous, like turbid serum of milk.

USE. To defend the fœtus from the pressure of the uterus, to dilate the orifice of that organ in labour, to lubricate the vagina, and, some have supposed, to give nourishment to the fœtus.

FŒTUS.

During the first month of pregnancy, the ovum is about the size of a pigeon's egg; the fœtus swims in the middle of the liquor amnii, and represents a little cloud, which gradually enlarges, and its parts become more firm and perfect. The parts of the fœtus at birth differ from the adult, in having a *foramen ovale*, a *canalis arteriosus*, a *canalis venosus*, an *umbilical cord*, and the *thymus gland*. The lungs are black, collapsed, and sink in water. The liver is large. All the small glands are also proportionately large, and the large intestines are filled with meconium.

PECULIARITIES.—1. The FORAMEN OVALE. An opening between the auricles in the septum auricularum, by which

part of the blood in the right auricle passes into the left: it is of an oval form, and large enough to admit a goose-quill. After birth, when the lungs dilate, and the blood passes from the right ventricle through the pulmonary arteries, this foramen is mostly obliterated, but the situation of it can always be perceived.

2. The CANALIS ARTERIOSUS. This is an artery which passes from the pulmonary artery obliquely to the ascending aorta, to convey the blood into the aorta that is propelled by the right ventricle into the pulmonary artery, for it cannot all pass through the lungs.

3. The CANALIS VENOSUS. A vein about half an inch or more in length, passing from the sinus of the vena portæ into the vena cava inferior.

4. An UMBILICAL VEIN, which goes to the liver.

5. Two UMBILICAL ARTERIES, which arise from the internal iliac, and run up the sides of the urinary bladder.

After birth, these vessels gradually become impervious, and at length are removed by the absorbents.

6. The THYMUS GLAND, situated in the anterior space of the mediastinum.

There exists, before the ninth month, a delicate membrane, which arises from the edge of the iris, and completely fills up the pupil: this is called MEMBRANA PUPILLARIS.

Another membrane is situated at the bottom of the meatus auditorius externus, and covers the external surface of the membrana tympani: this is termed MEMBRANA MUCOSA.

CIRCULATION OF THE BLOOD IN THE FŒTUS.

The fœtus receives its blood from the mother through the umbilical vein of the funis, which transmits it along the duc-

tus venosus into the vena cava, to be carried to the right auricle of the heart. From the right auricle it passes partly through the foramen ovale into the left auricle, and partly into the right ventricle. From the right ventricle it is propelled into the pulmonary artery, which sends a very small proportion through the lungs, and the remainder through the canalis arteriosus into the aorta. In other respects, the circulation of the fœtus is similar to that of the adult. The blood is returned from the fœtus by the two umbilical arteries, along the cord, to the mother.

HYGROLOGY;

OR,

DOCTRINE OF THE FLUIDS.

The fluids of the body are divided into *crude*, as the chyle; *sanguineous*, as the blood,; *lymphatic*, as the lymph of the lymphatic vessels; *secreted*, or those separated from the blood; and *excrementitious*, as the urine, fæces, &c.

The secreted fluids are subdivided into *lacteal*, as the juice of the prostate gland; *aqueous*, as the aqueous humour of the eye; *mucous*, as the mucus of the nostrils; *albuminous*, as the serum of the blood; *oleous*, as the oil of the adipose membrane; and *bilious*, as the bile.

The fluids of the body are also divided, from their motion, into *circulatory*, which continually circulate in the vessels; *commorant*, which circulate with a slow motion, as the semen, and oil of the adipose membrane; *stagnant*, which remain for a certain time in any receptacle, as cystic bile, &c.

FLUIDS COMMON TO THE WHOLE BODY.

BLOOD.

A red fluid, which circulates in the cavities of the heart, arteries, and veins.

Colour. In the arteries, of a *florid* hue; in the veins, *darker*, except in the pulmonary veins.

Composition. Blood exposed to the atmosphere spontaneously *separates* by degrees into two parts; viz. the *serum*, a yellow and somewhat greenish fluid; and a *cake*, called also the *cruor*, or *crassamentum*, which is a red mass, swimming like an island in the serum.

Use. To stimulate the cavities of the heart and vessels to contraction; to generate the heat of the body, and propagate it to every part; to nourish every part; and to supply all the secretions, they being all separated from the blood.

Diseased appearances. The blood *post mortem* does not always exhibit the same appearance. It is mostly found in the venal system, and distending the right auricle. Blood in the dead body is chiefly, therefore, of a dark, venal colour, and of the consistence of jelly, the serous part not having separated from the cruor. In this state, although it distends some of the larger vessels, as the vena cava, the vena portæ, &c. and assumes the form of those vessels, yet when taken out, it breaks with the slightest force, so that its form cannot be preserved. This may be considered as the healthy state of blood; and all deviations from it as disease. The following have occurred:

1. *The blood in a state of fluidity.* This happens when the body is deprived of life by lightning, drowning, and by certain poisons.

2. *The coagulating lymph separated from the other parts of the blood.* This occurs when the person is some time *in articulo mortis.* By this separation, the coagulating lymph accumulates in the auricles and ventricles of the heart, and also sometimes in the pulmonary artery and aorta: these concretions are improperly termed *polypi*; they are often found assuming the complete form of the pulmonary artery, which is beautifully ramified. Of the same nature is the coagulum found in aneurismal sacs, though it is more completely laminated.

3. *Air in the veins.* This, which now and then is observed soon after death, when there was no emphysema, when no putrefaction had commenced in the body, and is most probably owing to a diseased state of the blood.

4. *Calcareous matter in the blood-vessels.* This has occurred to the author in one instance only, and that in varicose veins about the ovarium; there were three portions, each about the size of a pepper-corn, covered with a layer of coagulated lymph, like a pea in its pellicle. Each portion was in a separate vessel, surrounded by blood, and in no way connected with the sides of the vessel.

5. *Bile in the blood.* This occurs very frequently: there is always an obstruction of the common choledic duct; the gall-bladder and hepatic ducts are distended with bile, and the person has died jaundiced. If a small quantity of this blood be put into a basin of clear water, the water is seen first tinctured yellow, and then red.

These are the principal diseased appearances of the blood detected after death. That an excess or deficiency of serous particles of lymph, of the fibrous part of the cruor, of the red globules, &c. do occasionally exist, there can be no doubt; such undue proportions, however, the author has only

ascertained during life. A chemical analysis of the blood, both after death and before, is likely to throw great light on the nature of some diseases, and is a department of the science hitherto neglected.

LYMPH OF THE LYMPHATIC VESSELS.

A tasteless crystalline liquid, contained in the lymphatic vessels.

It is ABSORBED from the surface of the body, tela cellulosa, viscera, and cavities of the viscera of the whole body; and CONVEYED into the thoracic duct.

USE. To return the superfluous nutritious fluid, the vapours of cavities, and substances applied to the skin, to the thoracic duct.

This fluid is frequently contaminated with acrimonious, poisonous, and other substances, it being the vehicle for the poison of lues venerea, hydrophobia, and every thing that is taken up by the absorbents.

VAPOUR OF THE SHEATHS OF THE NERVES.

The aqueous humour contained in the vagina, and between the fibrils of the nerves.

It is secreted by the arteries of the sheath of the nerves.

USE. To moisten the nervous fibrils.

FLUIDS PROPER TO EACH PART.

FLUIDS IN THE CAVITY OF THE CRANIUM.

1. A *vapour*, between the membranes of the brain, which prevents morbid adhesions.

An increase of this fluid constitutes the *hydrops membranarum*, or *hydrocephalus externus*.

The collected fluid, it is asserted, is sometimes found between the dura mater and cranium, but this the author has never witnessed. It collects between the dura mater and tunica arachnoidea in considerable quantity; but even this is uncommon. Water between the arachnoid membrane and pia mater, especially in the intergyral spaces of the pia mater, is met with very frequently.

2. The *vapour in the ventricles of the brain*. A thin vapour contained in the cavity of the ventricles of the brain, and *secreted* by the exhaling arteries of their internal membrane, and of the choroid plexus.—Its *use* is to prevent the concretion of the ventricles.

An accumulation of this fluid forms the *hydrocephalus internus*.

In hydrocephalus internus, when the quantity of fluid is not considerable, it generally occupies the lateral ventricles and the third ventricle only, and then the foramen of Monro is very much dilated. The fluid sometimes, though rarely, distends the fourth ventricle. In almost every instance, the fluid wholly evaporates when exposed to the boiling heat, and very little coagulum is separated by an admixture of the mineral acids.

FLUID IN THE CAVITY OF THE NOSTRILS.

The *mucus of the nostrils*. The mucus *secreted* by the muciparous glands of the pituitary membrane, lining the septum and conchæ of the nostrils.—Its *use* is to preserve the nervous papillæ of the olfactory nerves moist, and to moderate excessive sensibility.

In common catarrh the mucus of the nostrils is so altered as to become highly acrimonious, irritating the parts it passes over. Towards the decline of the disease pure pus is separated for several days.

IN THE CAVITY OF THE MOUTH.

The SALIVA. A fluid secreted by the salivary glands into the mouth.—The *secretory organ* is composed of the parotid, sub-maxillary, and sublingual glands.—Its *use* is to augment the taste of the food ; to mix with, dissolve, and resolve the food into its principles ; and to moderate thirst.

FLUID IN THE CAVITY OF THE FAUCES.

The *mucus of the fauces*. A mucus secreted by the muciparous glands of the tonsils, pharynx, &c.—Its *use* is to lubricate the fauces.

FLUIDS IN THE EYES.

1. The *aqueous humour of the eye*. A very limpid water, which fills the anterior and posterior chambers of the eye.—It is *secreted* by the floating vessels of the corpus ciliare, and exhaling vessels of the iris.—Its *use* is to distend the cornea, retain the crystalline lens and vitreous humour in their places, and to transmit the focus of the rays of light to the crystalline lens.

When the secretory organ, from inflammation, separates pus, or when pus becomes mixed, by the rupture of a small abscess, with the aqueous humour ; it falls to the bottom of the chamber, and constitutes the disease called *hypopium*.

It sometimes happens that a white milky fluid is separated by the secretory organ instead of a limpid water : this disease is termed *hypogala*.

2. The *crystalline lens*. A lentiform, pellucid, cellular body, distended by a very limpid aqueous fluid, inclosed in a membranous capsule, and situated in a depression in the

anterior surface of the vitreous humour.—Its *use* is to transmit and refract the focus of the rays of light to the vitreous humour.

When the secreting organ separates a turbid fluid into the cells of this lens, it forms the disease termed *cataract*, of which there are many species, mostly distinguished by the colour or nature of the opacity.

3. The *vitreous humour*. A pellucid vitriform or glass-like body, which fills the whole bulb of the eye behind the crystalline lens.—It is *composed* of small cells, distended with a limpid water.—Its *use* is to expand the bulb, and transmit and moderately augment the focus of the rays of light from the crystalline lens to the retina.

This vitriform substance occasionally becomes turbid, and causes a dimness of sight: this is termed *glaucoma*.

4. The *water in the capsule of the crystalline lens*. It is *secreted* by the pellucid branches of the artery of the crystalline lens.—Its *use* is to prevent the concretion of the crystalline lens with its capsule.

5. The *pigment of the iris*. The coloured mucus, which covers the anterior and posterior surface of the iris.—Its *use* is to reflect the rays of light.

6. The *pigment of the choroid membrane*. The black or brownish mucus, which covers the anterior surface of the choroid membrane, and the interior of the corpus ciliare.

7. The *tears*. A limpid fluid secreted by the lachrymal gland, and flowing on the surface of the eye.—Its *use* is to moisten the surface of the eye and eyelids.

8. The *juice of Meibomius's glands*. An unctuous humour secreted by the sebaceous glands of Meibomius, and lubricating the tarsi of the eyelids.—Its *use* is to lubricate the

tarsi of the eyelids, and involve the saline acridity of the tears.

FLUIDS IN THE CAVITY OF THE EARS.

1. The *cerumen*, or *wax of the ears*. A bitter ceraceous fluid, secreted by the ceruminous glands of the meatus auditorius externus.—Its *use* is to lubricate the sensible membrane of that canal, and to prevent insects from entering.

2. The *water of the labyrinth*. An insipid water contained in the cavity of the membranous semicircular canals and cochlea.—Its *use* is to preserve the nervous fibrils of the auditory nerve soft and moist, and to moderate the tremors of sounds.

A small white substance has occasionally been noticed, by the author, floating in the fluid, distending the membranaceous semicircular canals and alveus communis: its nature has not been investigated, nor does he know whether it occasioned any alteration in the function of that organ.

FLUIDS IN THE NECK.

1. The *juice of the thyroid gland*. It is of a yellowish white colour, especially in infants, and its *use* is not known.

2. The *mucus of the œsophagus:* which is secreted by the muciparous glands, situated in the cellular membrane.—Its *use* is to lubricate the cavity of the œsophagus, and prevent the concretion of its sides.

In some animals, as serpents, the inferior part of the œsophagus has a power of secreting a fluid capable of digesting substances: thus, if a fish, or frog, too large to be contained in the stomach of the serpent, be swallowed, and the animal killed some hours after, that part which is in the œsophagus will be seen equally digested with the portion in the stomach.

FLUIDS IN THE CAVITY OF THE THORAX.

1. The *mucus of the trachea, bronchiæ, and vesiculæ pulmonales.* This fluid is secreted by the muciparous glands situated under the internal membrane of those parts.—Its *use* is to prevent the surface of the trachea, bronchiæ, and vesiculæ pulmonales, from becoming dry by the continual passing of the air.

This fluid is frequently altered from its healthy appearance, and varies considerably in its quantity. In common colds, inflammation of the membrane lining the air-passages, asthma, anasarca of the lungs, phthisis, and other diseases, it assumes particular appearances, whose distinguishing characters have not yet been pointed out. Such an investigation may lead to pathognomonic criteria of asthma spontaneum, phthisis senilis, phthisis mucosa, and phthisis purulenta, in such cases as cannot well be distinguished by the ordinary consideration of the symptoms.

2. The *vapour in the cavity of the thorax:* which exhales from the exhaling vessels of the pleura of the lungs and ribs, into the cavity of the thorax.—It preserves the pleura soft, moist, and flexile, and defends and prevents it from the friction of, and concretion with, the lungs.

Hydrothorax is an accumulation of this fluid, or of a diseased secretion.

3. The *vapor* or *liquor pericardii.* Secreted by the arterious exhaling vessels, which open upon the external surface of the heart, and internal of the pericardium.—Its *use* is to prevent the concretion of the heart with the pericardium, to diminish the friction, and preserve the parts soft.

When this fluid, or a diseased one, accumulates in the pericardium, it forms the *hydro-cordis,* or *hydrops pericardii.*

4. The *juice of the thymus gland.* A milky juice secreted by the arteries of this gland: its *use* is not known.

FLUID IN THE BREASTS.

The *milk of the breasts.* A white, sweetish fluid, secreted by the glandular fabric of the breasts of women.—Its *use* is to be an aliment to new-born children.

Nurses' milk is often unhealthy, and produces many of the diseases of infants, which are only effectually relieved by putting the nurse on a different diet, or by changing the nurse.

FLUIDS IN THE ABDOMEN.

1. The *gastric juice.* A limpid colourless fluid, secreted by the exhaling vessels of the very numerous arteries which bedew every part of the stomach.—Its *use* is to digest the food.

2. The *pancreatic juice:* which is limpid, and secreted by the pancreas, and conveyed through its excretory duct, into the duodenum.—Its *use* is to assist in the formation of chyle.

3. *Bile.* A yellowish, green, bitter juice, secreted by the glandular substance of the liver, and conveyed by the biliary ducts, in part, into the duodenum, and in part into the gall-bladder: hence cystic and hepatic bile.—Its *use* is to extricate the chyle from the digested mass of food, to stimulate the intestines, and to prevent the abundance of mucus and acidity in the primæ viæ.

4. *Chyle.* A white fluid, separated from the food in the primæ viæ, and observed some hours after eating, in the lacteal vessels of the mesentery, and in the thoracic duct.—Its *use* is to form the blood.

5. The *enteric juice.* A limpid liquor, secreted by the exhaling arteries in the whole course of the small and large intestines.—Its *use* is to assist digestion, and to cleanse and moisten the intestines.

6. The *mucus of the primæ viæ.* This is secreted by the muciparous glands situated under the villous coat of the primæ viæ.—Its *use* is to lubricate the stomach and intestinal canal.

7. The *vapour of the cavity of the abdomen.* An aqueous vapour, secerned by the exhaling arteries of the peritoneum, which preserves moist, and prevents the concretion of, the abdominal viscera.

A collection of this fluid constitutes the *ascites abdominalis*, or dropsy of the belly.

8. *Urine.* A saline liquid, of a citrine colour, secreted in the kidneys, and dropping down from them *guttatim* through the ureters into the cavity of the urinary bladder.—Its *use* is to liberate the body from the superfluous water, &c.

9. The *mucus of the bladder.* Secreted by the muciparous glands situated under the innermost membrane.—Its *use* is to lubricate and defend the internal and very sensible surface of the urinary bladder.

FLUIDS IN THE PARTS OF GENERATION IN MEN.

1. The *mucus of the urethra.* Secreted by the muciparous glands situated under the internal membrane.—Its *use* is to lubricate and defend the very sensible surface of the urethra against the acridity of the urine.

In *gonorrhœa* the mucus of the urethra becomes increased in quantity, and altered in quality, from the specific action induced in the secretory organ by the venereal virus.

In *leucorrhœa*, or gleet, the mucus of the urethra is of a yellow colour and ropy consistence, and very different from the healthy mucus of that passage.

2. The *smegma of the glans penis*. An unctuous humour, secreted by the sebaceous follicles on the surface of the glans and prepuce.—Its *use* is to lubricate the sensible surface of the glans, and prevent its concretion with the prepuce.

These sebaceous follicles are often irritated to take on diseased action. When this arises from venereal virus, the *gonorrhœa glandis* takes place; but when from other acrimonies, as that of the smegma itself, or fluor albus of women, &c. there is a thin acrimonious discharge from the follicles, which smells intolerably.

3. The *vapour of the tunica vaginalis testis:* which exhales from the arteries into the cavity of the tunica vaginalis testis.—Its *use* is to prevent the concretion of the testes with the tunica vaginalis, and preserve them moist.

Hydrocele is an accumulation of this fluid.

4. The *liquor of the prostate gland*. A milky juice, separated by the arteries of the prostate gland, and sent through its ducts, *sub coitu*, into the urethra with the semen.—Its *use* is to serve as a vehicle to the semen.

5. The *semen*. A prolific liquor secreted in the testes, and carried through the epididymis and vas deferens into the vesiculæ seminales.—Its *use* is to be emitted, *sub coitu*, into the female vagina, and there, by its aura, to penetrate to, and impregnate the ovulum in the female ovarium.

FLUIDS IN THE PARTS OF GENERATION IN WOMEN.

1. The *smegma of the labia and vulva*. An unctuous juice, secreted by the sebaceous glands, and covering the internal

surface of the labia and nymphæ.—Its *use* is to lubricate their sensible surface, and prevent any irritation *post mictum*.

2. The *mucus of the vagina:* which is secreted by the muciparous glands under the internal membrane.—Its *use* is to lubricate the vagina, lest it be irritated by friction, *sub coitu*, and to prevent the concretion of its sides.

> *Leucorrhœa*, or *fluor albus*, is an altered state of these fluids, owing to a diseased action of the secretory organ; and in many cases there is reason to believe that the internal surface of the uterus supplies the discharge.

3. The *liquor of the cavity of the uterus.* Secreted into it by the exhaling arterious vessels. In the virgin uterus, it is serous and turbid; in the gravid, milky.—Its *use* is to moisten the cavity, and prevent its concretion.

FLUIDS IN THE ARTICULATIONS.

1. The *synovia.* An unctuous fluid, secreted by the internal membrane of the capsular ligaments surrounding the articulations of the bones.—Its *use* is to lubricate the cartilaginous surfaces of the articulatory bones, and facilitate their motions.

2. The *juice of the bursæ mucosæ.* An unctuous and somewhat mucilaginous juice, secreted by the vessels of the internal membrane of the bursæ mucosæ.—Its *use* is to lubricate the tendons for motion.

FLUID IN THE BONES.

The *marrow of bones.* An oily substance secreted by the arteries of a very vascular membrane lining the interstices of the bony *lamellæ*, and the cavities of bones. In the fœtus, the marrow is not oil, but a soft florid mucous fluid.

Inflammation of the membrane which secretes the marrow is sometimes the cause of *spina ventosa*.

FLUIDS OF THE COMMON INTEGUMENTS.

1. *Rete mucosum.* The mucus situated between the epidermis and cutis of the whole body, and secreted by the arterious vessels of the skin.—Its *use* is to conglutinate the epidermis to the cutis, to moderate the sense of touch, to moisten the nervous cutaneous papillæ, and give the external colour to the body; hence it is *white* in Europeans, *black* in Æthiopians, &c.

2. The *oil of the adipose membrane.* Secreted by the arteries of the cellular membrane.—Its *use* is to facilitate muscular motion.

The secretory organ of the adeps occasionally takes on a diseased action in some part, by which the quantity is augmented, and its nature somewhat altered. This gives rise to that species of wen or tumour called *lypoma.*

3. *Sweat.* The aqueous perspirable matter excreted through the exhaling arteries of the skin.—Its *use* is to keep the skin moist.

A morbid increase of perspiration is termed *ephidrosis,* or *sudor Anglicanus.*

THE ART OF MAKING

ANATOMICAL PREPARATIONS,

To exhibit the Structure and diseased Appearances

OF THE

HUMAN BODY.

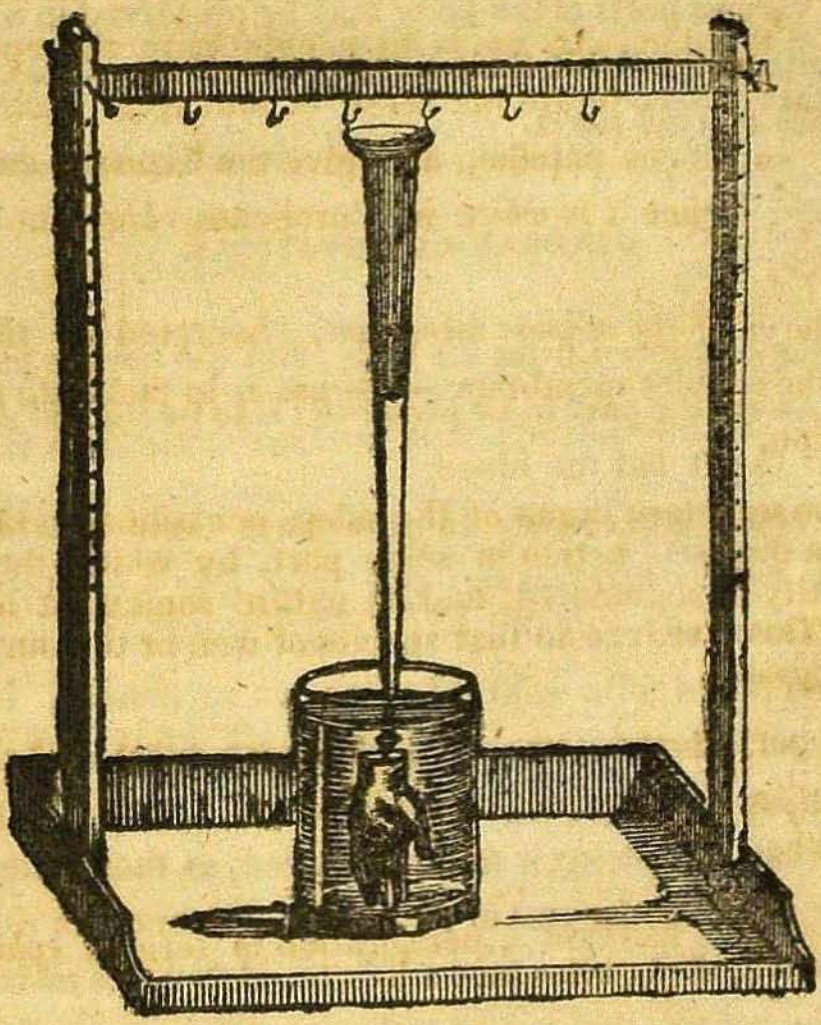

The Quicksilver Tray, and its Appendages.

The tray is to be made of mahogany, of a convenient size, and to have a small hole in one corner, with an ivory plug, to let out the mercury when necessary. The two uprights are moveable, and cut so as to permit the cross bar to be fixed at any distance from the tray. The uprights and cross bar are only to be affixed occasionally, as when a hand or testis is to be filled with mercury.

PREPARATIONS OF THE VISCERA IN A HEALTHY STATE.

THE various parts of the body may be preserved in a healthy state, either to exhibit their form or structure, or to compare them with morbid parts.

GENERAL OBSERVATIONS.

1. When removed from the body, and the useless parts dissected away, the part to be preserved is to be soaked in water, in order to get out the blood.

2. When it is necessary to give parts their *natural form*, which is lost by macerating; put them into a saturated solution of alum, or rectified spirit, retaining them by any means in the required form until they become hardened. If it be a hollow part, as the stomach, bladder, &c. fill it with, and immerse it in, the solution, or spirit.

3. When an *opening* is to be exhibited, as that of the ureter, the bile-duct, the lacunæ of the urethra, Stenonian duct, Fallopian tube, &c.; introduce a bristle. After this manner preserve the uterus, and its appendages, cutting open the vagina and cavity of the uterus, the bladder, intestine, stomach, heart in the pericardium, liver, spleen, kidney, &c. &c.

4. All preparations of the *brain* are best hardened in a saturated solution of corrosive sublimate.

5. The parts are to be suspended in proof spirit by raw silk, in a tie over bottle, and covered with putrid bladder, taking care to exclude all air. When dry, varnish the bladder with

ucilage of gum-arabic several times; then put a sheet of hin lead over, and varnish its edges with mucilage; and, lastly, e another bladder over, and give it a coat of common spirit rnish, in which lamp-black, or other colouring matter, is ixed, or with Brunswick varnish.

PREPARATIONS OF MORBID PARTS.

All morbid parts should, immediately after their removal om the body, be put into rectified spirit of wine for a day two, and then preserved in proof spirit. These preparations ul a great quantity of spirit, and should therefore be kept in opper-glasses, from which the spirit can easily be removed, nd fresh put in, until the preparation ceases to foul the spirit, hen it may be put into a tie-over bottle.

PREPARATIONS MADE BY MACERATING.

Preparations obtained by this process are very various.

GENERAL OBSERVATIONS.

1. Let the water be frequently *changed*, until it is no longer coloured with blood, but never after the blood is steeped away.

2. Let the macerating pan be placed in a *warm* place, to facilitate putrefaction; for if it be put in a cold place, the sper-

macceti-like conversion of the soft parts will be formed, and the part spoiled.

3. The soft parts surrounding bones are a long time before they detach themselves from the bones.

4. Bones, when macerated, should be exposed to the sun's rays, and frequently wetted with clean water, or they may be bleached with the diluted oxygenated muriatic acid.

BONES.

Bones are macerated, to be preserved whole; or they are sawed, to expose their internal structure.

Bones of the head. Put the whole head, without disturbing the flesh or brains, into the pan. When sufficiently macerated, all the soft parts will come away with the periosteum; then detach the vertebræ, and wash out the brain. Bones are separated from each other by filling the cranium with peas, and putting it into water. The same method is to be adopted with other bones.

Bones in general, for structure. Divide the femur into two halves: the os innominatum, the petrous portion of the temporal bone, the parietal bones, &c.: these, when macerated, will exhibit the compact, the spongy, laminated, and reticular substance of bones.

FŒTUS.

Cut carefully away the fatty substance enveloping a fœtus, but do not cut any of the cartilages. Steep out its blood, and macerate. It should be frequently looked at, and taken out when the flesh is all destroyed, before the cartilages are separated. The following preparations are obtained in this way:

1. The superior extremity, to shew its bones, the progress of ossification, and the cartilage to be formed into bone.

2. The lower extremity, to expose the same circumstance.

3. The spine, which forms a beautiful preparation.

4. The pelvis, not less elegant.

Preservation. In proof spirit.

CUTICLE.

The cuticle of the hand and foot may be separated by maceration: the former is called *chirotheca*, the latter *podatheca*. The arm and foot of a large fœtus are to be preferred; they are first to be well washed with a soft sponge in soap and water.

Preservation. Suspend them in proof spirit: first tie the part by which they are to be suspended, then put them into the bottle with the spirit, and gently pour some spirit into the cuticle, to distend it like a glove or stocking.

INJECTING INSTRUMENTS.

The celebrated Dutch anatomist, *Ruysch*, first invented the art of injecting animal bodies: hence it is termed the *Ruyschian* art.

There are three kinds of apparatus used in making injected preparations. The one for the coarse and fine injections, and the minute injection; the other for injecting with quicksilver; and the third, called the oyster syringe, for injecting minute preparations with the minute injection only.

The first consists of a *brass syringe* made for the purpose, of

various sizes, from one carrying six ounces to one sufficient large to hold two pounds. The point of these syringes adapted to the *pipes* into which it is to be affixed. To this ringe belong a stop-cock, and a great variety of pipes.

The instrument for injecting quicksilver consists of a lo *glass tube*, at whose end is fixed, by screwing in, a *steel pi* the extremity of which is extremely fine.

The *oyster syringe* is similar to the large syringe, excepti size. It is so small, that when the syringe is in the hand, a full, its piston may be commanded by the thumb of that han to throw its contents into any preparation in the other han The pipe affixed by being screwed to the end of this syring nearly as small as that belonging to the quicksilver tube.

These instruments are always to be had at the surgical-in strument-makers.

INJECTIONS.

The injections employed for anatomical purposes are four different kinds: coarse, fine, minute, and mercurial.

COARSE INJECTIONS.

Red. Yellow bees' wax, sixteen ounces—the palest resi eight ounces—turpentine varnish, six ounces, by measure— finely levigated vermilion, three ounces.

Yellow. Yellow bees' wax, sixteen ounces—pale resin, eight ounces—turpentine varnish, six ounces—king's yellow, two ounces and a half.

White. Fine virgin wax, sixteen ounces—pale resin, eight

ounces—turpentine varnish, six ounces—best flake white, five ounces and a half.

Pale blue. Fine virgin wax, sixteen ounces—pale resin, eight ounces—turpentine varnish, six ounces—best flake white, three ounces and a half—fine blue smalt, three ounces and a half.

Dark blue. Fine virgin wax, sixteen ounces—pale resin, eight ounces—turpentine varnish, six ounces—blue verditer, ten ounces and a half.

Black. Yellow bees' wax, sixteen ounces—pale resin, eight ounces—turpentine varnish, six ounces— pure lamp-black, one ounce.

Green. Yellow bees' wax, sixteen ounces—pale resin, eight ounces—turpentine varnish, six ounces—levigated crystallized verdigrise, four ounces and a half—best flake white, one ounce—levigated gamboge, one ounce.

Liquefy the wax, resin, and turpentine varnish over a slow fire, in an earthen pipkin; then add the colouring matter, having previously mixed it in another pipkin, with a very small quantity of the melted composition. Stir the whole well together with a wooden pestle, so that the colouring ingredients may be intimately and smoothly blended; place the whole again over the fire, and, when they have acquired their due heat, the injection will be fit for use.

FINE INJECTIONS.

Brown spirit varnish, white spirit varnish, of each four ounces—turpentine varnish, one ounce.

These are to be put together in an earthen pipkin, over a slow fire, until they have acquired the necessary degree of heat. To make it of a red colour, put one ounce of finely le-

vigated vermilion into another pipkin, and gradually add the heated materials, stirring the whole with a wooden pestle, that the colour may be equally diffused.

One ounce and a quarter of king's yellow—two ounces of best flake white—one ounce and a half of fine blue smalt, with one ounce and a quarter of best flake white—four ounces of blue verditer—half an ounce of pure lamp-black—are the proportions for the various colours to the quantity of ingredients ordered above.

MINUTE INJECTIONS.

The size, which forms the vehicle to the colouring matter in these injections, is made in the following manner:

Take, of the finest and most transparent glue, one pound; break it into small pieces, put it into an earthen pot, and pour on it three pints of cold water; let it stand twenty-four hours, stirring it now and then with a stick; then set it over a slow fire for half an hour, or until all the pieces are perfectly dissolved; skim off the froth from the surface, and strain it through a flannel for use.

Isinglass and the cuttings of parchment make an elegant size for very particular injections; and those who are not very nice, may use the best double size of the shops.

Red. Size, one pint—Chinese vermilion, two ounces.

Yellow. Size, one pint—king's yellow, two ounces and a half.

White. Size, one pint—best flake white, three ounces and a half.

Blue. Size, one pint—fine blue smalt, six ounces.

Green. Size, one pint—levigated crystallized verdigrise,

two ounces—best flake white, levigated gamboge, of each eight scruples.

Black. Size, one pint—lamp-black, one ounce.

GENERAL OBSERVATIONS.

1. All injections are to be heated to such a degree as not to destroy the texture of the vessels they are intended to fill: the best criterion of this degree of heat is dipping the finger into the injection. If the finger can bear the heat, the texture of the vessels will not be hurt.

2. All the coloured materials should be as finely legivated as possible, before they are mixed with the injection.

3. Great care should be taken lest the oily ones boil over, or bubble; and that the heat be gentle, otherwise the colour will be altered.

4. They should be constantly stirred, lest the colouring material, which is much heavier than the vehicle, fall to the bottom.

5. The instrument to stir them with should be a wooden pestle, and there should be one for each colour.

6. A large tin pan to contain water, with two or three lesser ones fixed in it for the injections, will be found very useful, and prevent all accidents, and the colour from spoiling when on the fire.

PREPARATIONS MADE WITH COARSE INJECTION.

The blood-vessels are mostly filled with coarse injection, and the parts dissected, to shew their course; and when the

anatomist wishes to exhibit the minuter branches, the fine injection is to be thrown in first, and followed by the coarse.

GENERAL OBSERVATIONS.

There are several circumstances to be observed in injecting with the fine and coarse injections, which are applicable to every part into which they are thrown; these are—

1. The part to be injected should be freed from its blood as much as possible, by steeping it for several hours in warm water, and repeatedly changing it.

2. Having emptied the part of its blood, the pipes are to be fixed in their proper vessels, and all other vessels to be tied with a ligature.

3. The heat of the water is then to be gradually increased to the same temperature with the injection to be thrown in.

4. The injecting syringe should be steeped in the water with the part to be injected until wanted.

5. The injection being finished, and the subject or part become cold, remove the pipes, and tie up the parts they were in. Whenever a blood-vessel is open, by accident or otherwise, be sure to secure it by a ligature, or cover it with a piece of thin and moist bladder, or the injection will always be oozing out.

6. The parts dissected and dried are to be varnished twice with copal or hard varnish, first washing them free from grease with some soap-lees, and well drying them again.

BLOOD-VESSEL SUBJECT.

Select an emaciated subject, between the age of two and fourteen years.

Preparation. Make an incision through the integuments the whole length of the sternum: then with a saw, divide the sternum longitudinally into two equal parts; introduce a dissecting knife under the divided bone on each side, separate it from the mediastinum, and lay open the thorax, by bending back the two portions of the sternum and the cartilages of the ribs; an incision is then to be made into the pericardium, and the left ventricle of the heart, and a large pipe introduced into the aorta, and secured by a ligature. The subject is next to be put into warm water, and gradually heated. The time generally required to heat the whole subject is four hours, in a large body of water.

If the veins are to be injected, three more pipes are required: one to be put into the angular vein, at the corner of the orbit; another into a vein as near the fingers as possible; and the third into a vein as near to the toes as possible.

Injection. The subject and injection being properly heated, throw the coarse red injection into the heart pipe, which will fill the arterial system; and then the coarse yellow injection into the head pipe first, and next into the pipes of the extremities. The subject, when injected, should be put into cold water, with its face downwards.

Dissection. Open the abdomen by an incision from the sternum to the umbilicus, and thence to each ilium. Cut away the abdominal viscera, the stomach, spleen, and intestines; leaving the mesenteric vessels as long as possible: dissect away the liver, leaving the vena portæ and hepatic artery as long as possible. This done, dissect away the fat and cellular membrane from the vessels; secure the mesenteric vessels in an arborescent form on a piece of pasteboard. The kidneys, urinary bladder, uterus, and its appendages, are to be preserved and dried in their situations. From the thorax are to be

removed the lungs and heart, or the latter may remain. The integuments being carefully dissected from the sternum, it is to be bent back, and kept in that situation, to expose the internal mammary arteries. The dissecting away the skin is next, in order to exhibit the muscles, and expose the arteries and veins. The skin should only be removed from time to time to carry on the dissection, and never more than that covering the part to be dissected; otherwise the parts from which the skin is removed will become dry, and the dissection be spoiled. In dissecting the arteries and veins, the dissector will find no difficulty, if he proceeds cautiously from the larger trunks towards their extremities. The brain is to be removed by sawing away a large portion of the bone on each side of the longitudinal sinus of the dura mater. The cheeks should be pushed out by introducing horse-hair into the mouth.

Drying. When dissected, or before, the subject should be hung up by the head in a frame: one arm is to be placed at a little distance from the side, and the other turned up over the head, with the palm of the hand in front; the legs at a little distance from each other, and kept in these postures by packthread. Should any muscles obstruct the sight of the arteries, they are to be separated to a proper distance by pieces of wood. This done, expose it to a current of air, in a place where it cannot get wet; and if the weather be moist, remove, from time to time, all moisture, by a soft sponge.

Preservation. Varnish it several times, and keep it in a dry place, and in a proper case, with a glass front and back.

A HEAD, FOR ARTERIES AND VEINS.

Choose an emaciated head of an adult, separated from the

body, by a transverse section, about the sixth or seventh vertebra.

Preparation. Put a pipe into each carotid, or, what is better, one bifurcated pipe: remove a portion of bone over the longitudinal sinus of the dura mater, about the middle of the parietal bones, and secure a pipe in the longitudinal sinus, pointed towards the occiput. Put the head into warm water, to soak, pressing the blood occasionally out of the external and internal jugulars. Then tie up the jugular veins and vertebral arteries, and all the small vessels.

Injection. Into the carotids throw the red injection, and the yellow, or dark blue, into the pipe in the sinus of the dura mater. The former will fill the arteries, the latter the veins.

Dissection. Follow the course of the larger trunks, dissect out the globes of the eyes, and remove, with a fine saw, the portion of the jaw-bone behind the last molaris, to shew the course of the internal carotids. To prepare the whole head, a portion of the cranium must be removed, by sawing on one side of the longitudinal sinus of the dura mater, from the frontal sinus to the horizontal spine of the occipital bone, and then sawing horizontally above the ear, from one extremity of the former incision to the other. The dura mater should be removed with a pair of scissars, the brain carefully washed out, and the tentorium and falx preserved. It is better to make a perpendicular section of the head, a little to one side of the sagittal suture, through the nose, foramen magnum, and vertebræ; and thus prepare each side. The course of the cervical artery is to be shewn by dissecting away the muscles, &c. from between the transverse processes.

Preservation. Varnish it several times, and keep it in a glass case, suspended; or fix it by the neck, and cover it with a glass bell.

AN ARM, FOR ARTERIES AND VEINS.

Remove the superior extremity from the trunk, by separating the clavicle from the sternum, raising it, and passing the knife under it to the articulation, including the greater part of the pectoral muscle. Then cut under the scapula, so as to remove with the arm the clavicle, scapula, and subscapularis muscle.

Preparation. After soaking it in warm water, force out the blood from the veins, by pressing the extremity from the fingers towards the shoulder. Fix a pipe in the axillary artery, and another in the largest vein on the back of the hand; some warm water may be injected into the vein, so as to wash out the blood; and, when pressed out, the axillary vein should be tied. Tie any muscular branches that may be gaping.

Injection. Red injection may be thrown into the artery, and yellow, or dark-blue, into the vein.

Dissection. This is very simple; it requires only the removal of all the cellular and fatty membrane, and exposing the course of the vessels. Tie up the limb by the clavicle.

Preservation. When varnished, keep it in a cool and dry place.

A LOWER EXTREMITY, FOR ARTERIES AND VEINS.

Having removed the contents of the abdomen, make a section through the symphysis of the pubis, and the ligaments connecting the ilium and sacrum, so as to remove one side of the pelvis.

Preparation. Fix a pipe in a vein as near the toes as possible, and another in the iliac artery. When the limb has been well soaked in warm water, press out the blood from the veins, or throw in some warm water, at the venal pipe; but carefully press it out again, and tie up the iliac vein. Secure all divided vessels.

Injection. Blue injection, or yellow, may be put into the vein, and red into the artery.

Dissection. Expose the course of the artery and veins, particularly the profunda of the thigh.

THE GRAVID UTERUS, FOR ARTERIES AND VEINS.

The gravid uterus, or the uterus soon after it has expelled the fœtus, may be injected, to shew its large and tortuous vessels. It may be injected, whilst in the body; but this is always attended with much difficulty, and never succeeds so well as when removed from the body. Therefore separate the spermatic and hypogastric vessels as far from the uterus as possible, and cut out the uterus with the bladder, vagina, and external parts of generation.

Preparation. Put a pipe in each spermatic artery, and each hypogastric, and also one into each spermatic and hypogastric vein; so that, at least, there will be required four pipes for arteries, and four for veins. Be very careful that all the divided vessels be secured by ligature, which only can ensure success.

Injection. Red and yellow are mostly preferred; the former for the arteries, the latter for the veins. Be careful that the red be thrown into all the arterial pipes, and the yellow into

the venal; and, to prevent mistakes, it will be better to have the pipes of the veins different from those of the arteries.

Dissection. Distend the vagina and uterus with horse-hair, either by introducing it through the vagina, or, if the fœtus be in it, by a perpendicular section through the anterior parietes, which is to be sewed up again. Then dissect away all loose cellular structure and fat, preserving the round and broad ligaments, and Fallopian tubes. Should the fœtus be in the uterus, an incision should be made, as above directed, except the placenta be adhering there, which is known by the great number of vessels, and then on the opposite side, and through the membranes, to remove the child; cut the umbilical cord close to the fœtus, and fix a pipe in one umbilical artery, and another in the umbilical vein; the latter carrying arterial blood, should be filled with red injection, and the artery with yellow: the cord is to be laid round the placenta.

Preservation. When well varnished, suspend it in a case, with a glass front and back.

A PLACENTA, FOR ARTERIES AND VEINS.

This is perhaps the easiest preparation to make with coarse injection; and should, therefore, be the first attempt of the student.

Preparation. Fix a large pipe in the vein, and a small one in one of the arteries. The difficulty usually attendant on getting the pipe into the artery is obviated in a great measure by introducing the point of the scissars into these vessels, and slitting them down for about half an inch, then spreading the artery open upon the fore-finger, and keeping it so by pressure with the thumb, by which the pipe may be carried in without

difficulty. A ligature should be passed round each pipe with a needle, taking care not to puncture any of the vessels.

Injection. The usual colours are to be selected; but instead of throwing the yellow into the vein, it should be pushed into the artery, for the artery here performs the function of a vein, and *vice versâ*. When there are two placentæ, there should be different colours used.

Dissection. The spongy substance is to be carefully dissected away from the injected vessels, the placenta soaked in cold water, to get rid of its blood, and then dried, curling the cord around it; and should the membranes not be much torn, they may be distended with curled hair over it.

Preservation. Varnish it well; fix its bottom in a case with a glass top.

THE HEART, *IN SITU*; WITH THE HEAD, AND ADJACENT VESSELS.

For this purpose choose the head of a young subject, or an adult, whose heart is free from fat. The liver, stomach, spleen, &c. are to be removed from the abdomen, and the aorta divided just as it gives off the cœliac artery. The incision into the chest should be carried through the integuments, from the trachea to the ensiform cartilage, the sternum sawed through, and bent one half on each side, from the extremity of the cartilages nearest the ribs; then divide one of the pulmonary veins as near as possible to the lungs, and remove a portion of bone over the longitudinal sinus of the dura mater.

Preparation. Having well soaked the parts in warm water, and squeezed the blood from the heart and vessels, by the inferior cava and pulmonary vein, put a pipe into the longitudi-

nal sinus of the dura mater, pointed towards the occipital bone another into the pulmonary vein, a third into the vena azygos, and one into the receptaculum chyli, or thoracic duct. Tie up carefully the aorta and the vena cava inferior, and put a strong ligature around the middle of each arm.

Injection. Three colours are required :—one for the arteries, which should be red ; another for the veins, which may be yellow or blue ; and the third for the thoracic duct, which should be white, to imitate chyle. Throw the red injection into the pipe in the pulmonary vein, which will fill the left auricle, ventricle, aorta, and all the arteries. The pipe in the head is for the yellow injection : by this will be filled the veins of the head, face, neck, and chest, the right auricle of the heart, the right ventricle, and the pulmonary arteries. Should the vena azygos not be injected, the yellow injection is to be thrown into it. A small quantity of white injection is sufficient for the thoracic duct.

Dissection. Remove the body by a transverse section at the last dorsal vertebra, then amputate the arms at their middle, saw away one side of the bones of the skull, and wash away the brain: then dissect away all the loose cellular membrane and fat, and expose the various parts in the best manner; dissect away the lungs, leaving the pulmonary arteries as long as possible.

Preservation. This is, when well done, a valuable preparation, and deserving of great care. Varnish it well, and preserve it in a square glass case.

A FŒTUS, TO EXHIBIT THE PECULIARITIES OF ITS CIRCULATION.

For this purpose select a still-born fœtus; and, if possible, one that died from a flooding of the mother.

Preparation. Dissect the umbilical vein from the arteries, about four inches from the umbilicus, and fix a pipe in it, taking care not to include the arteries. Throw warm water into this pipe, and wash out the blood, which will flow out by the umbilical arteries. Having drained away as much of the water as possible, tie a ligature very loose on the umbilical arteries.

Injection. The fœtus being heated, throw in gently any coloured injection. The water will come away first through the umbilical arteries; and, when the injection appears, make the ligature firm, to prevent its further egress.

Dissection. The peculiarities in the fœtal circulation are the umbilical cord, the ductus venosus, the ductus arteriosus, and foramen ovale. When the body is cold, proceed to the dissection; remove the head from the cervical vertebræ, the arms with the scapulæ, and pectoral muscles; the inferior extremity at the articulation with the pelvis, the whole of the parietes of the abdomen, leaving the arteries running to the cord by the sides of the bladder; the anterior part of the thorax, with the sternum, cartilages, and part of the ribs, the teguments and muscles of the back. Next cut away the lungs, and remove the pericardium; keep the diaphragm in its place, and turn up the liver, so as to expose the ductus venosus. Some discretion and care are here necessary. Dissect away the stomach and intestines, and lay out the mesenteric vessels; distend the bladder with air, and cut away any thing that may obstruct the view of the vessels. The foramen ovale cannot be exhibited.

Preservation. After having varnished it, hang it in a glass bell, with a hook at its top.

PENIS.

The penis may be injected, to shew the two corpora cavernosa, the corpus spongiosum, and glans, with the arteries and veins. For this purpose any healthy penis will do, but large ones are generally preferred. Having cut through the integuments and soft parts in the pelvis, in the direction the saw is to be passed, saw through the middle of each crista of the pubis, straight down and through the ascending ramus of each ischium, close to their commencement, and thus remove the pubis, with the bladder and external parts of generation.

Preparation. Make an incision into either of the crura of the corpora cavernosa, and into the bulbous part of the urethra, as near to the prostate gland as possible; soak it in hot water, and carefully press out the blood from every part. Introduce a probe along the vena magna ipsius penis, by an incision at its root, to break down its valves; fix a pipe in each of these incisions, and another in each vas deferens, at its entrance into the vesiculæ seminales, and secure all the divided vessels.

Injection. Four colours are necessary; those generally preferred are red, yellow, blue, and white. Throw the red into the corpus spongiosum, which will distend the glans; the yellow into the corpus cavernosum pipe; the blue into the vena magna ipsius penis; and the white into the vasa deferentia.

Dissection. Inflate the bladder, dissect away all the soft parts, and keep the penis erect against the symphysis pubis.

Preservation. In a covered box.

TESTICLE.

A testicle of an adult should be chosen free from disease, and great care is requisite in removing it from the body. First, enlarge the ring of the oblique muscle, push the testicle through from the scrotum, and separate its cellular connecting substance; then cut the spermatic artery and pampiniform plexus as high as possible, and then the vas deferens.

Preparation. When well soaked, press out the blood from the veins; put a pipe into the spermatic artery, and another into a vein; and secure all other open mouths.

Injection. Red is to be sent into the artery, and yellow or blue into the vein, which is without valves. Then fix the quicksilver tube in the vas deferens, and suspend it in water; this done, fill it with mercury, and in twenty-four hours it may be removed to be dissected.

Dissection. Cut away the tunica vaginalis and the tunica albuginea, which requires great care: then remove all the cellular and adipose membrane, and dry it on a board previously waxed.

Preservation. In a common preparation-glass, on a blue or green paper ground.

THE SYSTEM OF THE VENA PORTÆ.

Remove the liver, spleen, stomach, and intestines all together, of a person whose mesentery is free from fat, cutting away at the root of the mesentery, behind the peritoneum.

Preparation. Cut into a mesenteric vein, as near to the intestine as possible, and secure it with a ligature passed around it with a needle, taking care not to wound any other vein.

Inject warm water, and let it again run out by the divided vessels. Drain its water off, and secure all the veins, the hæmorrhoidal especially.

Injection. Throw any colour into the pipe, which will pass into the splenic, mesenteric, and internal hæmorrhoidal vein, and into the vena portæ.

Dissection. Remove all the soft parts; the stomach, spleen, and intestines; cutting the vessels as long as possible, and dry them in the best manner, either attached to the liver, or dissect away the liver from the vena portæ, taking care to preserve some of its ramifications.

Preservation. In a covered box.

HEART.

The heart is mostly injected out of the body, to shew its common and proper vessels. For this purpose, choose a lean heart. Cut through the thoracic viscera immediately at the top of the thorax; divide the intercostal arteries by drawing the knife down the pleura, over the ribs beyond their origin; separate the vena cava inferior and aorta, in the abdomen, with the cavæ hepaticæ; and remove the thoracic viscera, with the portion of the diaphragm surrounding the vessels.

Preparation. Soak the blood and coagula out of the cavities of the heart, and press the blood from the coronaries. Put a pipe into the vena cava superior, and another into one of the pulmonary veins. Then tie the lungs at their root, the vena cava inferior, the arteria innominata, the left carotid and subclavian; and pass a ligature, with a slip-knot, round the sinus of the aorta, and secure all other open vessels.

Injection. The common coloured injections, red and yellow, only are wanted. Throw the former into the pulmonary vein,

which will fill the left auricle, ventricle, aorta, and coronary arteries. The yellow, being sent into the superior cava, will distend the right auricle, coronary veins, right ventricle, and pulmonary artery. In order to fill the coronaries well, the injector must stop two or three times in the course of the process, to squeeze on the injection in them with his nail; then heat the whole again, and throw in more injection. The preparation having cooled, a pipe is to be fixed at the bottom of the aorta, and some red injection, just hot enough to run through the syringe, is to be pushed along the aorta, an assistant throwing cold water on the intercostals, if the injection runs through them.

Dissection. Cut away the lungs, pericardium, and all the soft parts.

Preservation. Either in a covered box, or under a glass bell.

STOMACH. INTESTINES. BLADDER.

These are best injected with the whole subject, but may be removed and injected separately.

GENERAL OBSERVATIONS.

1. The anatomist can only succeed by having the preparation constantly heated as he is throwing in the injection.

2. The injection should be thrown in very gradually.

3. When injected, the part should be immediately immersed in cold water.

PREPARATIONS WITH MINUTE INJECTION.

BONES.

The vascularity of bones is to be demonstrated, by throwing fine injection into an extremity, cutting out the bone when cold, separating it from all the soft parts, immersing it in water for a few days, to soak out the blood, and then putting it into a mixture of muriatic acid and water in the proportion of one ounce to a quart, for three or four months, adding about every month, a drachm of acid. The limb of a ricketty child is to be chosen.

Injection. Put a pipe into the largest artery of the extremity, and throw gradually the red injection into it, fixing the stop-cock in the pipe.

A FŒTUS.

Still-born children, when injected with minute injection, afford a number of beautiful preparations.

Preparation. No water should be thrown into the vessels. Fix a pipe with a stop-cock into the umbilical vein, and tie the arteries in the ligature.

Injection. Red injection is always chosen for this purpose; and throw it in with great care, until the abdomen and skin all over become very tumid. First, mucus comes from the nose and mouth, then the meconium from the anus, and often pure size.

Dissection. Cut off the head from the shoulders, the arms below the shoulder-joint, and the legs just below the acetabulum; then preserve a small quantity of the integuments

around the navel, and remove all the anterior parietes of the abdomen and chest, so as to exhibit the thoracic and abdominal viscera. Cut away the integuments and posterior part of the theca vertebralis, to exhibit the medulla spinalis.

Preservation. Soak out the blood, and preserve it in proof spirit, to shew the viscera and their vascularity.

From a well-injected fœtus may be obtained the following preparations:

1. If the fœtus be about seven months old, the *membrana pupillaris.*

2. If it be a male of this age, the *testicle* in the abdomen, with the *gubernaculum.*

3. The *vascular* and radiated fibres of the *parietal bones.*

4. The *vascular membrane,* including the *teeth.*

5. The *viscera of the chest* separate, if better injected than those of the abdomen, shewing the vascularity of the lungs, thymus gland, and heart.

6. The *stomach,* which is to be inverted, to shew its vascular *villous coat.*

7. The *intestines,* which are to be separated from the mesentery, and inverted, to shew their *villous coat.*

8. The *glandulæ renales* and *kidneys* together, to exhibit their relative size, and the lobulated structure of the kidney.

9. The *uterus and its appendages,* to shew the long ovaria and plicæ of the neck of the uterus and vagina.

10. The external parts of the female organs of generation, to shew the *hymen.*

11. A red portion of the *skin,* to exhibit its vascularity.

12. The *medulla spinalis,* to shew its vessels, and the *cauda equina.*

13. The *membrana tympani,* to exhibit its vascularity.

14. The *cavity of the tympanum*, to shew its vascularity, and that of the periosteum of its bones.

15. The *vestibulum and cochlea*, to shew the membranous semicircular canals of the former, with their ampullæ injected, and the vascularity of the zona mollis.

16. The *head*, to shew the natural appearance of the face, the papillæ of the lips, tongue, &c.

17. The *hand*, to shew its natural colour.

Preservation. The above preparations are all to be well soaked from their blood, and preserved in proof spirit of wine.

18. A portion of *skin*, freed of its adeps, to shew its vascularity.

19. The *membrana tympani*, to shew its vessels.

20. The *heart*, to shew the foramen ovale, by distending the cavities with air; and, when dry, cutting away the outermost sides of the auricles, and introducing a bristle.

21. Any large muscle, freed from its cellular membrane and fat, and dried, to shew the *vascularity of the muscle*.

Preservation. These are all to be dried, well varnished, and preserved in bottles. Some prefer putting them into spirit of turpentine; but this should be avoided as much as possible, for the turpentine is always oozing in warm weather, and dirtying the glass.

UTERUS.

The object of injecting a uterus with fine injection is to exhibit the vascularity of its internal membrane, which furnishes the catamenia. For this purpose the uterus of a person whose menstruation has not been stopped by age or disease is to be selected.

Preparation. Remove the uterus, by dividing the vessels as

long as possible, the round and broad ligaments, and as much as possible of the vagina. Tie a pipe in each hypogastric artery, and secure all the divided vessels.

Injection. Any coloured injection may be chosen, but red looks best.

Dissection. Cut away all the loose cellular membrane, bladder, and rectum, if there be any, from around the vagina, and cut it open along the middle of its superior part; continue this incision on each side of the anterior part of the uterus, so as to exhibit the posterior surface of its cavity.

Preservation. If the injection be successful, which it seldom is more than one time in ten, suspend it by the ligaments, and preserve it in proof spirit.

AN ADULT HEAD.

Separate the head as low as the last cervical vertebra from the shoulders.

Preparation. Put a bifurcated pipe into the carotids. Secure the vertebral arteries and jugular veins, and all the divided parts.

Injection. The red injection is always preferred.

From an adult head injected in this way may be made the following preparations:

1. The upper eyelid, to shew the vascularity of *Meibomius's glands.*

2. The *choroid membrane*, exhibiting its vascularity.

3. The *retina*, suspended by the optic nerve, exhibiting its vascularity.

4. A section of the optic nerve, to exhibit the *central artery.*

5. The whole of the *cerebrum*, *cerebellum*, and *medulla oblongata*, with the pia mater; or,

6. The pia mater, separated from the convolutions of the brain, to exhibit the *intergyral processes* and the *tomentum cerebri.*

7. One half of the nostrils, to exhibit the vascularity of *Schneider's membrane,* and that of the membrane lining the antrum of Highmore.

8. The *tongue,* lying in the jaw, and suspended by the *palatum molle,* with the posterior fauces cut away, to shew the *epiglottis* and *glottis,* the *uvula* and *velum pendulum palati,* the tongue, its papillæ and excretory ducts, and the vascularity of the gums and *sublingual glands.*

Preservation. The above preparations are to be soaked well in cold water, to get out all the blood, and then preserved in proof spirit.

PREPARATIONS WITH QUICKSILVER.

Mercury cannot be coloured by any substances; it must, therefore, always present the same silver colour.

GENERAL OBSERVATIONS.

1. The parts should always be injected in a proper tray, made similar to the wood-cut at the beginning of this section, that the mercury may be easily collected.

2. A lancet, with a curved needle ready threaded, should be always at hand; and likewise,

3. A bottle, whose neck is not so wide as to permit the quicksilver tube going to the bottom, when put into it.

4. When injecting, if any circumstance render it necessary for the injector to put aside the tube with the mercury, it should be placed in the bottle, the mercury remaining in it, to be handy and prevent delay.

5. Injecting with mercury is always tedious, and frequently unsuccessful. The parts exposed must be kept moist by sprinkling them with cold water.

A SUPERIOR EXTREMITY.

To inject the lymphatics of an arm, choose one from a dropsical subject, without fat; make an incision into the skin around the wrist, and seek diligently with a magnifying-glass, for an absorbent, into which the pipe is to be put; when the quicksilver will immediately run. The shoulder should now be placed considerably lower than the hand; and, when the mercury runs out at the divided vessels in the axilla, tie them up, and also the lymphatic, into which the pipe was introduced. Then seek for another absorbent. When the mercury ceases to run in a lymphatic, press it a little forward; and if that do not succeed, tie the vessel, and seek for another.

Dissection. Begin at the lymphatics, where the mercury entered, and trace them; removing every thing that obstructs their view: but preserve the glands.

AN INFERIOR EXTREMITY.

The limb for this purpose should also be taken from a dropsical person, and the same method adopted as with the superior extremity, seeking as near to the toes as possible for the lymphatics.

A PAROTID GLAND.

Cut down upon the masseter muscle, and seek for the Stenonian duct, which is the excretory duct of the parotid. Tie the quicksilver pipe in it, then fix the tube, and pour into it the quicksilver; and, when it ceases to run, remove the tube and pipe, and tie the duct. Be particularly careful, in dissecting away the gland, not to cut it.

Preservation. Dry it on a waxed board, and preserve it on a blue paper and pasteboard, in spirit of turpentine.

LIVER.

The lymphatics running on the peritoneal coat of the liver, and over the gall-bladder, make a beautiful preparation. The liver should be well soaked for several days, and the pipe put into the lymphatics of the suspensory and coronary ligaments, and the mercury forced along them, breaking down the valves with the nail, by pressing on the mercury. Secure the vessels at the portæ of the liver, when the mercury gets there, and tie the lymphatics when filled. Should the anatomist's attempt to force the quicksilver beyond the valves be unsuccessful, he must fix upon the most minute obvious branch, and let it run its proper course.

Preservation. Throw some coarse injection into the cavæ hepaticæ and vena portæ, without heating the liver thoroughly; inflate the gall-gladder, and dry the whole. Varnish it, and preserve it in the best manner under a glass bell, or preserve the injected part in proof spirit, without any wax injection.

LUNGS.

The superficial lymphatics of the lungs are to be filled from the part most remote from the root of the lungs.

Preservation. Cut away the part on which the lymphatics are filled. Dry it on a waxed board, varnish it, and preserve it in a bottle, on a green or blue piece of paper; or preserve it in proof spirit, without drying it.

HAND.

Select the hand of an aged female (separated from the arm by a transverse section, three inches above the wrist) that has died of a lingering disease. Soak out the blood in warm water; fix the pipe in the radial artery, then add the tube, and pour into it the mercury. As the mercury appears in the other arteries and veins, take them up and secure them with ligatures. Should the mercury still escape from small branches, put a cord round the arm, and, with a piece of wood, tighten it, by twisting the wood, taking care not to prevent the mercury passing into the hand. Then suspend the hand in a glass filled with water, and suspend also the tube and quicksilver in the manner represented in the annexed plate, for a day or two, that the mercury may get into the small vessels. When injected, remove the pipe, and tie, by a strong string, the fore-arm; put the hand into water, until putrefaction separates the cuticle.

Preservation. Dry it carefully, and varnish it; then fix the fore-arm in a pedestal of plaster of Paris, and keep this beautiful preparation under a glass bell.

LACTEALS.

Remove the mesentery and intestines, if the former be perfectly free from fat, and let them remain several days in water, which should be frequently changed. Search for an

absorbent, on the intestine, into which introduce the quicksilver, which will run on to the glands in the mesentery, where it will stop. When the lacteals are filled, the preparation will be more elegant if red and yellow coarse injection be thrown into the mesenteric arteries and veins.

Preservation. Spread the mesentery on a waxed board, inflate a portion of the intestine, clear away all that is useless; dry and varnish, and preserve it in a glass frame.

CORRODED PREPARATIONS.

These preparations are made by filling the vessels with coarse injection, and corroding the soft parts, so as to exhibit those vessels.

GENERAL OBSERVATIONS.

1. The liquor for corrosion is to consist of three parts of muriatic acid, and one of water.

2. The liquor should be kept in a well-glazed earthen vessel, with a top to it, also well glazed.

3. The part to be corroded should be carefully moved in and out of this liquor, as the slightest force may break the vessels.

4. When corroded, the pulpy flesh is to be carefully washed away, by placing it under a cock of water, the water flowing very slowly; or, in some instances, by squirting it away.

5. When the preparation is freed of its flesh, it should be fixed in the situation it is to remain in, either in a plaster of Paris pedestal, or on a flat surface.

6. If the flesh be not perfectly destroyed, the preparation is to be returned to the corroding liquor for a fortnight or month longer, or until it becomes pulpy.

HEART AND LUNGS.

These viscera, occupying less space in children than adults, are to be preferred from the former. It is of no consequence whether they are fat or lean. The integuments should be cut from the fore-part of the neck; and the trachea, jugular veins, and carotid arteries removed, and, with them, the viscera of the thorax; carefully separating the subclavian vessels from the clavicle, without injuring them, and dividing the axillary vessels and the cava inferior and aorta, just below the diaphragm.

Preparation. Soak the whole well, to free it of its blood, and press out all the fluids: fix a pipe in the inferior cava, and another in one of the pulmonary veins, taking care not to injure the others, by tying it. Then secure the carotids, the jugulars, the axillary vessels, the vertebral artery, the intercostals, the aorta, after it has formed its arch, the internal mammaries, and every vessel that can be found.

Injection. Red and yellow are generally preferred, but red and blue are more proper, and more elegant. Throw the blue into the vena cava inferior, which will distend the right auricle, the superior cava, the jugular veins, and great coronary vein, the right ventricle, and pulmonary arteries. The red injection will fill the left auricle and pulmonary veins, the aorta, subclavians, carotids, &c.

Preservation. Great care is requisite in freeing the injection from the pulpy flesh. When done, let the apex of the heart be placed immediately in a plaster-of-Paris pedestal, and cover it with a glass. If the pulmonary vessels are well

preserved, it forms a valuable preparation. If one good preparation be obtained in ten trials, it will amply repay the anatomist.

HEART.

A fat heart will do for this purpose. Inject it as directed in page 345, and put it into the corroding liquor.

Preservation. Lay it on some cotton, on a pedestal, and cover it with a glass.

LIVER.

The liver of a child is to be preferred to that of an adult, it occupying much less room: its vessels should be cut long, and with it the portion of the duodenum, perforated by the bile-duct.

Preparation. Fix a pipe into the hepatic artery, another nto the vena portæ, a third into the ductus communis choledochus, and a fourth in the vena cava hepatica.

Injection. The four injections are the red, yellow, dark blue, and light blue. First, throw the red injection into the hepatic artery, next the dark blue into the vena portæ, then the light blue into the cavæ hepaticæ, and lastly, the yellow into the ductus communis choledochus.

Preservation. Remove the pipes as soon as the injection will permit; and, when corroded, fix the trunks in the best manner possible, upon a proper pedestal: then wash away the flesh, dry it, and cover it with a glass.

KIDNEY.

Choose the kidney of an old drunkard. Cut the emulgent vessels close to the aorta and cava, and the ureter, very low; then remove the kidney with all its surrounding adeps.

Preparation. Soak out the blood, and press out all the fluid. Fix a pipe in the emulgent artery, another in the vein, and a third in the ureter; and tie up all the open-mouthed vessels.

Injection. Red, blue, and yellow. First throw the yellow into the vein, then the red into the artery, and lastly, the blue into the ureter.

Preservation. Under a glass bell. The kidneys of different animals form a beautiful exhibition.

ANATOMICAL, PHYSIOLOGICAL, SURGICAL, AND MEDICAL QUESTIONS, &c.

TO BE LEARNT BY EVERY STUDENT PREVIOUS TO HIS EXAMINATION AT SURGEONS' HALL, THE MEDICAL BOARD, &c.

1. HOW many bones compose the cranium?
2. What is the union of the bones of the skull termed?
3. Describe the situation of the sphænoid bone.
4. Into how many portions is the temporal bone dist[illegible]guished?
5. In what bone is the organ of hearing situated?
6. How many tables have the bones of the cranium?
7. What is the name of the substance which unites the two tables of the cranium?
8. What is the name of the suture which connects the frontal with the parietal bones?
9. By what suture is the occipital bone united to the parietal bones?
10. What name is given to the suture which connects the parietal bones?
11. How many species of sutures are there?
12. What bones are united by the false sutures?
13. Through what foramina do the olfactory nerves pass out of the cranium?
14. Where is the foramen magnum occipitale situated?

15. To what bone does the crista galli belong?
16. To what bone does the sella turcica belong?
17. Describe the frontal bone.
18. Where is the os ethmoides situated?
19. What bone separates the ethmoid from the occipital bone?
20. To what bone does the mastoid process belong?
21. How many bones compose the orbit?
22. How many bones compose the lower jaw?
23. What bones form the septum narium?
24. To what bone do the superior turbinated bones, as they are called, belong?
25. In what bone is the antrum of Highmore situated?
26. What separates the antrum of Highmore from the orbit?
27. Is there any communication between the orbit and the nostril?
28. What is the name of the process of the lower jaw to which the temporal muscle is attached?
29. Is there any communication between the tympanum of the ear, and back part of the mouth?
30. How many bones are there in the tympanum?
31. To what bone of the cranium does the styloid process belong?
32. What bones form the foramen lacerum in basi cranii?
33. What are the processes of the sphænoid bone called, which form the sides of the posterior nostrils?
34. What passes through the foramen lacerum in basi cranii?
35. Does the os palati form any part of the orbit?
36. Where is the vomer situated?
37. Point out the situation of the zygomatic processes on the face.
38. Where is the os unguis situated?

39. What is the name of the portions of the os ethmoides which hang down into the nostrils?
40. What is the shape of the os malæ?
41. What are the bones called which compose the spine?
42. Describe the spine.
43. What is there peculiar to the second vertebra?
44. How would you distinguish a dorsal vertebra from the rest?
45. Where is the os hyoides situated?
46. Describe the scapula.
47. What bone is fixed to the acromion scapulæ?
48. How many bones has the fore-arm?
49. Where is the ulna situated?
50. On what bone do we lean when on our elbow?
51. What is the process called on which we lean?
52. How many bones are in the shoulder-joint?
53. How many bones compose the elbow-joint?
54. What bone unites the arm to the thorax?
55. How many bones compose the carpus?
56. What receives the head of the os femoris?
57. Where is the *os tincæ* situated?
58. What bone supports the leg?
59. How many bones compose the tarsus?
60. Where is the trochanter major situated?
61. On what bone is the linea aspera?
62. What are the processes on the lower end of the os femoris called?
63. How many bones compose the knee-joint?
64. What are the bones of the leg called?
65. What is the shape of the tibia?
66. What bone forms the inner ankle?
67. What bone forms the outer ankle?

68. What are the names of the bones of the tarsus?
69. How many bones compose the pelvis?
70. How would you distinguish a male from a female pelvis?
71. Into how many portions is the os innominatum distinguished?
72. What separates the ossa innominata from each other behind?
73. Is there any bone between the ossa innominata anteriorly?
74. Where is the os coccygis situated?
75. What is the name of the cavity that receives the head of the thigh-bone?
76. To what bone does the acetabulum belong?
77. What bones form the hip-joint?
78. Where is the tuberosity of the ischium?
79. Of what bone is the ascending ramus of the pubis a part?
80. What bones form the thorax?
81. What is the use of the periosteum?
82. Describe the contents of the cranium.
83. What membrane nourishes the internal table of the skull?
84. What does the falciform process of the dura mater separate?
85. What vessel runs in the falciform process of the dura mater?
86. Where is the tentorium situated?
87. How many lobes has the brain?
88. How many lobes has the cerebellum?
89. What are the cavities in the brain called?
90. What separates the lateral ventricles from each other?
91. From what part of the brain does the pineal gland arise?
92. From what part of the brain does the optic nerve arise?

93. What nerves pass through the foramen lacerum orbitale superius?

94. Through what foramina do the fifth pair of nerves pass out of the cranium?

95. Does the arm receive nerves from the brain, or from the spinal marrow?

96. What nerve supplies the nose for the sense of smelling?

97. What nerve supplies the diaphragm?

98. Where does the great sciatic nerve arise?

99. What is the name of that ganglion in the abdomen, which supplies most of the abdominal viscera?

100. What does the foramen magnum occipitale transmit?

101. How many membranes has the brain?

102. What are the processes of the dura mater called?

103. What are the viscera of the thorax?

104. How many lobes has the left lung?

105. What separates the chest into two cavities?

106. What are contained in the posterior mediastinum?

107. What is there in the anterior mediastinum of infants which disappears towards adult age?

108. Describe the heart.

109. Do the auricles of the heart communicate before birth?

110. Where is the Eustachian valve situated?

111. Where is the Eustachian tube situated?

112. What is the name of the valves at the origin of the aorta?

113. What are the differences between the fœtal and adult heart?

114. Where is the ductus arteriosus situated in the fœtus?

115. What viscera are contained in the abdomen?

116. What is the membrane called, that lines the cavity and covers the viscera of the abdomen?

117. Are the kidneys completely enveloped in the peritoneum?
118. Describe the stomach.
119. What viscera are attached to the greater curvature of the stomach?
120. Describe the liver.
121. What is the use of the liver?
122. What are the excretory ducts of the liver called?
123. How would you distinguish the small from the large intestines?
124. Describe the situation and course of the colon.
125. What is the excretory duct of the kidney called?
126. Describe the uterus.
127. Through what tube does the ovum pass from the ovarium into the uterus?
128. What is the excretory duct of the testicle called?
129. What is the proper juice of the stomach called?
130. Where is the spleen situated?
131. Describe the eye.
132. How many coats has the eye?
133. How many chambers has the eye?
134. What separates the anterior from the posterior chamber of the eye?
135. What is contained in the capsule of the crystalline lens?
136. What artery nourishes the crystalline lens?
137. Where is the pigmentum nigrum of the eye situated?
138. Where is the lachrymal sac situated?
139. What is situated in the groove at the lower internal edge of each rib?
140. What difference is there in the situation of the right and left kidney?
141. What are the ducts that enter the duodenum?

142. In what intestines are the valvulæ conniventes found?
143. What is the name of the duct leading from the pelvis of the kidney to the bladder?
144. What forms the linea alba?
145. How many openings has the right auricle?
146. Where do the ostia of the lacteals open?
147. How many openings has the left auricle?
148. What is the true organ of vision?
149. What is the general division of the internal ear?
150. What nerves form the great sympathetic?
151. Do the olfactory nerves supply the nose with the sense of feeling?
152. How many arteries are there?
153. What are the arteries called, which supply the kidney?
154. What is the name of the vessels which nourish the heart?
155. What are the blood-vessels of the stomach called?
156. Where is the popliteal artery situated?
157. What arteries are given off from the arch of the aorta?
158. What artery ramifies upon the anterior parietes of the abdomen?
159. What is the course and distribution of the epigastric artery?
160. What is the course of the femoral artery?
161. What are the terminations of arteries?
162. What are the veins at the flexure of the arm?
163. What muscles are inserted into the patella?
164. What is the name of the muscles which are inserted into the os calcis?
165. What is the name of the tendon which is formed by the gastrocnemius and soleus muscles?
166. Do the external condyles of the humerus give origin to the extensor or flexor muscles of the arm?

167. What muscles are attached to the coracoid process of the scapula?
168. Where is the diaphragm situated?
169. What are the muscles of the abdomen?
170. Where is the longest crus of the diaphragm situated?
171. What tendon passes through the shoulder-joint?
172. What are the salivary glands called?
173. Where is the thyroid gland situated?
174. Where is the pituitary gland situated?
175. Where is the lachrymal gland placed?
176. What are the most important fasciæ of the body?
177. What are the ligaments about the shoulder-joint?
178. What are the ligaments of the pelvis?
179. What is the name of the ligament which connects the os femoris to the bottom of the acetabulum?
180. What is the name of the ligaments within the joint which connect the condyles of the femur to the tibia?
181. What are the bursæ mucosæ, and their use?

---

182. The circulation of the blood.
183. How do you distinguish venal from arterial blood?
184. What is the contraction of the heart called?
185. In what viscus does the change from venal into arterial blood take place?
186. What is the colour of the blood in the pulmonary artery?
187. What is the cause of the bile regurgitating into the gall-bladder?
188. What is the use of the urinary bladder?
189. What is the use of the gastric juice?
190. What is the theory of ossification?
191. How is inspiration performed?

192. What is meant by secretion?

193. What change is produced on the blood in the lungs?

194. How is expiration performed?

195. What is meant by animal heat?

196. Why does not the fluid, exhaled to lubricate the different cavities of the body, accumulate?

197. How is nutrition effected?

198. What membrane moderates the effect of light on the retina?

199. What is the use of the fluid which fills the labyrinth of the ear?

200. Why does not the fat gravitate to the lower extremities after long standing; like the fluid of an anasarcous person?

201. Why does not the urine excite inflammation of the bladder?

---

202. What are the symptoms of compressed brain?

203. Does the radius or the ulna move in pronation and supination?

204. What are the symptoms of concussion of the brain?

205. How would you distinguish a fissure of the cranium from a suture?

206. What practice would you adopt to relieve concussion of the brain?

207. When a portion of the cranium is depressed, what would you do to elevate it?

208. When a portion of the cranium is depressed, where would you apply the trephine to raise it?

209. What do you mean by an exomphalos?

210. What is a bubonocele?

211. What do you mean by a hydrocele?

212. What are the symptoms of a strangulated intestine?

213. Describe the operation for strangulated inguinal hernia.

214. What method is to be taken if, after liberating a strangulated intestine by operation, a great quantity of irreducible thickened omentum exists?

215. What is the difference between a femoral and an inguinal hernia?

216. What are the circumstances by which you judge an operation is necessary to liberate a strangulated hernia?

217. What means would you have recourse to in order to reduce a strangulated hernia, before you judge it necessary to perform the operation?

218. What are the symptoms of suppression of urine?

219. How would you attempt to relieve a suppression of urine, in a medical point of view?

220. When these means fail to evacuate the urine, what would you have recourse to?

221. What do you mean by a popliteal aneurism?

222. Describe the operation for popliteal aneurism.

223. Describe the symptoms of a phlegmon.

224. How would you treat a phlegmon?

225. How would you treat a violent ophthalmia?

226. How would you treat gangrene in general?

227. When a locked-jaw arises from an injury of the great toe, how would you endeavour to relieve it?

228. When a ball is lodged in the calf of the leg, and it is necessary to make an incision upon it; in what direction would you make that incision?

229. How does the complete division of a punctured artery, as the temporal, stop the hæmorrhage?

230. What is the cause of the cold sensation and numbness of the leg and foot, generally felt from an aneurism of the popliteal artery?

231. If necessary to take up the brachial artery near the flexure of the arm, how will the circulation be carried on?

232. How is amputation of the shoulder-joint to be performed?

233. How many species of white-swelling are there?

234. What muscles are cut through in the operation for lithotomy on the male?

235. What are the peculiarities of a gun-shot wound?

236. How is an aneurismal tumour distinguished from other tumours?

237. What is the substance generally found in aneurismal sacs?

238. How is amputation below the knee to be performed?

239. What are the consequences that generally arise from wounded nerves?

240. What is meant by a compound fracture?

241. What takes place when a bone is denuded of its periosteum?

242. What bone is perforated in operating for fistula lachrymalis?

243. Why are luxations of the shoulder-joint more frequent than luxations of the hip-joint?

244. Under what circumstances is amputation of an extremity necessary?

245. What forms the sac in femoral hernia?

246. In what direction is Poupart's ligament to be divided, if necessary, to liberate strangulated femoral hernia?

247. How many ways are there of puncturing the bladder to relieve suppression of urine?

248. On what part of the arm is pressure to be made before amputation of the fore-arm?

249. At what part of the aorta do aneurisms most frequently take place?

250. What are the unfavourable circumstances in compound fracture, that require amputation of the extremity?
251. What are the signs of a fractured cranium?
252. What is the cause of stupor, or coma, in fracture of the cranium?
253. What is the medical treatment in fracture of the skull?
254. Why are fistulæ generally dilated?
255. How is the radical cure of hydrocele performed?
256. Where does a psoas abscess generally point?
257. What are the signs of a wounded artery?
258. What are the terminations of inflammation?
259. What method is to be taken after a cannon-ball has torn off a limb?
260. What are the circumstances which prevent the dilatation of gun-shot wounds to extract the extraneous body?
261. What is the treatment of gun-shot wounds?
262. What is the treatment of contused wounds?
263. What are the terminations of erysipelas?
264. Under what circumstances is an artificial anus to be formed?
265. How is gastroraphe performed?
266. How is emphysema produced from a wound of the thorax?
267. What is the treatment of wounds of the joints?
268. What is meant by spina ventosa?
269. What is the prognosis in wounds of the abdominal viscera?
270. How may an abscess of the liver rupture?
271. What symptoms accompany wounds of the abdominal viscera.
272. How is the hip-disease distinguished from an affection of the knee-joint, as the forerunning symptoms of the

hip-disease are generally pains about the knee, and no affection of the hip?

273. What do you mean by tetanus?
274. How would you treat inflammation of the bowels?
275. What is a dysentery?
276. How should dysentery be treated?
277. What are the symptoms of enteritis?
278. What are the symptoms of volvulus?
279. What are the symptoms of nephritis?
280. How do you distinguish hepatitis from gastritis?
281. What purges would you give in nephritis?
282. What are the symptoms of pneumonia?
283. How would you distinguish cystitis from enteritis?
284. When gangrene takes place in internal parts, what are the symptoms?
285. What are the symptoms of hydrocephalus?
286. What is a typhus fever?
287. What practice should be adopted in a typhus fever?
288. What is the best way to destroy the fetid smell of sick-wards?
289. What is meant by scrofula?
290. What is the best method of relieving inflammatory affections?

A GLOSSARY; OR, *Explanation of Anatomical Terms.*

A

Abdŏmĕn. *The cavity of the belly;* from *abdo*, to hide, as including the intestines and other viscera.

Acetābŭlum. *The cavity which receives the head of the thigh-bone;* from *acetum* vinegar: so called, because it represents the acetabulum, or saucer, of the ancients, in which vinegar was held for the use of the table.

Acĭni. *A species of gland;* from *acinus* a grape or berry.

Acrŏmĭon. *A process of the scapula;* from ακρος extremity, and ωμος the shoulder.

Adenology. *The doctrine of the glands;* from αδην a gland, and λογος a treatise.

Amnĭon. *A membrane that surrounds the fœtus, which is soft and shaggy;* from αμνιος a lamb's skin.

Amphiarthrŏsis. *A species of connexion of bones, which admits of an obscure motion;* from αμφω both, and αρθρωσις an articulation.

Anastomŏsis. *The communication of vessels with one another;* from ανα through, and στομα a mouth.

ANATOMY. *The dissection of the human body*; from ανα through, and τεμνω to cut.

ANCON. *The elbow*; from αγκων, from αγκαζομαι to embrace, απο τȣ αγκεισθαι ετερω οςεω το οςεον, because the bones meeting, and being there united, are folded one into another.

ANCONEUS. *A muscle*; so called from αγκων the elbow.

ANCONOID. *Process of the cubit*; from αγκων the elbow, and ειδος shape.

ANGIOLOGY. *The doctrine of the vessels*; from αγγειον a vessel, and λογος a treatise.

AORTA. Αορτη: from αηρ air, and τηρεω to keep: *an artery* so called, because the ancients supposed that only air was contained in it. It may rather be derived from αειρω to convey, as serving to convey the blood to the rest of the body.

APONEURŌSIS. *A tendinous expansion*: From απο from, and νευρον a nerve; from an erroneous supposition of the ancients, that it was formed by an expansion of a nerve.

APŌPHȲSIS. *A process of a bone*; from αποφυω to proceed from. A synonym of Process.

ARACHNOIDES. *A web-like membrane*; from αραχνη a spider, and ειδος likeness.

ARTERY. From αηρ air, and τηρεω to keep; because the ancients supposed that only air was contained in them.

ARTHRODĪA. *A species of connexion of bones*; from αρθροω to articulate.

ARYTÆNOIDES. *The name of two cartilages of the larynx*; also applied to *some muscles of the larynx*; from αρυταινα a funnel, and ειδος shape.

ASTRĀGĂLUS. *A bone of the tarsus*; so called from its resemblance to a die used in ancient games, from αςραγαλος a cockal, or die.

ATLAS. *The first vertebra of the neck*; so called, because it

sustains the head: from the fable of Atlas being supposed to have supported the world; or from ατλαω to sustain, because it sustains the head.

AZYGOS. *A term applied to parts without a fellow;* from the privative particle α, and ζυγος a yoke; because it has no fellow.

B

BRĀCHĬUM. *The arm:* hence *os brachii, brachialis externus,* &c.; from βραχυς short; because, in a well-proportioned man, it is shorter from the shoulder to the hands than from the hip to the feet.

BRŎNCHĬA. *The ramification of the trachea or wind-pipe;* from βρεχω to pour, because the ancients believed that the fluids were conveyed into the stomach by the bronchia.

BURSA. *A bag;* from βυρσα: generally applied to the bursæ mucosæ.

BURSALOGY. *The doctrine of the bursæ mucosæ;* from βυρσα a bag, and λογος a treatise.

C

CALVĀRĬA. *The top of the cranium;* from *calvus* bald.

CANCELLI. *Lattice-work;* generally applied to the reticular substance in bones.

CARDĬA. *The superior opening of the stomach;* from καρδια the heart; because it is situated near it.

CAROTID. *The name of some arteries of the neck and head;* from καροω to cause to sleep; for, if tied with a ligature, the animal becomes comatose, or has the appearance of being asleep.

CARPUS. Καρπος; *the wrist.*

CHŌRĬON. *The external membrane of the fœtus in utero,* Χωριον, from χωρεω to escape; because it always escapes from the uterus with the fœtus.

CHOROID. From χοριον the chorion, and ειδος likeness; so called on account of the many blood-vessels resembling the chorion.

CLAVĪCŬLA. *The clavicle, or collar-bone,* a diminutive of *clavis* a key; so called from its resemblance to an ancient key.

CLINOID. *Four processes of the sella turcica of the ethmoid bone* are so called; from κλινη a bed, and ειδος likeness; from their supposed resemblance to a couch.

CLĪTŎRIS. *A part of the female pudenda, enclosed by the labia majora;* from κλειω to enclose or hide.

CŌLON. *The first of the large intestines;* from κωλον, quasi κοιλον, from κοιλος hollow; it generally being found empty, and full of wind, in the dead body.

CONDYLE. *An eminence in any of the joints;* κονδυλος, from κονδυ an ancient cup shaped like a joint.

CORĂCO. Names compounded with this word belong to muscles which are attached to the coracoid process of the scapula; as coraco-hyoideus, &c.

CORACOID. From κοραξ a crow, and ειδος resemblance; shaped like the beak of a crow.

CORONARY. From *corona* a crown. *The vessels of the heart, stomach,* &c. are so called, because they surround the parts in the manner of a crown.

CORONOID. A process so called, from κορωνη a crow, and ειδος likeness; from its resemblance to a crow's beak.

COTYLOID. From κοτυλη the name of an old measure, and ειδος resemblance; *resembling the kotule.*

CRĀNĬUM. *The skull;* κρανιον, quasi καρανιον, from καρα the head.

CREMASTER. *A muscle* so called; from κρεμαω to suspend; because it suspends the testicle.

CRIBRIFORM. From *cribrum* a sieve; it being perforated like a sieve.

CRICOID. *Annular, round, like a ring*; from κρικος a ring, and ειδος likeness.

CRURA. The plural of *crus*, a leg or root; applied to some parts of the body, from their resemblance to a leg or root, as crura cerebelli, &c.

CUBOIDES. *A bone of the foot*; from κυβος a cube, and ειδος likeness; because it resembles a cube.

CUNEIFORM. *Some bones are so called*; from *cuneus* a wedge, and *forma* likeness; being shaped like a wedge.

D

DARTOS. *A muscle of the scrotum*; from δερω to excoriate.

DELTOID. *A muscle resembling the Greek letter* Δ: from Δ, and ειδος resemblance.

DIAPHRAGM. *The muscle which separates the thorax from the abdomen*; from διαφραττω to divide.

DIARTHROSIS. *A moveable connexion of bones*; from διαρθροω to articulate.

DIGASTRIC. From δις twice, and γαστηρ a belly; having two bellies.

DIPLÖE. *The spongy substance between the two tables of the skull*; from διπλοω to double.

DUODENUM. *The first portion of the small intestines*; so called because the ancients supposed that it did not exceed the breadth of twelve fingers; from *duodenus*, consisting of twelve.

DURA MATER. *The outermost membrane of the brain*; called *dura*, because it is much harder than the other membranes, and *mater*, from the ancients supposing it was the source of all the other membranes.

E

EMBRYO. *The child in the womb* is so called before the fifth month, after which it is termed *fœtus*; from εμϐρυω to bud forth.

ENARTHROSIS. *An articulation of bones*; from εν in, and αρθρον a joint or articulation.

ENTERIC. *Belonging to the intestines*; from εντερον an entrail or intestine.

EPIDERMIS. *The scarf or outermost skin*; from επι upon, and δερμις the skin.

EPIDIDYMIS. *The small oblong body which lies above the testicles*; from επι upon, and διδυμος a testicle.

EPIGASTRIC. *The superior part of the abdomen*; from επι upon, and γαστηρ the stomach.

EPIGLOTTIS. *A cartilage of the larynx* so called; from επι upon, and γλωττις the aperture of the larynx; being situated upon the glottis.

EPIPHYSIS. *A portion of bone growing upon another bone, but separated from it by a cartilage*: from επι upon, and φυω to grow.

EPIPLOON. *The membranous viscus of the abdomen, which covers the intestines, and hangs to the bottom of the stomach*; from επιπλεω to swim upon.

EPISTROPHÆUS. *The second vertebra of the neck*; from επιστροφαω to turn round; because the head is turned upon it.

ETHMOID. From εθμος a sieve, and ειδος resemblance; being perforated like a sieve.

F

FASCIA. *An expansion of a muscle, inclosing others like a band*; from *fascis* a bundle.

FALCIFORM. *Shaped like a sickle;* from *falx* a sickle.

FASCĬCŬLUS. *A little bundle,* dim. of *fascis* a bundle.

FAUCES. The plural of *faux* the top of the throat.

G

GALACTOPHĔROUS. From γαλα milk, and φερω to carry; conveying the milk.

GANGLĬON. Γαγγλιον, a knot in the course of a nerve.

GASTROCNĒMĬUS. *The muscle which forms the thick of the leg;* from γαστηρ a belly, and κνημη the leg.

GENĬO. Names compounded with this word belong to muscles which are attached to the chin, as genio-glossus—genio-hyoideus—genio-pharyngeus, &c.; from γενειον the chin.

GENU. *The knee;* from γονυ, παρα το εις γην νευειν, because by it the body is bent towards the earth.

GINGLȲMUS. *An articulation;* from γιγγλυμος a hinge.

GLENOID *cavity.* From γληνη a cavity, and ειδος resemblance.

GLOMER. *A convoluted bundle of vessels;* generally applied to the lymphatic glands.

GLOSSO. Names compounded with this word belong to muscles which are attached to the tongue; as glosso-pharyngeus—glosso-staphilinus, &c.; from γλωσσα the tongue.

GLOTTIS. *The superior opening of the larynx at the bottom of the tongue;* from γλωττα the tongue.

GLUTÆUS. *The name of a muscle;* from γλουτος the buttocks.

GOMPHŌSIS. Γομφωσις inclavation, *a species of immoveable connexion of bones;* from γομφος a nail; because one bone is fixed in another bone like a nail in a board.

H

HARMŌNIA. *A species of immoveable connexion of bones;* ἁρμονια, from ἁρω to fit together.

Hĕlix. *The outward circle of the ear ;* from ειλω to turn about.

Hēpar. *The liver.* Ἡπαρ, *an abdominal viscus.*

Hyaloid. From ὑαλος glass, and ειδος likeness : the capsule of the vitreous humour of the eye is so called, from its *transparent* and *glassy appearance.*

Hygrology. *The doctrine of the fluids ;* from ὑγρος a fluid, and λογος a treatise.

Hymen. *The membrane situated at the entrance of the virgin vagina ;* from Ὑμην Hymen, the god of marriage.

Hyo. Names compounded with this word belong to muscles which are attached to the os hyoides, as hyo-glossus—hyo-pharyngeus—hyo-thyroideus ; from ὑοειδες the os hyoides.

Hyoidēs. *A bone of the tongue, so called from its resemblance to the Greek* Υ ; from υ, and ειδος resemblance.

Hypochŏndrĭum. *That part of the body which lies under the cartilages of the spurious ribs ;* from ὑπο under, and χονδρος a cartilage.

Hypogastric. *The lower region of the fore part of the abdomen ;* from ὑπο under, and γαστηρ the stomach.

I

Ilĕum. *A portion of the small intestines ;* from ειλεω to turn ; being always convoluted.

Ilium. *Part of the os innominatum ;* so called because it supports the ειλεια, or small intestines.

Ischĭum. *The part of the os innominatum upon which we sit ;* from ισχυω to sustain.

L

Lacūna. *The excretory duct of the glands of the urethra and vagina ;* from *lacus* a channel.

Lambdoidal *suture.* So called because it is shaped like the letter λ: from λ, and ειδος resemblance.

Larynx. *The superior part of the windpipe;* λαρυγξ the larynx.

M

Masseter. *A muscle of the face, which assists in the action of chewing;* from μασσαομαι to chew.

Mastoid. From μαςος a breast, and ειδος likeness; *shaped like a nipple or breast.*

Mediastīnum. *The production of the pleura, which divides the thorax into two cavities;* from *medium* the middle, *quasi in medio stare.*

Mesentĕry. *The membranes to which the intestines are attached;* from μεσος the middle, and εντερον an intestine; because it is in the middle of the intestines.

Mesocōlon. *That part of the mesentery in the middle of the colon;* from μεσος the middle, and κωλον the colon.

Metacarpus. *That part of the hand between the carpus and fingers;* from μετα after, and καρπος the wrist.

Metatarsus. *That part of the foot between the tarsus and toes;* from μετα after, and ταρσος the tarsus.

Mylo. Names compounded with this word belong to muscles which are attached near the grinders, as *mylo-hyoides—mylo-pharyngeus,* &c.; from μυλη a grinder-tooth.

Myology. *The doctrine of the muscles;* from μυς a muscle, and λογος a treatise.

N

Neurology. *The doctrine of the nerves;* from νευρον a nerve, and λογος a treatise.

O

Odontoid. *Tooth-like;* from οδυς a tooth, and ειδος resemblance.

Œsophăgus. *The canal leading from the pharynx to the stomach;* from οιω to carry, and φαγω to eat; because it carries the food into the stomach.

Olecranon. *The elbow, or head of the ulna;* from ωλενη the cubit, and κρανον the head.

Omentum. *An abdominal viscus;* so called from *omen* a guess; because the soothsayers prophesied from the inspection of this part.

Omo. Names compounded with this word belong to muscles which are attached to the scapula, as *omo-hyoideus,* &c. from ωμος the shoulder.

Omoplăta. *The scapula* or *shoulder-blade;* from ωμος the shoulder, and πλατυς broad.

Orgasm. *A violent salaciousness, attended with turgescence in the parts;* from οργαω to desire vehemently.

Osteology. *The doctrine of the bones;* from οςεον a bone, and λογος a treatise.

P

Pancreas. *A viscus of the abdomen;* so called from its fleshy consistence; from παν-all, and κρεας flesh.

Parenchȳma. *The substance connecting the vessels,* &c. of the lungs is so called; from παρεγχυω to pour through.

Parotid *gland;* from παρα near, and ες the ear; because it is situated near the ear.

PELVIS. *A bony cavity shaped like a bason;* from πελυς a bason.

PERICARDĬUM. *The membrane which surrounds the heart;* from περι around, and καρδια the heart.

PERICRANĬUM. *The membrane which covers the bones of the skull;* from περι around, and κρανιον the cranium or head.

PERIOSTĔUM. *The membrane which surrounds the bones;* from περι around, and οςεον a bone.

PERISTALTIC *motion of the intestines;* from περιςελλω to contract.

PERITONĔUM. *The membrane lining the abdomen, and covering its viscera;* from περιτεινω to extend around.

PHALANX. *The bones of the fingers and toes* are called phalanges, from their regular situation, like a φαλαγξ or army of soldiers.

PHARYNX. *A membranous bag at the end of the mouth;* απο τε φερειν, because it conveys the food into the stomach.

PHRENIC or *diaphragmatic nerve.* Φρενες the diaphragm; from φρην the mind; because the ancients supposed it to be the seat of the mind.

PHYSIOLOGY. *That part of natural history which treats of the actions and functions of an animated body;* from φυσις nature, and λογος a treatise.

PIA MATER. *The innermost membrane of the brain;* so called because it embraces the brain as a good mother folds her child.

PLACENTA. *The after-birth;* from πλακες a cake, on account of its resemblance to a cake.

PLATȲSMA-MYOIDES. *A muscle of the neck;* from πλατυς broad, μυς a muscle, and ειδος resemblance.

PLEURA. *The membrane lining the thorax;* πλευρα the side.

PLEXUS. *A kind of net-work of vessels or nerves;* from *plecto* to weave together.

PRÆPUCE, or *foreskin of the penis;* from *præputo* to cut off before; because the Eastern nations usually cut it off.

PSOAS. *A muscle* so called; from ψοα the loin, being situated in the loins.

PTERYGOID *process.* From πτερυξ a pen or wing, and ειδος likeness; so called from its likeness to a pen or wing.

PYLŌRUS. *The lower orifice of the stomach, which opens into the intestines;* from πυλοω to guard an entrance; because it guards as it were the entrance of the bowels.

R

RAPHĒ. *A suture,* ῾Ραφη: from ῥαπτω to sew.

RENĒS. *The kidneys,* απο τȣ ῥειν, because through them the urine flows.

RETĬNA. *The net-like expansion of the optic nerve, on the inner surface of the eye;* from *rete* a net.

RHOMBOIDĒS. *A muscle so called from its shape;* from ῥομβος a geometrical figure, whose sides are equal but not right-angled, and ειδος a likeness.

ROTŬLA. *The knee-pan;* a dim. of *rota* a wheel, from its shape.

S

SACRUM. *A bone so called;* from *sacer* sacred, because it was once offered in sacrifices.

SALVATELLA. *A vein of the foot,* so called because it was thought the opening of it preserved health, and cured melancholy: from *salvo* to preserve.

SANGUIS. *The blood;* απο τȣ σαειν γυια, because it preserves the body.

SARTORĬUS. *A muscle so called, because tailors cross their legs with it;* from *sartor* a tailor.

SCĂPHA. *The depression of the outer ear before the anti-helix;* from σκαφη a little boat or skiff; from σκαπτω to dig; because skiffs were formerly only trees made hollow.

SCAPHOIDĒS. *A bone of the carpus,* so called from its resemblance to a skiff; from σκαφη a skiff, and ειδος likeness.

SCLEROTIC. *A term applied to the outermost or hardest membrane of the eye;* from σκληροω to make hard.

SELLA TURCĬCA. Part of the sphænoid is so called from its supposed resemblance to a Turkish saddle.

SESAMOID *bones.* From σησαμη an Indian grain, and ειδος likeness; from their resemblance to the semen sesami.

SIGMOID. *Parts are so called from their resemblance to the letter* Σ: from Σ, the letter Sigma, and ειδος likeness.

SPHÆNOID. From σφην a wedge, and ειδος likeness; shaped like a wedge.

SPHINCTER. *The name of several muscles whose office it is to shut up the aperture around which they are placed;* from σφιγγω to shut up.

SPLANCHNOLOGY. *The doctrine of the viscera;* from σπλαγχνον an entrail, and λογος a treatise.

SYMPHȲSIS. *A connexion of bones;* from συμφυω to grow together.

SYNARTHRŌSIS. *A connexion of bones;* from συν with, and αρθρον a joint.

SYNCHONDRŌSIS. *A species of union of bones by means of cartilage;* from συν with, and χονδρος a cartilage.

SYNDESMOLOGY. *The doctrine of the ligaments;* from συνδεσμος a ligament, and λογος a treatise.

SYNDESMŌSIS. *A species of union of bones by means of ligament;* from συνδεσμος a ligament.

SYNEURŌSIS. *A species of connexion of bones by means of membrane;* from συν with, and νευρον a nerve; because mem-

branes, ligaments, and tendons, were by the ancients considered as nerves.

SYSSARCŌSIS. *A species of connexion of bones by means of muscle;* from συν with, and σαρξ flesh.

SYSTŎLE. *The contractile motion of the heart and arteries;* from συςελλω to contract.

T

TENDON. Ftom τεινω to extend.

THĒCA. The spinal canal is called *theca vertebralis;* from θηκη a repository; from τιθημι to put.

THORAX. Θωραξ. *The breast* or *chest;* from θορεω to leap; because in it the heart beats.

THYRO. Names compounded with this word belong to muscles which are attached to the thyroid cartilage.

THYROID. From θυρεος a shield, and ειδος likeness; shaped like a shield.

TRACHEA. *The windpipe,* so called from its roughness; from τραχυς rough.

TRAPEZOID. From τραπεζιον a four-sided figure, and ειδος likeness; resembling a trapezium.

TROCHANTER. *A process of the thigh-bone,* so called from τρεχω to run; because the muscles inserted in these parts perform the office of running.

TROCHLEA. *A kind of cartilaginous pulley,* through which the tendon of one of the muscles of the eye passes; from τρεχω to run.

TROCHOIDES. *A species of articulation of bones;* from τροχος a wheel, and ειδος likeness; because one bone moves round upon another, like a wheel upon an axle-tree.

U

ULNA. *A name for the cubit;* from ωλενη the cubit.

URETER. *The canal which conveys the urine from the kidney to the bladder;* from ερον urine.

URĒTHRA. *The passage through which the urine passes from the bladder;* from ερον the urine.

UVEA. *The posterior lamina of the iris;* so called because in beasts (which the ancients chiefly dissected) it is of the colour of unripe grapes; from *uva* an unripe grape.

UVULA. *The glandular substance which hangs down from the middle of the soft palate;* so called from its resemblance to a grape. A diminutive of *uva* a grape.

V

VALVES. *Little membranes that prevent the return of the blood in the veins and arteries;* from *valvæ* folding doors.

VERTEBRÆ. *The bones of the spine* are so called; from *verto* to turn.

VOMER. *A bone of the nose,* so called from its resemblance to a ploughshare; from *vomo* to turn up.

X

XIPHOID. So called from the *resemblance to a sword;* from ξιφος a sword, and ειδος likeness.

Z

ZYGŌMA. *The cavity under the zygomatic process of the temporal bone;* from ζυγος a yoke, because it transmits the tendon of the temporal muscle like a yoke.

INDEX.

A — Page

ABDOMEN — 275
Abdominal region — ib.
——— ring — 111
Abductor indicis manûs 136
——— longus pollicis manûs — ib.
——— minimi digiti manûs — 137
——— digiti pedis — 149
——— oculi — 96
——— pollicis manûs 136
——— pedis 149
Abscess — 154
Absorbents — 178
———, diseases of 182
Absorption, physiology of ib.
——— of bone 80
Accelerator urinæ — 112
Accessory nerve of Willis 192
Acetabulum — 51
Acini biliosi — 285
Acromion — 56
Action of arteries — 171
——— veins — 177
——— the cerebrum, cerebellum, medulla oblongata and spinalis 236
Additamentum ad sacro-lumbalem — 124
——— suturæ lambdoidalis — 9
——— suturæ squamosæ — ib.
——— ulnæ 60
Adducens oculi — 96

Page

Adductor brevis femoris 138
——— longus femoris ib.
——— magnus femoris ib.
——— minimi digiti manûs — 137
Adductor pollicis manûs 136
——— pedis 149
Adenology — 203
Adipose membrane 218
Air-vesicles — 264
Alæ majores — 20
——— minores — ib.
Almonds of the ear 208
Alveolar artery — 162
——— nerve, posterior 188
Alveoli — 27
Alveus communis — 244
Amnion — 286
Amphiarthrosis — 74
Ampulla — 244
Anatomical terms — 375
Anatomy — 1
———, comparative ib.
Anchyblepharum — 242
Anchylops — ib.
Anchylosis — 80
Ancle-joint — 72
Anconeus — 131
Anconoid process — 59
Aneurism, popliteal 169
———, varicose 174
Angina œdematosa 254
——— pectoris 161
Angiology — 160
Angular artery — 162
——— vein — 174

Page
Annulus osseus — 23
Anterior auris — 100
Antihelix — 243
Antithenar — 149
Antitragicus — 100
Antitragus — 243
Antrum of Highmore 27
——— maxillare ib.
———, perforation of 28
Aorta — 161
——— descendens — 166
Aphthæ — 253
Aponeurosis, plantar 150
Aphophysis — 5
Appendicula cæci vermiformis — 280
——— epiploicæ 280
Aqueduct of Sylvius 229
Aqueous humour — 241
Arachnoid membrane 221
Arbor vitæ — 232
Areola — 262
Arm — — 57
Arteria cerebri — 163
——— cervicalis — 165
——— circumflexa iliaca 169
——— comes phrenici 164
——— coronaria ventriculi — 167
——— communicans 164
——— dorsalis pollicis 166
——— ——— ulnaris ib.
——— duodena gastrica 167
——— hepatica — 167
——— innominata 161
——— intercostalis 165
——— labialis — 162
——— lingualis — ib.
——— maxillaris interna 162
——— magna pollicis 166
——— malleolaris 170
——— metatarsea 165
——— nutrita — ib.

Page
Arteria occipitalis 162
——— ophthalmica 163
——— palmaris profunda 166
——— pancreatica duodenalis — 167
——— phrenico-pericardiaca — 164
——— pharangia inferior 162
——— plantaris — 170
——— posterior auris 162
——— profunda femoris 169
——— ——— humeri 165
——— pulmonalis 170
——— pudica communis 168
——— pylorica inferior 167
——— ——— superior hepatica — ib.
——— radialis indicis 166
——— subscapularis 165
——— supra-scapularis ib.
——— splenica — 167
——— sublingualis 162
——— submentalis ib.
——— superficialis volæ 166
——— temporalis — 163
——— thoracica alaris 165
——— ——— thyroid 162
——— ——— humeriana — ib.
——— ——— longior ib.
——— ——— superior ib.
——— tibialis antica 169
——— ——— postica 170
——— tarsea — ib.
——— transversalis faciei 163
——— vertebralis — 164
Arterial system — 160
Arteries — ib.
———, action of — 171
———, diseases of ib.
Arthrodia — 74
Arytæno-epiglottideus 108
Arytænoid cartilage 257

Page
Arytænoideus obliquus 108
——— transversus ib.
Ascites abdominalis 275
Astragalus — 71
Atlas — 45
Attollens auris — 99
——— oculi — 96
Auditory nerves — 245
Auricles of the heart 270
Auricular vein — 174
Auricularis — ib.
Auris — 243
Axillary artery — 165
———- nerve — 193
———- vein — 174
Azygos uvulæ — 107

B

Barba — 218
Barbula — 245
Basilare os — 17
Basilary artery — 164
——— process — 18
Basilic vein — 173
Basio-glossus — 104
—— -chondro-cerato-glossus — ib.
Bibitorius — 96
Biceps cruris — 143
——— flexor cubiti 130
——— brachii ib.
Bile — — 324
Biventer cervicis — 125
——— maxillæ inferioris — 103
Blepharophthalmia 242
Blood — — 316
——, circulation of 273
Blood-vessel subject 338
Bones, colour of — 4, 73
——, composition of 4
——, doctrine of 3
——, diseases of 78

Page
Bones, growth o. 76
——, nerves of 73
——, processes of 5
——, substance of 3
——, table of — 6
——, vessels of — 73
Bone converted into chalk — 82
Bony fibre — 1
Brachial artery — 166
——— vein — 174
Brachialis internus 130
Brachio-cubital ligament 89
——— -radial ligament ib.
Breasts — 262
Brevissimus oculi — 97
Broad ligament — 284
Bronchiæ 260, 264
Bronchial glands — 208
Brunner's glands — 281
Bubo — 212
Bubonocele — 281
Buccinator — 98
Bursæ mucosæ — 155
———, diseases of 160
——— of the head — 155
——— about the shoulder-joint — ib.
——— situated near the elbow-joint 146
——— on the inside of the wrist and hand — 157
——— on the back part of the hand and wrist — ib.
——— near the hip-joint — 158
———
knee-joint — ib.
——— situated in the foot — 159

	Page
Bursalogy —	155

C

	Page
Cæcum —	280
Calamus scriptorius	233
Calcaneum —	71
Calvaria —	12
Canalis arteriosus	314
——— caroticus	11, 22
——— mentalis	32
——— nasalis —	27
——— venosus —	314
Canal of Petit —	241
—— semicircular	40
Cancelli —	3
Caninus —	97
Canna major —	59
—— minor —	60
Capilli —	217
Caput gallinaginis	295
Caries of bones —	81
——, honeycomb	12
Carneæ columnæ	270
Carotid artery —	161
——— canal —	11, 17
Carpus —	62
Cartilage —	82
Caruncula lachrymalis	206, 238
Carunculæ myrtiformes	303
Catamenia —	309
Cataract —	243
Catarrhus —	248
Cavitas innominata	243
Cauda equina —	225
Cellular membrane	1, 218
Centres of ossification	76
Centrum ovale —	225
——— tendinosum	115
Cephalic vein —	173
Cerato-glossus —	104
Cerebellum —	232
Cerebral artery —	163
Cerebral nerves —	185
Cerebrum —	223
Cerumen aurium —	295
Ceruminous glands	206
Cervicalis descendens	124
Cervical vertebræ	44
——— glands —	207
Chalk in bones —	82
Chamber of the eye	241
Chancre —	296
Cheeks —	249
Chondro-glossus —	104
Chorda tympani —	244
Chordæ Willisii —	220
Chorion —	286
Choroid membrane	226
Chyle —	324
Chylification —	282
Chymification —	278
Cilia —	217
Ciliary ligament —	240
Circulation of the blood	273
———— in the fœtus	314
Circumflexus palati	106
Clavicula —	54
Clavis —	ib.
Clinoid processes	10
Clitoris —	302
Coccygeus —	114
Cochlea —	40
Cœliac artery —	167
Cœliac plexus of nerves	198
Colic arteries —	167
Collateralis penis	112
Colon —	280
Colour of bones —	73
Columna anonyma	227
——— spinalis —	41
——— vertebralis	ib.
Commissura anterior cerebri —	224
——— inferior cerebri —	229

Page
Commissura superior cerebri — 224
———— magna cerebri — ib.
———— posterior cerebri — 229
Commissures — 223
Common integuments 215
Complexus — 125
———— major ib.
———— minor ib.
Compressor nasi 99
Conception, physiology of 309
Concha auris — 243
Conchæ inferiores 30
Conglomerate gland 204
Coni vasculosi — 297
Conjunctive membrane 239
Connexion of bones 74
Constrictor isthmi faucium 106
———— nasi — 99
———— oris — ib.
———— pharyngis inferior — 107
———— ———— medius — ib.
———— ———— superior — ib.
———— vel compressor alæ nasi — 99
Coraco-brachialis — 129
——— hyoideus — 105
Coracoid process — 56
Cordæ tendineæ — 270
Cornea opaca — 239
——— transparens ib.
Cornu ammonis — 227
Corona glandis — 295
Coronal suture — 9
Coronary artery of the lips 162
———— of the stomach — 167
Coronoid process — 56

Page
Corpora candidantia Willisii — 224
Corpora cavernosa penis 294
———- lutea 307, 308
———- olivaria — 234
———- quadrigemina 230
———- pyramidalia 234
———- sesamoidea 270
Corpus annulare — 234
——— callosum — 224
——— ciliare — 240
——— fimbriatum 226
——— mucosum — 216
——— pampiniforme 298
——— reticulare 216
——— spongiosum penis 294
——— striatum — 226
Corrugator supercilii 95
Costæ — 46
Cowper's glands — 211
Cranium, adult — 8
———, fœtal — 13
———, honeycomb caries of — 12
Crassamentum — 289
Cremaster — 112
Cribriform plate — 25
———— foraminula ib.
Crico-arytænoideus lateralis — 108
———— obliquus — ib.
———— posticus — ib.
—— thyroideus — 105
Cricoid cartilage — 257
Crista galli — 25
Crucial ligaments — 91
——— spine — 18
Cruor — 289
Crura cerebri — 224
Cruræus — 142
Crural artery — 169

Page
Crural nerve — 195
—— vein — 176
Cruralis — 142
Cryptæ — 289
Crystalline lens 241, 320
Cubital artery — 166
Cubitus — 59
Cuneiform process 11, 17
Cuspidatus — 36
Cutaneal nerves, brachial 193
Cuticula — 215
Cutis — 216
Cynanche maligna 251
—— œdematosa 254
—— parotidea 207
—— tonsillaris 254
—— trachealis 260
Cystic glands — 210

D

Dartos — 112
Decidua — 312
Deglutition, physiology of 255
Deltoides — 129
Dentata — 44
Dentatus — ib.
Dentes sapientiæ — 37
Deprimens oculi — 96
Depressor labii inferioris 98
—— anguli oris ib.
—— superioris et alæ nasi — ib.
Dermis — 216
Descent of the testicle 299
Diaphragma — 115
Diaphragmatic nerve 192
—— veins 176
Diaphragmitis — 116
Diarthrosis — 74
Diastasis of bones 80
Diastole — 275
Digastricus — 103
—— capitis 95

Page
Digestion — 278
Digital veins — 173
Digiti manûs — 64
Digiti pedis — 73
Dilator alæ nasi — 97
Diploe — 10
Diseases of the breast 262
—— pleura 264
—— lungs 265
—— pericardium — 268
—— heart 272
—— abdomen 275
—— peritonæum — 276
—— intestines 281
—— mesentery 283
—— liver 284
—— gall-bladder — 287
—— pancreas 288
—— lacteal vessels — 289
—— kidney 290
—— venal glands — 291
—— bladder 293
—— urethra 296
—— testicle 299
—— vesiculæ seminales — 301
—— female organs of generation 303
—— vagina 304
—— uterus 308
—— blood 316
Diseased appearances of bones — 78
—— of ligaments 93
—— of muscles 153
—— of the bursæ 160
—— of arteries 171
—— of veins 177

Page

Diseased appearances of absorbents — 182
———— of nerves 199
———— the dura mater — 221
———— the pia mater — 222
———— the tunica arachnoides — 222
———— the cerebrum — 234
———— the cerebellum — 233
———— the medulla oblongata — 235
———— the eye 242
———— the nose 248
———— the mouth 251
———— the tongue 252
———— the fauces 254
———— the œsophagus — 255
———— the larynx 258
———— the trachea 260
———— the thorax 261
Distichiasis — 242
Dorsal glands — 209
——— nerves — 194
——— vertebræ — 45
Duct, thoracic — 181
Ductus ad nasum — 27
——— communis 287
——— cysticus — ib.
——— hepaticus — ib.
——— pancreaticus 288
Duodenum — 279
Dura mater — 219
—— meninx — ib.

E

Ear — — 243
Ejaculator seminis — 112
Ejaculatory ducts — 301

Page

Elbow-joint — 61
Elementary fibre — 1
Eleutritis — 394
Empyema — 264
Emulgent artery — 167
Enarthrosis — 74
Encanthus — 222
Encephalon — 223
Enteric juice —282, 324
Enteritis — 281
Entropium — 242
Ephippium — 21
Epicranius — 95
Epidermis — 215
Epididymis — 297
Epigastric artery — 168
———— region — 214
Epiglottis — 257
Epiphysis — 5
Epiplocele — 277
Epiploic glands — 210
Epiploitis — 277
Epiploon — 276
Epistropheus — 45
Epithelium — 215
Epulis — 242
Erector clitoridis — 114
——— penis — 112
Ethmoidal harmony 16
Eustachian tube — 23
———— valve — 269
Excretion of the urine 290
Exfoliation — 3
Exostosis — 80
Expiration — 266
Expulsion of the fæces 282
Extensor brevis cubiti 130
———— digitorum pedis — 148
———— carpi radialis longior — 131
———— brevior — ib.

Page

Extensor carpi ulnaris 132
—— digitorum communis — 132
—— indicis proprius 134
—— longus cubiti 130
—— —— digitorum pedis — 146
—— major pollicis manûs — 134
—— tertius pollicis ib.
—— minimi digiti manûs — 132
—— minor pollicis manûs — 134
—— pollicis primus ib.
—— secundi internodii — ib.
—— secundus pollicis ib.
—— ossis metacarpi pollicis manûs — 133
—— primi internodii 134
—— primus pollicis 133
—— proprius pollicis pedis — 147
—— tarsi minor 144
—— —— suralis ib.
Eye — 237
Eyelids — ib.

F

Facial artery — 161
—— nerve — 189
Fæces, expulsion of 282
Falciform process — 219
Fallopian hiatus — 24
—— tubes — 306
Falx — 219
Fascia — 137
—— of the thigh ib.
Fascialis — 141
Fauces —260, 263
——, bony — 37
Femoral artery — 169

Page

Femoral vein — 176
Femur — 65
Fenestra ovalis — 39
—— rotunda — ib.
Fibre, elementary — 1
Fibula — 68
Fifth ventricle — 225
Fingers — 64
Finger-joints — ib.
Fissura magna cerebelli 232
—— cerebri 224
Fissures — 81
Flexor brevis digitorum pedis — 148
—— minimi digiti pedis — 149
—— pollicis manûs — 136
—— —— pedis 148
—— carpi radialis 133
—— carpi ulnaris 132
—— digitorum accessorius — 147
—— —— profundus — 135
—— —— sublimis 134
—— longus digitorum pedis — 147
—— —— pollicis 135
—— —— pollicis pedis — 147
—— parvus minimi digiti — 137
—— perforans pedis 147
—— perforatus pedis ib.
—— profundus pedis ib.
—— sublimis pedis 148
Fluids, doctrine of 315
—— in the cavity of the cranium — 318
—— —— nostrils 319
—— —— mouth 320
—— —— fauces ib.

Page
Fluids of the eyes 320
——— in the cavity of the ears — 322
——— of the neck ib.
——— in the cavity of the thorax — 323
——————— abdomen 324
——— in the parts of generation in men 325
——————— in women 326
——— in the articulations 327
——————— bones ib.
——— of the common integuments — 328
Focile majus — 59
Fœtus — 313
Follicle — 203
Folliculose gland — ib.
Fons pulsatilis — 13
Fontanel — ib.
Foot — 70
Foramen, anterior orbitar 15
——— cæcum 10, 15
——— condyloideum anterius — 12
——— incisivum 27
——— lacerum in basi cranii — 11, 19
——————— orbitale superius — 21, 10
——— magnum occipitale — 11, 18
——— of Monro 227
——— of Winslow 277
——— opticum 10, 20
——— ovale 11, 20, 269
——— parietale 17
——— posterior orbitar 15
——— rotundum 11, 20
——— spinosum ib.
——— stylo-mastoideum — 22
——— superciliare 15

Page
Foramen thyroideum 51
Foramina cribrosa 10
——— maxillaria 32
——— orbitalia nasi 24
——— palatina 26
——— Thebesii 269
Fore-arm — 59
Fornix — 227
Fossa jugalis — 23
Fractures — 81
Fragility of bones 82
Frenulum — 294
Frenum — ib.
Frontal bone — 14
——— eminences ib.
——— nerve — 187
——— sinuses — 14
——— spine — ib.
——— tuberosities ib.
——— vein — 174
Frontis os — 14
Funiculus umbilicalis 312
Funis — ib.
Furcula — 54
Furfura — 216
Furuncle — 204

G

Galactoferous ducts 262
Gall-bladder — 286
Ganglion of nerves 185
Gastric arteries — 167
——— glands — 209
——— juice — 324
Gastritis — 278
Gastrocele — ib.
Gastrocnemius externus 144
——————— internus ib.
Gastroraphe — 276
Gelatin — 3
Gemelli — 140
Gemini — ib.

	Page
Generation, female organs of —	301
———, male organs of —	297
Genio-glossus —	104
——-hyoides —	ib.
Ginglymus —	74
Glands, doctrine of	203
—— of the skin —	204
—— in the cavity of the cranium —	ib.
—— eyes —	205
—— nostrils	206
—— ear —	ib.
—— mouth	ib.
—— neck	207
—— fauces	208
—— breast	ib.
—— thorax	ib.
—— abdomen	209
—— loins	210
—— organs of generation in man	210
—— female organs of generation	211
—— extremities	212
—— joints	ib.
Glans penis —	295
Glaucoma —	242
Glenoid cavity —	57
Globate gland —	203
Glomer —	ib.
Glomerate gland —	ib.
GLOSSARY —	375
Glossitis —	258
Gluteal arteries —	167
Gluten —	2
Gluteus magnus —	139
——- major —	ib.
——- maximus —	ib.
——- medius —	ib.
——- minimus —	140
——- minor —	ib.

	Page
Gomphosis —	75
Gonorrhœa —	296
Gracilis —	141
——- anterior —	ib.
——- internus —	ib.
Growth of bones —	76
Gubernaculum testis	299
Gummi —	81
Gums —	249
Gyri —	224

H

	Page
Hæmatocele —	299
Hæmorrhoidal artery	168
Hæmorrhois —	281
Hairs —	217
Hamular process —	22
Hand —	61
Harmonia ethmoidalis	16
——- sphænoidalis	ib.
Harmony —	75
Harvey, life of —	xix
Head —	8
—- of the Algerine	ib.
——- Asiatic negro	ib.
——- Chinese	ib.
——- European	ib.
——- Tartar	ib.
——- Turk —	ib.
Hearing, bony cavity of	38
——-, physiology of	245
Heart, adult —	268
Helicis major —	100
—— minor —	ib.
Helix —	243
Hepar —	260
Hepatic artery —	285
——- glands —	209
——- plexus of nerves	198
Hepatitis —	286
Hernia —	101
—— humoralis —	299
—— strangulated	101

	Page
Hiatus Fallopii —	24
Highmore, antrum of	27
Hip joint —	66
Hippocampus major	227
———— minor	226
Honeycomb caries of the cranium —	13
Hordeolum —	242
Hyaloid membrane	240
Hydrocele —	299
Hydrocephalus externus et internus —	319
Hydrocordis —	268
Hydrorachitis —	44
Hydrothorax —	264
Hygrology —	315
Hymen —	302
Hyo-glossus —	104
—— -thyroideus —	105
Hyoides os —	38
Hyperostosis —	79
Hypochondriac region	214
Hypogala —	242
Hypogastric artery	153
———— plexus of nerves	198
———— region	214
Hypopium —	242

I

Iliac artery, external	169
————, internal	167
—— glands —	210
—— vein, external	176
————, internal	ib.
Iliacus externus —	140
——— internus —	118
Ilium —	279
Incisivus inferior —	97
——— medius —	ib.
Incisores —	35
Incus —	244
Indicator —	134
Indignabundus —	96

	Page
Inferior extremities	65
——— maxillary nerve	188
Inflammation of bones	7?
Infra-orbital arteries	163
———— canal —	27
———— nerve —	188
Infra-spinatus —	128
Inguinal glands —	212
Injected gravid uterus	343
——— placenta —	345
——— heart —	346
——— fœtus —	ib.
——— penis —	348
——— testicle —	349
——— arm —	348
——— head —	34?
——— lower extremity	348
Injecting instruments	333
Injections, coarse —	334
————, fine —	335
————, minute —	ib.
Inspiration —	266
Instruments for injecting	306
Integuments, common	215
Interarticular cartilages	82
Intercostal vein —	175
———— nerve, great	196
Intercostales externi	119
———— interni	ib.
Intergyral spaces —	224
Internal maxillary artery	162
Interossei manûs externi	137
———— interni	ib.
Interossei pedis externi	150
———— interni	ib.
Interspinales —	127
———— colli —	ib.
———— dorsi —	ib.
———— lumborum	ib.
Intertransversales	ib.
Intervertebral substance	43
Intestinal glands —	209
Intestines —	279

	Page
Introduction —	vii
Iris —	239
Irritability —	152
Ischiatic artery —	168
———— nerve —	195
———— notch —	49
Ischio-cavernosus —	112
Iter ad infundibulum	229
—— à tertio ad quartum ventriculum —	229

J

Jejunum —	279
Joints, preternatural	80
Joints of the vertebræ	44
———— ribs —	48
———— shoulder	56
———— elbow —	61
———— wrist —	63
———— fingers—	64
———— hip —	66
———— knee —	69
———— ancle —	72
———— toes —	73
Jugal fossa —	22
Jugular glands —	207
———— vein, internal	175

K

Kidney —	289
Knee-joint —	69

L

Labia cerebri —	225
—— majora —	302
—— minora —	ib.
Labial glands —	207
Labyrinth —	244
Lachrymal caruncle	283
———— depression	27
———— gland 205,	238
———— nerve —	187
———— sac —	238

	Page
Lacteal glands —	209
Lacteals —	179, 288
Lactiferous ducts —	241
Lacunæ —	294
Lambdoidal suture	9
Lamina —	1
Layer —	ib.
Laryngitis —	257
Larynx —	256
Lateral sinuses —	220
———— ventricles —	225
Latissimus colli —	120
———— dorsi —	121
Laxator tympani —	101
Leg — —	67
Leucorrhœa —	296
Levator anguli oris	97
———— ani —	113
———— labii inferioris	97
———— superioris alæque nasi —	ib.
———— superioris proprius —	ib.
———— labiorum communis —	ib.
———— menti —	99
———— oculi —	96
———— palati mollis	106
———— palpebræ superioris —	95
———— proprius angularis	125
———— scapulæ —	ib.
Levatores costarum	124
———— longiores	ib.
Ligament —	1
————, brachio-cubital	89
———— radial	ib.
————, Poupart's	87
Ligaments —	84
———— sacro-sciatic	87
Ligamentum ciliare	240
———— conoideum	88
———— deltoideum	ib.

Page
Ligamentum denticulatum — 236
——— inguinale 87
——— obturans ib.
——— pectinatum 294
——— rhomboideum 88
——— serratum 236
——— teres — 90
Light — 201
Ligula — 54
Linea alba — 111
——- innominata — 51
——- semilunaris — 111
Lingual nerve, internal 188
——— nerves — 191
Lingualis — 104
Liquor amnii — 313
——— pericardii — 3, 296
Lips — 250
Liver — 284
Lobulus Spigelii — ib.
——— caudatus anonymus — ib.
Loins — 49
Longissimus dorsi — 124
Longitudinal sinus — 220
Longus colli — 120
Lumbar arteries — 167
——— vertebræ — 45
——— glands — 210
——— nerves — 195
Lumbricalis manûs 136
——— pedis — 148
Lungs — 264
Lymph — 318
Lymphatics — 179
——— of the head and neck — ib.
——— upper extremities — ib.
——— inferior extremities — 180

Page
Lymphatics of the abdominal and thoracic viscera — 181
Lyra — 228

M

Malacosteon — 79
Malleus — 244
Mamillæ — 262
Mamillary artery, internal — 162
——— process — 24
Mammæ 262
Mammary artery, external — 150
——— glands — 208
——— vein, internal 174
Mandibula — 31
Manubrium manûs — 60
Marrow — 327
Marsupialis — 140
Massa carnea Jacobi Sylvii — 147
Masseter — 102
Mastication, physiology of — 251
Mastitis — 262
Mastodynia — ib.
Mastoid process — 23
Mastoideus — 103
——— lateralis 125
Maxillary artery, internal 162
——— lower ib.
——— foramina — 32
——— glands — 207
——— nerve, superior 187
———, inferior 188
——— vein, external 175
Meatus auditorius externus — 248
——— internus — 11, 23

Page

Meatus urinarius — 302
Median nerve — 193
Mediastinal vein — 174
Mediastinum — 264
Meditullium — 10
Medulla oblongata— 233
——— spinalis — 235
Meibomius's glands 205
Membrana adiposa 218
————— medullaris 84
————— arachnoidea 221
————— cellulosa 218
————— choroides 139
————— conjunctiva ib.
————— decidua 312
————— pupillaris 240
————— mucosa 314
————— sclerotica 239
Membrane — 1
Membranous ovum of the fœtus — 312
————— semicircular canals — 244
Membrum virile — 293
Memoriæ os — 17
Menses — 309
Menstruation, physiology of — 309
Mesenteric artery, superior — 167
—————, inferior — ib.
————— glands 209
Mesenteric plexus of nerves — 198
—————, inferior ib.
—————, posterior ib.
—————, superior ib.
Mesenteritis — 283
Mesentery — ib.
Mesochondriac muscles 259
Mesocola — 280
Mesocolic plexus of nerves 198
Mesocolon — 283

Page

Mesorectum — 283
Metacarpus — 63
Metatarsus — 72
Milk — 324
Milk teeth — 37
Modiolus — 38
Molar glands — 207
Molares — 36
Mollities ossium — 79
Mons Veneris — 301
Monsters, calvaria wanting in — 12
Morbid thickness of bones 79
——— thinness of bones ib.
Motion, muscular, physiology of — 150
Mould of the head — 13
Mouth 35, 228
Mucus Malpighianus 197
Multifidus spinæ 126
Muscles, disease of 153
——— situated about the glottis — 103
————— about the anterior part of the abdomen — 109
——— of the female organs of generation 114
——— situated within the pelvis —
————— within the cavity of the abdomen 115
————— on the anterior part of the thorax — 118
————— between the ribs and within the thorax — 119
————— on the anterior part of the neck 120
————— on the posterior part of the trunk 121
——— of the superior extremity — 128

Page

Muscles of the integuments of the cranium 95
—— of the eye-lids ib.
—— eye-ball 96
—— nose and mouth — 97
—— external ear — 99
—— internal ear — 101
—— lower jaw ib.
—— which appear about the anterior part of the neck — 102
—— situated between the lower jaw and os hyoides — 103
——between the os hyoides and trunk — 104
——between the lower jaw and os hyoides laterally 105
—— about the entry of the fauces 106
—— on the superior part of the pharynx — 107
—— on the os brachii — 130
—— fore-arm 131
—— chiefly on the hand — 136
—— of the inferior extremities — 137
—— situated on the thigh — 141
—— on the leg 144
—— chiefly on the foot — 148
Muscular motion, physiology of — 150

Page

Musculi accessorii ad sacro-lumbalem — 124
—— fidicinales — 136
—— pectinati — 269
Musculus ani latus — 113
—— cutaneus — 102
—— fasciæ latæ 141
—— incisivus 97
—— patientiæ 125
—— perforans Casserii — 129
—— polychrestus 104
—— tubæ — 106
Mylo-hyoideus — 103
Myology — 95
Myops — 242
Mystax — 217

N

Nails — 217
Nasal arteries — 162
—— nerve — 187
Nasalis labii superioris 99
Neck — 260
Necrosis — 79
Nerves, cervical — 191
—— of the brain 185
——, diseases of 199
——, doctrine of 184
——, dorsal — 194
——, upper extremities 198
——, lumbar — 195
——, occipital — 191
——, physiology of 199
——, sacral — 195
——, spinal — 191
Nervi abducentes — 188
—— auditorii — 189
—— linguales — 191
—— oculorum motorii 186
—— pathetici — 187
—— trigemini — ib.

Page
Nervous system, functions of — 199
Nervosum os — 17
Nerves of bones — 73
Neurology — 184
Nonus Vesalii — 146
Nose — 246
Nostrils — 34
Nymphæ — 302

O

Obducent cartilages 82
Obliquus capitis inferior 127
———— superior ib.
——— externus — 109
——— descendens ib.
——— internus — ib.
——— major descendens ib.
——— inferior oculi 97
——— superior oculi 96
Obturator externus 139
——— internus — 140
——— nerve — 195
Obturatory artery — 168
Occipital artery — 162
——— bone — 17
——— nerve — 191
——— suture — 9
——— tubercle — 17
——— vein — 174
Occipitalis et frontalis 95
Occipito-frontalis — ib.
——— sphænoidal bone 19
Oculorum motorii — 186
Oculus — 237
Odoriferous glands — 210
Œsophageal glands 209
Œsophagitis — 255
Œsophagotomy — ib.
Œsophagus — ib.
Œstrum venereum — 300
Olecranon — 59

Page
Olfactory nerves — 185
Omentitis — 277
Omentum — 276
Omo-hyoideus — 105
Omoplata — 55
Onyx — 242
Operations on the eye 243
———— mouth 249
———— nose ib.
———— tongue 260
———— fauces 254
———— œsophagus — 255
———— larynx 258
———— trachea 260
———— thorax 261
———— breast 262
———— pleura 264
———— abdomen 276
———— peritonæum — ib.
———— omentum — 277
———— intestines — 281
———— bladder 293
———— penis 296
———— urethra ib.
———— female organs of generation 303
———— vagina 304
———— uterus 308
Ophthalmia — 242
Oponeneus pollicis 136
Ophthalmic artery — 163
Ophtalmoptosis — 242
Optic nerves — 186
Orbicularis oris — 99
———— palpebrarum 95
Orbitar foramina — 15
——— plates — 14
Orbital nerve — 187

	Page
Orbits —	34
Orchitis —	299
Organs of generation, male —	293
————, female	301
Os alæforme —	20
— basillare —	17
— brachiale —	58
— brachii —	ib.
— calcis —	71
— clunium —	52
— coccygis —	53
— cribriforme —	25
— cribrosum —	ib.
— cuboides —	71
— cuneiforme —	20, 71
— ethmoidale —	25
— ethmoideum —	ib.
— externum —	305
— femoris —	65
— frontis —	14
— humeri —	58
— hyoides —	38
— internum —	305
— jugale —	54
— latum —	ib.
— linguale —	38
— lunare —	62, 71
— magnum —	ib.
— maxillare inferius	31
— memoriæ —	17
— multiforme —	20
— naviculare —	62, 71
— nervosum —	17
— occipitis —	ib.
— occipito-sphænoideum	18
— orbiculare —	62, 244
— pectoris —	48
— petrosum —	22
— polymorphon —	19
— pterygoideum —	ib.
— sacrum —	52

	Page
Os scaphoides —	62, 71
— sphænoidale —	20
— sphænoideum —	ib.
— subrotundum —	62
— tincæ —	305
— trapezium —	62
— trapezoides —	ib.
— unciforme —	ib.
— uteri —	305
— vespiforme —	20
— vespertiliforme —	ib.
Osculator —	99
Opponens pollicis —	136
Orbital nerve —	188
Orbitar plates —	25
Ossa innominata —	50
—— anonyma —	25
—— bregmatis —	16
—— coxarum —	50
—— coxendicis —	ib.
—— cuneiformia —	62
—— ilii —	50
—— ischii —	ib.
—— jugalia —	28
—— lachrymalia —	29
—— malarum —	28
—— maxillaria superiora	26
—— nasalia —	29
—— nasi —	ib.
—— parietalia —	16
—— plana —	25
———— superiora	ib.
—— palati —	30
—— palatina —	ib.
—— sesamoidea —	73
—— sincipitis —	16
—— spongiosa inferiora	30
—— temporalia —	22
—— temporum —	ib.
—— turbinata inferiora	30
—— unguis —	29
—— verticalia —	16

	Page
Ossa verticis —	16
—— zygomatica —	28
Ossicula auditûs —	38
——— triangularia	9
——— triquetra —	ib.
——— Wormiana	ib.
Ossification —	76
————, centre of	10
Osteogeny —	76
Osteology —	3
Ovaria —	312
Ovula Graafiana —	ib.
Ovum of the fœtus	212
Ozena —	248
P	
Pacchionian glands	204
Palate —	250
Palatine foramen —	27
Palato-pharyngeus —	107
——— salpingus —	106
Palmaris brevis —	137
——— cutaneus —	ib.
——— longus —	133
Palpebræ —	237
Pancreas —	288
Pancreatic duct —	ib.
———— glands —	210
———— juice —	324
Papilla 216. 252.	262
Papillæ of the tongue	252
Par vagum —	189
Paraphrenitis —	116
Parathenar minor —	149
Parietal bones —	16
——— foramen —	ib.
Parotid glands —	206
Parotis —	207
Patella —	69
Pectineus —	138
Pectinalis —	ib.
Pectoralis major —	118

	Page
Pectoralis minor —	118
Pelvis —	49
——, female —	50
——, male —	ib.
Penicilli —	285
Penis —	293
Perforans —	135
Perforatus —	134
Pericardiac veins —	174
Pericardium —	267
Pericranium —	83
Perichondrium —	ib.
Peridesmium —	ib.
Perineal artery —	168
Perineum —	214
Periorbita —	83
Periosteum —	ib.
Peroneal nerve —	196
———— vein —	175
Peritoneum —	276
Peritonitis —	ib.
Peroneus anticus —	146
———— brevis —	ib.
———— longus —	145
———— maximus	ib.
———— medius —	146
———— posterior	145
———— posticus —	ib.
———— primus —	ib.
———— secundus	146
———— tertius —	ib.
Perspiration, insensible	217
————, physiology of —	ib.
————, sensible	ib.
Pes anserinus —	189
—— hippocampi major	227
———————— minor	226
Petro-salpingo staphilinus	105
Petrosum os —	22
Pharyngeal artery —	164
Pharynx —	254

Page
Phlyctenæ — 242
Phrenic nerve — 192
Phthisical teeth — 36
Phyma — 204
Pia mater — 222
—— meninx — ib.
Pigment of the iris 240. 321
Pili — 217
—— auriculares — ib.
Pineal gland — 229
Pituitary gland — 205
——— membrane 248
Placenta — 311
Plana papyracea — 25
Plantar aponeurosis 150
Plantaris — 144
Plantysma myoides 102
Pleura — 263
Pleuritis — 264
Plexus choroides — 226
——— of Haller — 233
——— nerves, brachial 193
———, cœliac 198
———, hepatic ib.
———, hypogastric — ib.
———, inferior mesenteric — ib.
———, mesocolic ib.
———, œsophageal — 190
———, posterior mesenteric — ib.
———, pulmonic ib.
———, renal 198
———, solar ib.
———, spermatic — 199
———, splenic 198
———, stomachic — 190
———, superior mesenteric — 198

Page
Plica lunaris — 233
Pomum Adami — 214
Pons Tarinii — 224
—— Varolii — 234
Popliteal aneurism 141
——— artery — 169
——— nerve — 196
Popliteus — 144
Pori biliarii — 285
Portio dura — 189
——— mollis — ib.
Posterior auris — 100
Poupart's ligament 109
Preparations, corroded 360
———, macerated 331
———, morbid ib.
———, natural 330
———, made with coarse injection 337
———, with minute injection — 352
———, quicksilver 356
Prepuce — 294
Presbyops — 242
Preternatural joints 80
Primary teeth — 35
Principles of the body 1
Process, mamillary 23
Process, mastoid — ib.
———, styloid — ib.
———, vaginal — ib.
———, zygomatic 2 2
Processes, basilary 11
———, clinoid — 10
———, cuneiform 11
———, how named 4
Pronator radii quadratus 135
——— teres 133
Prostate gland — 211
Psalterium — 228
Psoas abscess — 117
—— magnus — ib.
—— parvus — ib.

Page

Pterygoideus externus — 102
—— internus ib.
—— major ib.
—— minor ib.
Pterygo-staphilinus 106
Pterygoid artery — 162
Pubis os — 50
Pudical arteries — 168
Pulmonary artery — 170
—— vesicles 264
Pulmonic plexus of nerves 190
Pulmonitis — 265
Puncta ciliaria — 205
Pupil — 240
Pylorus — 277
Pyramidalis — 110
Pyriformis — 141

Q

Quadratus femoris 141
—— genæ — 98
—— lumborum 116
Questions, Anatomical, &c. — 364
Quicksilver tray — 329

R

Rachitis — 79
Radius — 60
Radial nerve — 194
Ranula — 253
Raphe — 224
Rectum — 280
Rectus abdominis — 110
—— capitis lateralis 120
—— capitis posticus major — 126
—— posticus minor — ib.
—— cruris — 142
—— externus oculi 96
—— femoris — 142
—— inferior oculi 96

Page

Rectus internus capitis major — 120
—— capitis minor — ib.
—— femoris 142
—— oculi 96
—— superior oculi 96
Recurrent nerve, left 190
——, right ib.
Regions, abdominal 214
Renal artery — 167
—— capsules — 291
—— glands — ib.
—— plexus of nerves 198
Respiration — 266
Rete Malpighianum 216
—— mucosum — ib.
—— vasculosum testis 297
Reticular membrane 218
Retina — 240
Retrahens auris — 100
Rhomboideus — 122
—— major ib.
—— minor ib.
Rhyas — 242
Ribs — 46
——, spurious — ib.
——, true — ib.
Ring, abdominal — 109
Ringlike bone — 24
Rotula — 69
Round ligaments — 284

S

Saccus lachrymalis 238
Sacral arteries — 167
—— nerves — 195
Sacro-lumbalis — 124
——sciatic ligament 87
Sagittal suture — 9
Saliva — 330
Salpingo-pharyngeus 106
—— staphilinus ib.

	Page
Sanguification —	183
Sarcostosis —	81
Sartorius —	141
Scala cochleæ —	39
—— tympani —	ib.
—— vestibuli —	ib.
Scalenus primus —	127
———— secundus	ib.
Scapula —	35
Scapha —	243
Scarf-skin —	215
Schneider's membrane	248
Sclerotic membrane	239
Scoptula —	55
Scrobiculus cordis	214
Scrotum —	298
Scutiform cartilages	257
Secretion, physiology of	212
Seeing, physiology of	201
Sella turcica —	20
Semen —	326
———, excretion of	300
Semicircular canals, membranous —	244
Semilunar ganglion	198
Semimembranosus	143
Seminervosus —	ib.
Semiorbicularis superior and inferior —	99
Semispinalis colli —	126
———— dorsi —	125
———— internus	ib.
———— pars interna	ib.
Semitendinosus —	143
Sensation —	200
Senses, external —	ib.
———, internal —	ib.
Sensorium commune	223
Septum cerebelli —	220
——— cerebri —	219
——— lucidum —	225
——— transversum	220
——— auricularum	271

	Page
Septum ventriculorum	271
——— ethmoidale	25
——— transversum	115
Serratus major anticus	119
——— minor anticus	ib.
——— posticus inferior	122
——— superior posticus	123
Serum —	316
Shedding teeth —	37
Shoulder —	54
Sinus, lateral —	220
——, longitudinal	ib.
Sinuses, frontal pituitary	15
———, maxillary pituitary	27
Skeleton, artificial	6
———, natural	ib.
Skin, false —	216
——, true —	215
Smelling —	200
Solar plexus —	198
Soleus —	144
Sound —	245
Speech —	258
Spermatic artery	298
———— cord —	298
———— plexus of nerves	198
Sphæno-palatine nerve	187
———salpingo-staphilinus —	106
——— staphilinus	ib.
Sphænoidal harmony	16
———— spine	20
Sphincter ani —	113
———— oris —	99
———— vaginæ	114
Spigelian lobe —	285
Spina bifida —	46
—— dorsi —	41
—— ventosa —	82
Spinal lamina —	42
——— nerves —	194
Spinalis cervicis —	126
——— dorsi —	123

	Page
Spine —	41
Spinous artery —	162
Spiral nerve —	194
Splanchnology —	213
Splanchnic nerve —	197
Spleen —	287
Splenic vein —	198
——— artery —	288
——— plexus of nerves	198
Splenius —	123
——— capitis —	ib.
——— colli —	ib.
Spurious suture —	9
Squamous suture —	ib.
Stapedius —	101
Stapes —	39
Staphilinus externus	106
Staphyloma —	242
Steno's duct —	206
Sterno-cleido-mastoideus	103
———costalis —	119
———hyoideus —	104
———mastoideus —	102
———thyroideus —	105
Sternum —	48
Stomacace —	250
Stomach —	278
Stomachic plexuses	190
Stylo-glossus —	105
——-hyoideus —	ib.
——————— alter	ib.
——-mastoid foramen	23
——-pharyngeus —	106
Styloid process —	22, 56
Subaxillary glands	207
Subclavian artery	161. 164
————-- vein —	174
Subclavanis —	118
Subclavius —	ib.
Subcruræi —	143
Subcutaneous glands	204
Sublingual glands —	207
————- vein —	174
Submaxillary glands	207. 212
Subpopliteal vein —	175
Subscapularis —	129
Substance, intervertebral	48
Substantia medullaris	223
————- corticalis	ib.
————- cerebri —	ib.
Superbus —	96
Supercilia —	217. 237
Superciliary arches	14
———— foramen	16
———— ridges	15
Superior auris —	99
———— extremities	53
———— maxillary nerve	187
Supinator radii brevis	133
————— longus	131
Suppuration of bone	78
Supra-costalis —	124
———renal glands	210
Supraspinatus —	128
Suspensory ligament	284
Suture —	75
———, transverse	15. 26
Sutures of the cranium	ib.
———, coronal —	9
———, obliteration of	ib.
———, occipital —	ib.
———, sagittal —	ib.
———, spurious —	ib.
———, squamous —	ib.
———, true —	ib.
Sweat —	217
Symblepharom —	242
Sympathetic nerve, great	196
Symphysis —	75
Synarthrosis —	ib.
Synchondrosis —	ib.
Syndesmology —	84
Syndesmosis —	75
Syneurosis —	ib.
Synezesis —	242
Synostosis —	75

Page

Synovia — 327
Synovial glands — 212
Syssarcosis — 75
Systole — 275

T

Table of bones — 6
Tænia semicircularis 226
Tarsus — 70
Tasting, physiology of 202
Tears — 321
Temporal arteries 163
——— vein — 174
Temporalis — 101
Teeth — 35
———, milk — 37
———, primary — ib.
———, shedding — ib.
Tendon — 85
Tensor palati — 106
——— tympani — 101
——— vaginæ femoris 141
Tentorium — 220
Teres major — 128
—— minor — ib.
Testicle — 297
Testis — ib.
Thalamus nervi optici 226
Thebesian foramina 269
Theca vertebralis — 41
Thickness of bones 79
Thinness of bones — ib.
Thigh — 65
Thoracic duct — 181
——— aorta — 166
Thorax — 46. 261
Thrombus — 158
Thymus glands — 208
Thyreo-arytænoideus 107
———-epiglottideus 108
———-hyoideus — 104
Thyroid artery — 162
————, ascending 164

Page

Thyroid artery, inferior 164
——— cartilage 257
——— gland — 207
Tibia — 67
Tibial nerve — 196
—— vein, anterior 175
————, posterior 175
Tibialis anticus — 145
——— gracilis — 144
——— posticus — 145
Tic douloureux — 188
Toes, joints of — 73
Tomentum cerebri 222
Tongue — 252
Tonsils — 208
Tophus — 81
Torcular Herophili 220
Touching, physiology of 202
Trabeculæ — 220
Trachea — 259
Tracheal arteries — 164
Trachelo-mastoideus 125
Tragicus — 100
Tragus — 243
Transversalis abdominis 110
———— colli 125
———— dorsi ib.
———— lumborum, vulgo sacer — ib.
———— pedis 149
———— penis 113
———— perinæi ib.
———— perinæi alter — ib.
Transverse suture 16. 27
Transverso-spinalis colli 126
———— colli pars interna — ib.
———— dorsi 125
Transversus auris — 100
Trapezius — 121
Trepanning, where performed — 12

	Page
Triangularia ossicula	9
Triangularis labiorum	98
——— sterni —	119
Triceps adductor femoris	138
——— extensor cubiti	130
Tricorn cavity —	225
Tricuspid valve —	270
Trigemini —	187
Trigeminus —	125
Triglochin valve —	270
Triquetra ossicula —	9
Trochanters —	65
Trochlearis —	96
Trochoides —	74
Trunk —	41
Tube, Eustachian —	24
Tubercle, occipital	17
Tuberculum Loweri	269
Tuberosity of the ischium	51
Tubuli galactoferi	208
——— lactiferi —	ib.
——— uriniferi —	290
Tunica albuginea testis	298
——— arachnoides	221
——— conjunctiva	239
——— sclerotica	ib.
——— choroidea —	ib.
——— vaginalis testis	298
Tympanum —	244

U

Ulna —	59
Ulnar arteries —	166
——— nerve —	193
Umbilical cord —	312
——— region —	214
Umbilicus —	111
Ungues —	217
Unguis —	226
Uniting cartilages	77
Urachus —	292
Urine —	290. 325
———, excretion of —	290

	Page
Uterine placenta —	311
Uterus —	305
———, gravid —	311
Uvea —	240
Uvula —	250

V

Vagina —	303
Vaginal process —	23
Valve of Eustachius	269
Valvula magna cerebri	233
——— Tulpii —	280
——— semilunaris	238
Valvulæ conniventes	280
——— mitrales —	271
Varicocele —	300
Varicose aneurism	174
Vas deferens —	297
Vasa brevia —	176
——— efferentia —	297
——— præparantia —	298
——— recta —	297
Vastus externus —	142
——— internus —	ib.
Veins —	172
———, action of —	171
———, diseases of —	ib.
Velum interpositum	228
——— pendulum palati	250
Vena azygos —	175
——— basilica —	173
——— cephalica —	ib.
——— cava ascendens	172
——— hepatica	176
——— inferior	175
——— superior	172
——— dorsalis pedis	175
——— mediana —	173
——— portæ	177. 183
——— salvatella —	173
——— saphena —	173
Venal system —	172

	Page
Ventricles	
———, fifth —	225
———, fourth —	232
———, lateral —	225
———, third —	228
———, tricorn	225
——— of the heart	269
Ventriloquism —	259
Vermiform processes	232
Vertebræ —	41, 44, 45
———, cervical —	44
———, dorsal —	45
———, false —	42
———, joints of	44
———, lumbar —	45
———, true —	42
Vertebral arteries —	164
Verumontanum —	295
Vesalius, life of —	xiv
Vesica fellis —	286
——— urinaria —	292
Vesiculæ pulmonales	264
——— seminales —	301
Vessels, doctrine of	160
——— of bones —	73
Vestibulum —	39
Vibrissæ —	217
Viduan canal —	22
Vis elastica —	152
— insita —	ib.
— mortua —	ib.
— tonica —	ib.
Viscera, doctrine of	213
Viscus —	1
Vitreous humour	240. 321
Voice, physiology of	258
Vomer —	31
Vomicæ —	265

W

Wormiana ossicula	9
Water of the labyrinth	ib.
Wax of the ears —	322
Worms —	281

X

Xiphoid cartilage	49

Z

Zona mollis —	245
Zootomy —	1
Zygoma —	22
Zygomatic process	ib.
Zygomaticus major	98
——— minor	ib.

THE END.

MEDICAL BOOKS

LATELY PUBLISHED

BY JOHN MURRAY, 32, FLEET-STREET, LONDON;

AND SOLD ALSO BY EVERY OTHER BOOKSELLER IN TOWN AND COUNTRY.

1. ANATOMICAL PLATES of the THORACIC and ABDOMINAL VISCERA; accompanied by explanatory Maps, for the Use of Students. By the same Author. 5s.

2. ANATOMICAL PLATES of the BONES and MUSCLES, diminished from Albinus, for the Use of Students in Anatomy, and Artists; accompanied by explanatory Maps. By the same Author. 7s.

"The figures in these two little volumes are very neatly and very accurately executed, and are accompanied by maps, or separate outlines, differently coloured, which render the explanation and reference very easy. The whole forms a very neat, portable, and useful help to the student."—*Physical Journal*, and *Annual Review*.

3. The PHYSICIAN'S VADE-MECUM; containing the Symptoms, Causes, Diagnosis, Prognosis, and Treatment of Diseases; accompanied by a Select Collection of Formulæ, and a Glossary of Terms. By the same Author. Very neatly printed in small 8vo. 6s.

4. The SURGEON'S VADE-MECUM; containing the Symptoms, Causes, Diagnosis, Prognosis, and Treatment of Surgical Diseases: accompanied by the modern and approved Methods of operating; a select Formula of Prescriptions, and a Glossary of Terms. By the same Author. In a neat and closely printed Pocket Volume, small 8vo. Price 6s. in boards.

5. The MODERN PRACTICE of PHYSIC: Exhibiting the Characters, Causes, Symptoms, Prognostic, morbid Appearances, and improved Method of treating Diseases. By ROBERT THOMAS, M. D. *Third* Edition, considerably enlarged, in one neat and very closely printed Volume. 8vo. 15s.

This work has been again carefully revised; and a large portion of new and important matter has been added.

"This is a judicious compilation of facts, from the best writers, which may be perused with great advantage by students, because the different subjects are treated with brevity and perspicuity. The Author has chiefly followed Dr. Cullen, both in the classification of diseases, and in his text; but it is necessary to add, that Dr. Thomas does not prove a servile copyist. He has abridged with judgment, has added modern opinions and discoveries, has frequently introduced the result of his own experience, and his performance thus becomes a useful compendium of the present state of Medical Practice. —*Monthly Review.*

6. OBSERVATIONS on the UTILITY and ADMINISTRATION of PURGATIVE MEDICINES, in several Diseases. By JAMES HAMILTON, M. D. Fellow of the Roy College of Physicians, and of the Royal Society of Edinburgh and Senior Physician to the Royal Infirmary of that City *Third* Edition, corrected and enlarged. 8vo. 9s.

7. A PRACTICAL SYNOPSIS of the MATERIA ALIMENTARIA, and MATERIA MEDICA. By RICHARD PEARSON, M. D. Member of the Royal College of Physicians, and formerly Physician to the General Hospital, near Birmingham. A *new* Edition, comprising the latest Improvements in the London, Edinburgh, and Dublin Pharmacopœias; complete in one Volume, 8vo. 12s.

"This very useful and scientific work, which at first was published anonymously, was noticed by us in various stages of its progress with approbation. It is now avowed by a physician of eminence, and appears in an enlarged and improved form, and we can recommend this work of Dr. Pearson as a synopsis of the most useful and masterly kind."—*British Critic.*

8. An ESSAY on the Nature of FEVER; being an Attempt to ascertain the Principles of its Treatment. By A. PHILIPS WILSON, M. D. F. R. S. Ed. Fellow of the Royal College of Physicians of Edinburgh, &c. 8vo. 5s.

9. An ESSAY on DISEASES incidental to EUROPEANS in HOT CLIMATES, with the Method of preventing their fatal consequences. To which are added, Observations on Intermittent Fevers. By the late JAMES LIND, M. D. F. R. S. &c. *Sixth* Edition, corrected, 8vo. 8s. in boards.

10. OBSERVATIONS on the DISEASES which prevail in Long Voyages to HOT COUNTRIES, particularly in those to the East Indies; and on the same Diseases, as they appear in Great Britain. By the late JOHN CLARK, M.D. Fellow of the Royal College of Physicians at Edinburgh; Physician to the Infirmary, and Dispensary, at Newcastle, &c. A new Edition, 8vo. 7s. 6d.

11. An ACCOUNT of the DISEASES of INDIA, as they appeared in the English Fleet, and in the Naval Hospital at Madras, in 1782 and 1783; with Observations on Ulcers, and the Hospital Sores of that Country: comprising also, a Short Treatise on Hospitals. To which is prefixed, A View of the Diseases of an Expedition, and Passage of a Fleet and Armament to India, in 1781. By CHARLES CURTIS, formerly Surgeon of the Medea Frigate. 8vo. 7s.

"The present work is entirely practical. The Author regards the history and symptoms of diseases which he has witnessed, and gives a candid account of his good or ill success in the cure, whilst he indulges in no hypothetical speculations."—*British Critic.*

12. OBSERVATIONS on the DISEASES of SEAMEN. By GILBERT BLANE, M.D. F.R.S.S. Lond. et Ed. &c. Third Edition, 8vo. 7s.

13. A SYSTEM of ARRANGEMENT and DISCIPLINE for the MEDICAL DEPARTMENT of ARMIES. By ROBERT JACKSON, M.D. 8vo. 12s.

14. A TREATISE on the FEVERS of JAMAICA; with some Observations on the Intermitting Fever of America; and an Appendix, containing some Hints on the Means of Preserving the Health of Soldiers in Hot Climates. By ROBERT JACKSON, M.D. 6s. 6d.

15. A DICTIONARY of PRACTICAL SURGERY: collected from the best and most original Sources of Information, and illustrated by critical Remarks. Including Observations on the most important Remedies, Applications, Instruments, &c.; a copious Pharmacopœia Chirurgica, and the Etymology and Meaning of the principal Terms. The whole forming a complete Compendium of Modern Surgical Knowledge. For the Use of Students, private Practitioners, and Naval and Military Surgeons. By SAMUEL COOPER, Member of the Royal College of Surgeons in London. In one neat and very closely printed volume, 8vo. 15s. in boards.

16. LETTERS concerning the DISEASES of the THRA. By CHARLES BELL, 8vo. with Plates. *Press.*

17. PRACTICAL OBSERVATIONS on URI GRAVEL and STONE; on the Diseases of the Blad Prostate Gland; and on Strictures of the Urethr HENRY JOHNSTON, Fellow of the Royal College of S of Edinburgh. 8vo. 5s.

18. PRACTICAL OBSERVATIONS on the RAL HISTORY and CURE of the VENERE EASE. By JOHN HOWARD, Member of the College geons, London. A *new* Edition, considerably impro two Volumes, 8vo. with Plates. 18s.

19. JOHN GOTLIEB WALTER'S PLATES THORACIC and ABDOMINAL NERVES, reduce the Original, as published by Order of the Royal Acad Sciences at Berlin: accompanied by coloured Expla and a Description of the Par Vagum, Great Sympathe Phrenic Nerves. 4to. 18s.

"Professor Walter's incomparable plates are we by anatomists, to be one of the most accurate, most and altogether most perfect specimens of Neuro published; they are executed in the most masterl engraving. Being not easily procurable, Dr. Ho done great service to Anatomy, in republishing t reduced form, accompanied with the original explana which he has added, a short account of the par vagu great sympathetic and phrenic nerves. Dr. H. has also ed the very useful plan of some of his former anatomi lections, of accompanying the finished plate with a v coloured outline skeleton, to which all letters o are transferred; a plan which preserves the unity ness of the engraving, and is of the most material to the reader. The plates of this collection are exe remarkably distinct and elegant manner, and do gre to the artist."—*Annual Review.*

20. ESSAYS on the MORBID ANATOMY of t MAN EYE. By JAMES WARDROP, Fellow of t College of Surgeons, of the Royal Medical and C Societies, and one of the Surgeons of the Public Dispe Edinburgh. Beautifully printed in royal 8vo. illustra several Plates, accurately coloured. Price 21s. boards.

Printed by Harding and Wright, St. John's-square, Lo